This is a digital copy of a book that was preserved for generations on library shelves before it was carefully scanned by Google as part of a project to make the world's books discoverable online.

It has survived long enough for the copyright to expire and the book to enter the public domain. A public domain book is one that was never subject to copyright or whose legal copyright term has expired. Whether a book is in the public domain may vary country to country. Public domain books are our gateways to the past, representing a wealth of history, culture and knowledge that's often difficult to discover.

Marks, notations and other marginalia present in the original volume will appear in this file - a reminder of this book's long journey from the publisher to a library and finally to you.

Usage guidelines

Google is proud to partner with libraries to digitize public domain materials and make them widely accessible. Public domain books belong to the public and we are merely their custodians. Nevertheless, this work is expensive, so in order to keep providing this resource, we have taken steps to prevent abuse by commercial parties, including placing technical restrictions on automated querying.

We also ask that you:

+ *Make non-commercial use of the files* We designed Google Book Search for use by individuals, and we request that you use these files for personal, non-commercial purposes.
+ *Refrain from automated querying* Do not send automated queries of any sort to Google's system: If you are conducting research on machine translation, optical character recognition or other areas where access to a large amount of text is helpful, please contact us. We encourage the use of public domain materials for these purposes and may be able to help.
+ *Maintain attribution* The Google "watermark" you see on each file is essential for informing people about this project and helping them find additional materials through Google Book Search. Please do not remove it.
+ *Keep it legal* Whatever your use, remember that you are responsible for ensuring that what you are doing is legal. Do not assume that just because we believe a book is in the public domain for users in the United States, that the work is also in the public domain for users in other countries. Whether a book is still in copyright varies from country to country, and we can't offer guidance on whether any specific use of any specific book is allowed. Please do not assume that a book's appearance in Google Book Search means it can be used in any manner anywhere in the world. Copyright infringement liability can be quite severe.

About Google Book Search

Google's mission is to organize the world's information and to make it universally accessible and useful. Google Book Search helps readers discover the world's books while helping authors and publishers reach new audiences. You can search through the full text of this book on the web at `http://books.google.com/`

BOSTON
MEDICAL LIBRARY
8 THE FENWAY

TRANSACTIONS

OF THE

PATHOLOGICAL SOCIETY OF LONDON.

VOLUME THE THIRTY-FIRST.

COMPRISING THE REPORT OF THE PROCEEDINGS FOR THE SESSION 1879-80.

LONDON:
PRINTED FOR THE SOCIETY BY J. E. ADLARD, BARTHOLOMEW CLOSE.
1880.

30004

THE present publication, being the Thirty-first Volume of Transactions, constitutes the Thirty-fourth published Annual Report of the Pathological Society's Proceedings.

The COUNCIL think it right to repeat that the exhibitors are alone responsible for the descriptions given of the Specimens exhibited by them, the only change made in the Reports furnished by the authors being such verbal alterations as were absolutely necessary.

53, BERNERS STREET, OXFORD STREET.
October, 1880.

TABLE OF CONTENTS.

OF VOLUME XXXI.

List of Presidents of the Society iv
List of Officers and Members for 1880 . . v—xxxii
Annual Report of Council for 1879 xxxiii
List of Specimens Exhibited during the Session 1879-80 xxxvii
List of Specimens Reported on by the Committee on Morbid Growths lii
List of Plates liii
List of Woodcuts lv
Diseases, etc., of the Nervous System . . . 1
Diseases, etc., of the Organs of Respiration . . 30
Diseases, etc., of the Organs of Circulation . . 58
Diseases, etc., of the Organs of Digestion . . 101
Diseases, etc., of the Genito-Urinary Organs . 148
Diseases, etc., of the Osseous System . . . 193
Diseases, etc., of the Organs of Special Sense . 252
Morbid Growths 256
Diseases, etc., of the Skin 315
Diseases, etc., of the Supra-renal Capsules . . 350
Miscellaneous Specimens 353
Specimens from the Lower Animals 385
Appendix 389
Index 391

Presidents of the Society.

ELECTED

1846 CHARLES J. B. WILLIAMS, M.D., F.R.S.
1848 CHARLES ASTON KEY.
1850 PETER MERE LATHAM, M.D.
1852 CÆSAR H. HAWKINS, F.R.S.
1853 BENJAMIN GUY BABINGTON, M.D., F.R.S.
1855 JAMES MONCRIEFF ARNOTT, F.R.S.
1857 SIR THOMAS WATSON, BART., M.D., F.R.S.
1859 SIR WILLIAM FERGUSSON, BART., F.R.S.
1861 JAMES COPLAND, M.D., F.R.S.
1863 PRESCOTT G. HEWETT, F.R.S.
1865 THOMAS BEVILL PEACOCK, M.D.
1867 JOHN SIMON, D.C.L., F.R.S.
1869 RICHARD QUAIN, M.D., F.R.S.
1871 JOHN HILTON, F.R.S.
1873 SIR WILLIAM JENNER, BART., M.D., K.C.B., D.C.L., F.R.S.
1875 GEORGE D. POLLOCK.
1877 CHARLES MURCHISON, M.D., LL.D., F.R.S.
1879 JONATHAN HUTCHINSON.

OFFICERS AND COUNCIL

OF THE

Pathological Society of London,

ELECTED AT

THE GENERAL MEETING, JANUARY 6TH, 1880.

President.

JONATHAN HUTCHINSON.

Vice-Presidents.

GEORGE BUCHANAN, M.D.
GEORGE HARLEY, M.D., F.R.S.
JAMES EDWARD POLLOCK, M.D.
HERMANN WEBER, M.D.
CHRISTOPHER HEATH.
THOMAS WILLIAM NUNN.
S. JAMES A. SALTER, F.R.S.
SEPTIMUS WILLIAM SIBLEY.

Treasurer.

GEORGE JOHNSON, M.D., F.R.S.

Council.

THOMAS BARLOW, M.D.
EVAN BUCHANAN BAXTER, M.D.
SIDNEY COUPLAND, M.D.
SIR JOSEPH FAYRER, K.C.S.I., M.D.
WILLIAM SMITH GREENFIELD, M.D.
WILLIAM MILLER ORD, M.D.
FREDERICK TAYLOR, M.D.
THOMAS TILLYER WHIPHAM, M.D.
JOHN WILLIAMS, M.D.
J. N. C. DAVIES-COLLEY.
RICKMAN JOHN GODLEE.
JOHN WARRINGTON HAWARD.
HENRY GREENWAY HOWSE.
WILLIAM BEDFORD KESTEVEN, M.D.
JOSEPH LISTER, F.R.S.
JEREMIAH McCARTHY.
WILLIAM MAC CORMAC
WILLIAM JOHNSON SMITH.
WILLIAM W. WAGSTAFFE.

Honorary Secretaries.

JOSEPH FRANK PAYNE, M.D. | W. MORRANT BAKER.

Trustees.

THOS. BEVILL PEACOCK, M.D. | RICHARD QUAIN, M.D., F.R.S.
GEORGE D. POLLOCK.

*** *Members are requested to indicate to the Secretaries corrections when necessary.*

LIST OF MEMBERS OF THE SOCIETY.

Honorary Members.

ARNOTT, JAMES MONCRIEFF, F.R.S., Chapel House, Lady Bank, Fifeshire; and 36, Sussex-gardens, Hyde-park, W.

BILLROTH, THEODOR, M.D., Professor of Surgery in the University of Vienna.

BRUECKE, ERNST, M.D., Professor of Physiology in the University of Vienna.

CHARCOT, J. M., M.D., Physician to the "Hôpital de la Salpêtrière," and Professor at the Faculty of Medicine of Paris.

CHAUVEAU, A., M.D., Professor of Physiology at the Medical School of Lyons.

COHNHEIM, JULIUS, M.D., Professor of General Pathology and Pathological Anatomy in the University of Breslau.

GROSS, SAMUEL D., M.D., D.C.L. Oxon., LL.D., Professor of Surgery in the Jefferson Medical College of Philadelphia.

HELMHOLTZ, H., M.D., Professor of Physiology in the University of Heidelberg.

HENLE, J., M.D., Professor of Anatomy and Physiolcgy in the University of Göttingen.

LUDWIG, C., M.D., Professor of Physiology in the University of Leipzig.

PIROGOFF, NIKOLAUS, M.D., Professor of Surgery to the Medico-Chirurgical Academy of St. Petersburg.

RINDFLEISCH, EDOUARD, M.D., Professor of Pathological Anatomy in the University of Bonn.

ROBIN, CHARLES, M.D., Professor of Histology at the Faculty of Medicine of Paris.

SCHWANN, THEODOR, Professor of Physiology at the University of Liège.

THIERSCH, CARL, M.D., Professor of Surgery in the University of Leipzig.

VIRCHOW, RUDOLF, M.D., Professor of Pathological Anatomy in the University of Berlin.

VOGEL, JULIUS, M.D., Professor of Cutaneous Diseases in the University of Halle.

EXPLANATION OF ABBREVIATIONS.

O.M.—Original Member.	V.-P.—Vice-President.
Pres.—President.	S.—Secretary.
T.—Treasurer.	C.—Member of Council.

Those marked thus (†) have paid Composition Fee for Annual Subscription.
Those marked thus (‡) have paid Composition Fee for Transactions.

GENERAL LIST OF MEMBERS.

Elected

1879 ABERCROMBIE, JOHN, M.D., Hospital for Sick Children, 49, Great Ormond-street.

1858 ACLAND, HENRY WENTWORTH, M.D., F.R.S., Regius Professor of Medicine, University of Oxford, Physician to the Radcliffe Infirmary, Oxford.

Elected

‡1866 ADAMS, ARTHUR BAYLEY.

1869 ADAMS, JAMES EDWARD, Surgeon to the London Hospital, 17, Finsbury-circus, E.C.

O.M. ADAMS, WILLIAM, Consulting Surgeon to the National Orthopædic Hospital, 5, Henrietta-street, Cavendish-square, W. (C. 1851-4. V.-P. 1867-9.)

1859 ADAMS, WILLIAM, Tower Lodge, Regent's-park-road, Gloucester-gate, N.W. (C. 1877-8.)

1848 AIKIN, CHARLES A., 7, Clifton-place, Sussex-square, Hyde-park, W. (C, 1864-6.)

1872 AIKIN, CHARLES EDMUND, 7, Clifton-place, Sussex-square, Hyde-park, W.

1871 AIR, A. CUMMINGS, 88, Kennington-park-road, S.E.

1880 AITKEN, WILLIAM, M.D., F.R.S., Professor of Pathology, Army Medical School, Netley, Southampton, Park Villa, Weston-grove-road, Woolston, Southampton.

1869 ALLBUTT, THOMAS CLIFFORD, M.D., F.R.S., Physician to the Leeds General Infirmary, 35, Park-square, Leeds.

1877 ALTHAUS, JULIUS, M.D., Senior Physician to the Hospital for Epilepsy and Paralysis, Regent's Park, 36, Bryanston-street, Portman-square.

1868 ANDERSON, J. FORD, M.D., 28, Buckland-crescent, Belsize-park, N.W.

1871 ANDERSON, WILLIAM, Assistant Surgeon to St. Thomas's Hospital, 93, St. George's-square, S.W.

1859 ANDREW, EDWYN, M.D., Hardwick House, St. John's-hill, Shrewsbury.

1863 ANDREW, JAMES, M.D., Physician to St. Bartholomew's Hospital, 22, Harley-street, W. (C. 1868-70.)

1866 ARNOTT, REV. HENRY, Braeside, Beckenham. (C. 1872, 1875-6. S. 1873, 1874.)

1863 BAGSHAWE, FREDERICK, M.A., M.D., 16, Warrior-square, Hastings.

1864 BAKER, WILLIAM MORRANT (HON. SECRETARY), Assistant Surgeon to, and Lecturer on Physiology at, St. Bartholomew's Hospital, 26, Wimpole-street, Cavendish-square, W. (C. 1873-6. S. 1878-80.)

‡1856 BALDING, DANIEL BARLEY, Royston, Herts.

1880 BALL, BENJAMIN, Professeur à la Faculté de Médecine de Paris, Médecin en Chef de la Clinique des Maladies Mentales, Faubourg St. Honoré, 3, Paris.

1851 BARCLAY, A. WHYTE, M.D., Physician to St. George's Hospital, 23A, Bruton-street, Berkeley-square, W. (C. 1858-61.)

1875 BARKER, ARTHUR E. J., Assistant Surgeon and Assistant Teacher of Clinical Surgery, University College Hospital, 87, Harley-street, Cavendish-square, W.

1874 BARLOW, THOMAS, M.D., B.S. (C.), Assistant Physician to University College Hospital and to the Children's Hospital, Great Ormond-street, 10, Montague-street, Russell-square, W.C. (C. 1879-80.)

1871 BARNES, ROBERT, M.D., Obstetric Physician to St. George's Hospital, 15, Harley-street, Cavendish-square, W.

Elected

1862 BARRATT, JOSEPH GILLMAN, M.D., Accoucheur to the St. George's and St. James's Dispensary, 8, Cleveland-gardens, Bayswater, W.

1877 BARROW, A. BOYCE, Pathological Registrar, King's College Hospital, 17, Welbeck-street, Cavendish-square, W.

1879 BARTLETT, HENRY, M.D., 171, Loughboro'-road, Stockwell, S.W.

1853 BARWELL, RICHARD, Surgeon to, and Lecturer on Surgery at, the Charing Cross Hospital, 32, George-street, Hanover-square, W. (C. 1862-4.)

1861 BASTIAN, H. CHARLTON, M.A., M.D., F.R.S., Professor of Pathological Anatomy in University College, and Physician to University College Hospital, 20, Queen Anne-street, W. (C. 1869-71.)

1877 BATEMAN, ARTHUR W., B.A., Tenterfield, New South Wales.

†1876 BATTESON, JOHN, Medical Officer of the Royal Humane Society, 1, Coborn-place, Bow-road, E.

1870 BÄUMLER, CHRISTIAN G. H., M.D., Professor of Materia Medica in the University of Erlangen.

1871 BAXTER, EVAN BUCHANAN, M.D. (C.), Professor of Materia Medica, King's College, London, and Assistant Physician to King's College Hospital, 28, Weymouth-street, Portland-place, W. (C. 1880.)

1874 BEACH, FLETCHER, M.B., Metropolitan District Asylum, Darenth, near Dartford, Kent.

1879 BEALE, EDWIN CLIFFORD, M.B., 16, Langham-street, Portland-place, W.

1852 BEALE, LIONEL S., M.B., F.R.S., Professor of Medicine at King's College, Physician to King's College Hospital, 61, Grosvenor-street, W. (C. 1858-9. V.-P. 1874-5.)

1856 BEALEY, ADAM, M.D., M.A., Oak-lea, Harrogate.

†1878 BEANEY, JAMES GEORGE, Senior Surgeon to the Melbourne Hospital, Melbourne, Victoria.

1870 BECK, MARCUS, M.S., Assistant Surgeon to University College Hospital, 30, Wimpole-street, Cavendish-square, W. (C. 1875-7.)

1865 BEEBY, WALTER, M.D., Bromley, Kent.

1875 BELL, H. ROYES, Surgeon to King's College Hospital, 44, Harley-street, Cavendish-square, W.

1865 BELLAMY, EDWARD, Surgeon to the Charing Cross Hospital, 17, Wimpole-street, Cavendish-square, W. (C. 1876-8.)

1847 BENNET, JAMES HENRY, M.D., Weybridge, Surrey.

O.M. BENNETT, JAMES RISDON, M.D., F.R.S., Consulting Physician to St. Thomas's Hospital, and to the City of London Hospital for Diseases of the Chest, 22, Cavendish-square, W. (C. 1846-8. V.-P. 1856-9.)

1877 BENNETT, WILLIAM HENRY, Assistant Surgeon to St. George's Hospital, Surgeon to the Belgrave Hospital for Children, 5, Savile-row, Burlington-gardens.

1878 BERNARD, FRANCIS W., M.D., Medical Superintendent, Stockwell Small-pox Hospital, Stockwell, S.W.

Elected

‡1856 BICKERSTETH, EDWARD R., Surgeon to the Liverpool Royal Infirmary, 2, Rodney-street, Liverpool.

1878 BINDON, WILLIAM JOHN VERBEKER, M.D., 2, Elm-villas, Kilburn, N.W.

1850 BIRKETT, EDMUND LLOYD, M.D., Consulting Physician to the City of London Hospital for Diseases of the Chest, 48, Russell-square, W.C. (C. 1856-7.)

O.M. BIRKETT, JOHN, Consulting Surgeon to Guy's Hospital, 59, Green-street, Grosvenor-square, W. (C. 1851. V.-P. 1860-2.)

1865 BISSHOPP, JAMES, Bedford-place, Tunbridge Wells.

1853 BLACK, CORNELIUS, M.D., Physician to the Chesterfield Dispensary, St. Mary's-gate, Chesterfield.

1877 BLACK, JAMES, 41, Aytoun-road, Stockwell-road, Brixton.

1850 BLAGDEN, ROBERT, Stroud, Gloucestershire.

1863 BLANCHET, JEAN B., M.D., M.S., Montreal, Quebec, Canada.

1876 BLASSON, WILLIAM, Edgeware, Middlesex.

1879 BOILEAU, J. P. H., M.D., Surgeon-Major, Army Medical Department. Assistant Professor of Pathology, Netley School of Medicine, Netley.

1876 BOND, THOMAS, M.B., Assistant Surgeon and Lecturer on Forensic Medicine to Westminster Hospital, 17, Delahay-street, Westminster, S.W.

1869 BOURNE, WALTER, M.D.

1880 BOWEN, ALFRED LONGMORE, 5, Lewisham-road, Greenwich, S.E.

1861 BOWER, RICHARD NORRIS, 14, Doughty-street, Mecklenburg-square, W.C

1851 BOWMAN, WILLIAM, F.R.S., Surgeon to the Royal Ophthalmic Hospital, 5, Clifford-street, Bond-street, W. (C. 1855-6.)

1879 BRAILEY, WM. ARTHUR, M.D., Lecturer on Comparative Anatomy at St. George's and Guy's Hospitals, 38, King's-road, Brownswood-park, Green-lanes, N.

1880 BRAMWELL, BYROM, M.D., 4, Drumsheugh-gardens West, Edinburgh.

1877 BRIDGES, ROBERT, M.B., M.A. Oxford, Casualty Physician to St. Bartholomew's Hospital, 52, Bedford-square, W.C.

‡1867 BRIDGEWATER, THOMAS, M.B. Lond., Harrow-on-the-hill, Middlesex.

1873 BRIGGS, JACOB MYERS, M.D., Coeymans, New York, U.S.

1868 BRIGHT, G. C., M.B., Cannes, France.

1857 BRISCOE, JOHN, 12, Broad-street, Oxford.

†1851 BRISTOWE, JOHN S., M.D., Physician to, and Lecturer on the Theory and Practice of Medicine at, St. Thomas's Hospital, 11, Old Burlington-street, W. (C. 1854-8. S. 1861-4. C. 1865-7. V.-P. 1868-76.)

1860 BROADBENT, WILLIAM HENRY, M.D. Lond., Physician to St. Mary's Hospital, and Physician to the London Fever Hospital, 34, Seymour-street, Portman-square, W. (C. 1871-3.)

1877 BROCKMAN, E. F., Madras Medical Service [18, Addison-gardens North, Kensington, W.].

1852 BRODHURST, BERNARD E., Surgeon to the Royal Orthopædic Hospital, 20, Grosvenor-street, W. (C. 1862-4.)

1863 BRODIE, GEORGE BERNARD, M.D., Consulting Physician-Accoucheur to Queen Charlotte's Hospital, 3, Chesterfield-street, Mayfair, W.

Elected

1865 BROWN, AUGUSTUS, M.D., 29, Belitha-villas, Barnsbury-park, N.

1871 BROWN, FREDERICK GORDON, 16, Finsbury-circus, E.C.

1875 BROWNE, GEORGE BUCKSTON, 80, Wimpole-street, Cavendish-square, W.

1866 BROWNE, LENNOX, Surgeon to the Central Throat and Ear Hospital, and to the Royal Society of Musicians, 36, Weymouth-street, Portland-place, W.

O.M. BROWNE, JOSEPH HULLETT, M.D., late Physician to the St. Pancras Royal General Dispensary, Ridgeway House, near Southampton. (C. 1859-60.)

1877 BRUCE, J. MITCHELL, M.D., Assistant Physician to Charing Cross Hospital and to the Hospital for Consumption, Brompton, 60, Queen Anne-street, Cavendish-square, W.

1855 BRYANT, THOMAS, Surgeon to Guy's Hospital, 53, Upper Brook-street, Grosvenor-square, W. (C. 1863-6. V.-P. 1877-79.)

1854 BUCHANAN, GEORGE, M.D. (V.-P.), Medical Officer of the Local Government Board, 24, Nottingham-place, Marylebone-road, W. (C. 1864-6. V.-P. 1880.)

1862 BUCHANAN, ALBERT, M.B. Lond., 382, Camden-road, N.

1858 BUDD, GEORGE, M.D., F.R.S., Ashleigh, Barnstaple. (C. 1862-4.)

1878 BURNETT, ROBERT WILLIAM, M.D., 57, Queen Anne-street, Cavendish-square, W.

1853 BURTON, JOHN M., Lee-park Lodge, Lee, Kent, S.E.

1872 BUTLIN, HENRY TRENTHAM, Assistant Surgeon to St. Bartholomew's Hospital, Assistant Surgeon to the West London Hospital, 47, Queen Anne-street, W. (C. 1876-8.)

1866 BUTT, WILLIAM FREDERICK, 25, Park-street, Park-lane, W.

1856 BUZZARD, THOMAS, M.D., Physician to the National Hospital for the Epileptic and Paralysed, 56, Grosvenor-street, W. (C. 1869-70.)

†O.M. CAMPS, WILLIAM, M.D. (C. 1856-9.)

‡1855 CARPENTER, ALFRED, M.D., High-street, Croydon.

1879 CARRINGTON, ROBERT E., M.B., 13, Loughborough-road, Brixton, S.W.

1871 CARTER, CHARLES HENRY, M.D., B.S. Lond., Physician to the Hospital for Women, 45, Great Cumberland-place, Hyde-park, W.

1855 CARTER, H. VANDYKE, M.D., Professor of Anatomy and Physiology, Grant Medical College, Bombay. [22, Clarendon-road, Victoria-road, Kensington, W.]

1876 CARTER, ROBERT BRUDENELL, Ophthalmic Surgeon to, and Lecturer on Ophthalmic Surgery at, St. George's Hospital, 69, Wimpole-street, Cavendish-square, W.

1879 CASSIDY, JOSEPH LAMONT, M.D., 82, Guilford-street, Russell-square, W.C.

1877 CASSON, JOHN HORNSEY.

†1868 CAVAFY, JOHN, M.D., Senior Assistant Physician to St. George's Hospital, 2, Upper Berkeley-street, Portman-square, W.

1864 CAY, CHARLES VIDLER, Smedleys, Matlock Bank, Derby.

Elected

1863 CAYLEY, WILLIAM, M.D., Physician to, and Lecturer on the Principles and Practice of Medicine at, the Middlesex Hospital, 58, Welbeck-street, Cavendish-square, W. (C. 1870-1, 1875-8. S. 1872-4.)

1869 CHAFFERS, EDWARD, Keighley, Yorkshire.

1849 CHALK, WILLIAM OLIVER, 3, Nottingham-terrace, Regent's-park, N.W. (C. 1856-7.)

1876 CHARLES, T. CRANSTOUN, M.D., M.C., Lecturer on Practical Physiology at St. Thomas's Hospital, 61, West Cornwall-road, South Kensington, S.W.

1870 CHEADLE, WALTER BUTLER, M.D., Assistant Physician to St. Mary's Hospital, and to the Hospital for Sick Children, Great Ormond-street, 2, Hyde-park-place, Cumberland-gate, W.

O.M. CHEVERS, NORMAN, M.D., 32, Tavistock-road, Notting-hill, W. (C. 1848.)

1879 CHEYNE, WILLIAM WATSON, M.B., C.M., Assistant Surgeon to King's College Hospital, 6, Old Cavendish-street, W.

1858 CHILD, GILBERT W.

1873 CHISHOLM, EDWIN, M.D., Abergeldie, Ashfield, near Sydney, New South Wales.

1855 CHOLMELEY, WILLIAM, M.D., Physician to the Great Northern Hospital, and to the Margaret-street Infirmary for Consumption, 63, Grosvenor-street, W. (C. 1871-3.)

1871 CHRISTIE, THOMAS BEATH, M.D., Superintendent of the Royal India Asylum, Ealing, Middlesex.

1865 CHURCH, WILLIAM SELBY, M.D., Physician to St. Bartholomew's Hospital, 130, Harley-street, Cavendish-square, W. (C. 1871-3.)

†1868 CHURCHILL, FREDERICK, M.B., Assistant Surgeon to the Victoria Hospital for Children, 6, Sumner-place, S.W.

1861 CLAPTON, EDWARD, M.D., 10A, St. Thomas's-street, Southwark, S.E.

1854 CLARK, ANDREW, M.D., Physician to the London Hospital, 16, Cavendish-square, W. (C. 1862-5.)

1872 CLARK, ANDREW, Assistant Surgeon to the Middlesex Hospital, 19, Cavendish-place, W.

1867 CLARKE, WILLIAM FAIRLIE, M.A., M.D., Southborough, Tunbridge Wells. (C. 1873-5.)

1875 CLARKSON, JOHN, Surgeon in the India Department, Bombay Presidency, India.

1875 CLUTTON, HENRY HUGH, M.A., Assistant Surgeon, St. Thomas's Hospital, 16, Palace-road, Albert-embankment, S.E.

‡1865 COATES, CHARLES, M.D., Physician to the Bath General and Royal United Hospitals, 10, Circus, Bath.

1856 COCKLE, JOHN, M.D., M.A., Physician to the Royal Free Hospital, 13, Spring-gardens, Charing-cross, S.W.

O.M. COHEN, DANIEL WHITAKER, M.D., South-bank, Northdown-lane, Bideford Devon.

COLLEY, see DAVIES-COLLEY.

Elected

1879 COLLINS, WM. MAUNSELL, M.D., Surgeon, Scots Guards, 78, Grosvenor-street, W.

1878 COLLYNS, R. T. POOLE, Atkinson Morley Hospital, Copse-hill, Wimbledon.

1858 COOKE, ROBERT THOMAS, Surgeon to the Scarborough Dispensary, 15, St. Nicholas-cliff, Scarborough, Yorkshire.

1871 COOKE, THOMAS, Assistant Surgeon to the Westminster Hospital, 16, Woburn-place, W.C.

1866 COOMBS, ROWLAND HILL, Mill-street, Bedford.

1879 COOPER, ARTHUR, 2, Henrietta-street, Cavendish-square, W.

§1851 COOPER, WILLIAM WHITE, Consulting Ophthalmic Surgeon to St. Mary's Hospital, 19, Berkeley-square, W. (C. 1860-2.)

1853 CORNISH, WILLIAM ROBERT, Surgeon-Major, Madras Army, Sanitary Commissioner for Madras.

1875 CORY, ROBERT, M.D., Assistant Obstetric Physician to St. Thomas's Hospital, 14, Palace-road, Albert-embankment, S.E.

1876 COTTLE, ERNEST WYNDHAM, M.A., Assistant Surgeon, Hospital for Diseases of the Skin, Blackfriars, 3, Savile-row.

1859 COULSON, WALTER J., Surgeon to the Lock Hospital, 17, Harley-street, Cavendish-square, W.

†1861 COUPER, JOHN, Surgeon to the London Hospital, 80, Grosvenor-street, Grosvenor-square, W. (C. 1870-2.)

1873 COUPLAND, SIDNEY, M.D. (C.), Physician to, and Lecturer on Pathological Anatomy at, the Middlesex Hospital, 14, Weymouth-street, Portland-place. (C. 1878-80.)

1879 COWBURN, GEORGE HERBERT, late House Physician, St. George's Hospital, 1, St. George's-place, Hyde-park, S.W.

1873 CRIPPS, WILLIAM HARRISON, Surgical Registrar to St. Bartholomew's Hospital, 6, Stratford-place, Oxford-street, W.

O.M. CRISP, EDWARDS, M.D., 16, Beaufort-street, Chelsea, S.W. (C. 1846-7-V.-P. 1870-2.)

1848 CRITCHETT, GEORGE, Surgeon to the Royal London Ophthalmic Hospital, Moorfields, and Ophthalmic Surgeon to the Middlesex Hospital, 21, Harley-street, W. (S. 1849. C. 1851, 1858-9. V.-P. 1866-7.)

1877 CROCKER, HENRY RADCLIFFE, M.D., Physician to the Skin Department, University College Hospital; Assistant Physician and Pathologist to the East London Hospital for Children, 78, Welbeck-street, Cavendish-square, W.

1856 CROFT, JOHN, Surgeon to St. Thomas's Hospital, 61, Brook-street, Grosvenor-square, W. (C. 1870-2.)

1879 CROOKE, GEORGE FREDERICK, M.B., Gainsborough, Lincolnshire.

1861 CROSBY, THOMAS BOOR, M.D., 21, Gordon-square, W.C.

1875 CROSS, FRANCIS RICHARDSON, 5, The Mall, Clifton, Bristol.

1864 CRUCKNELL, HENRY H., M.B., 58, Welbeck-street, W. (C. 1875-76.)

1871 CUMBERBATCH, ELKIN, Demonstrator of Anatomy at St. Bartholomew's Hospital, 17, Queen Anne-street, W.

Elected

1858 CUMBERBATCH, LAURENCE T., M.D., 25, Cadogan-place, Sloane-street, S.W.

1873 CURNOW, JOHN, M.D., Professor of Anatomy at King's College, and Assistant Physician to King's College Hospital, 3, George-street, Hanover-square, S.W.

‡1865 CURRAN, WILLIAM, M.D., Army Medical Staff. [Agent: Mr. H. K. Lewis, 136, Gower-street, W.C.]

1873 DAVIDSON, ALEXANDER, M.D., Physician to the Liverpool Royal Infirmary; Lecturer on Pathology at the Liverpool Medical School, 49, Rodney-street, Liverpool.

1869 DAVIES-COLLEY, J. NEVILLE C., M.B. (C.), Surgeon to Guy's Hospital, 36, Harley-street, Cavendish-square. (C. 1880.)

O.M. DAVIES, HERBERT, M.D., Consulting Physician to the London Hospital, and to the Infirmary for Asthma, 23, Finsbury-square, E.C. (C. 1849-50. V.-P. 1871.)

‡1859 DAVIS, FRANCIS WILLIAM, R.N., Surgeon to the Naval Medical Establishment, Lisbon. [Agents: Messrs. Hallett and Co., 7, St. Martin's-place, Trafalgar-square, W.C.]

1879 DAVY, HENRY, M.B., 34, Southernhay, Exeter.

1866 DAY, WILLIAM HENRY, M.D., Physician to the Samaritan Free Hospital for Women and Children, 10, Manchester-square, W.

1872 DECASTRO, JAMES C., M.B., Pau, France.

1871 DE LIEFDE TEMPLE, JOHN, M.D. [per Mr. James Nimmo, 7, Red Lion-court, Watling-street, E.C.].

1863 DEVEREUX, DANIEL, Tewkesbury, Gloucestershire.

1856 DICK, H., M.D.

1871 DICKINSON, EDWARD HARRIMAN, M.A. Oxon., M.D., Physician to the Liverpool Northern Hospital, and Lecturer on Comparative Anatomy at the Liverpool School of Medicine, 162, Bedford-street, Liverpool.

1858 DICKINSON, WILLIAM HOWSHIP, M.D., Physician to the Hospital for Sick Children, Physician and Lecturer on Medicine to St. George's Hospital, 9, Chesterfield-street, Mayfair, W. (C. 1866-8. S. 1869-71. V.-P. 1872-4.)

1872 DIVER, EBENEZER, M.D., Kenley, Caterham-valley, Surrey.

O.M. DIXON, JAMES, Consulting Surgeon to the Royal Ophthalmic Hospital, Moorfields; Harrowlands, Dorking, Surrey. (C. 1852-6. V.-P. 1860-2.)

1872 DORAN, ALBAN HENRY GRIFFITHS, Surgeon to Out-Patients, Samaritan Hospital, Pathological Assistant to Museum, Royal College of Surgeons, 51, Seymour-street, Portman-square, W.

†1866 DOWN, JOHN LANGDON H., M.D., Physician to the London Hospital, 39, Welbeck-street, Cavendish-square, W. (C. 1872-4.)

1872 DOWSE, THOMAS STRETCH, M.D., 14, Welbeck-street, Cavendish-square.

Elected

1880 DRESCHFELD, JULIUS, M.D., 292, Oxford-road, Manchester.

1879 DREWITT, F. G. DAWTREY, M.B., Hospital for Sick Children, Great Ormond-street, W.C.

1865 DUCKWORTH, DYCE, M.D., Assistant Physician to St. Bartholomew's Hospital, 11, Grafton-street, Bond-street, W. (C. 1877.)

1863 DUDFIELD, THOMAS ORME, M.D., 8, Upper Phillimore-place, Kensington, W.

1847 DUDGEON, ROBERT E., M.D., 53, Montagu-square, W.

1852 DUFF, GEORGE, M.D., High-street, Elgin.

1865 DUFFIN, ALFRED BAYNARD, M.D., Physician to King's College Hospital, 18, Devonshire-street, Portland-place, W. (C. 1872-4.)

1875 DUKA, THEODORE, M.D., Surgeon-Major, H.M.'s Bengal Army; 38, Montagu-square, W.

1868 DUKE, OLIVER THOMAS, M.B., India.

1871 DUKES, CLEMENT, M.D., B.S. Lond., Physician to Rugby School, Sunnyside, Rugby.

1877 DUNBAR, J. J. MACWHIRTER, Assistant House-Physician to St. George's Hospital, 77, Ladbroke-grove, Kensington-park, W.

1877 DUNCAN, ANDREW, M.D., 8, Henrietta-street, Covent-garden, W.C.

1880 DUNCAN, JAS. MATTHEWS, M.D., Obstetric Physician to St. Bartholomew's Hospital, 71, Brook-street, Grosvenor-square, W.

1861 DUNN, ROBERT WILLIAM, 13, Surrey-street, Strand, W.C.

1858 DURHAM, ARTHUR EDWARD, Surgeon to Guy's Hospital, 82, Brook-street, Grosvenor-square, W. (C. 1869-71.)

1879 DURHAM, FREDERIC, M.B., 38, Brook-street, Grosvenor-square, W.

1867 ELLIS, JAMES, M.D., California.

1847 ELLIS, JAMES. [Messrs. Tweedie, 337, Strand.]

1873 ENGELMANN, GEORGE JULIUS, M.D., A.M., 3003, Locust-street, St. Louis, Miss., U.S.

1846 ERICHSEN, JOHN ERIC, F.R.S., Surgeon to University College Hospital, 6, Cavendish-place, Cavendish-square, W. (C. 1849-51. V.-P. 1863-4.)

1853 EVANS, CONWAY, M.D., The Garden House, Clements-inn, W.C. (C. 1867-8.)

1873 EVANS, GEORGE HENRY, M.D.

1875 EVANS, JULIAN, A.M., M.D., Physician to the Victoria Hospital for Sick Children, 123, Finboro'-road, Redcliffe-square, West Brompton, S.W.

1879 EVE, FREDERIC S., Curator of Museum, St. Bartholomew's Hospital, 14, Furnival's Inn, Holborn, W.C.

1876 EWART, JAMES COSSAR, M.B., C.M., School of Medicine, Edinburgh.

1877 EWART, WILLIAM, M.B., Assistant Physician to the Hospital for Consumption, Brompton, 33, Curzon-street, Mayfair, W.

‡1859 EWENS, JOHN, Cotham Brow, Bristol.

Elected

1864 FAGGE, CHARLES HILTON, M.D., Physician to, and Lecturer on Pathology at, Guy's Hospital, 11, St. Thomas's-street, Southwark, S.E. (C. 1870-2.)

1862 FARQUHARSON, ROBERT, M.D., M.P., 23, Brook-street, Grosvenor-square, W. (C. 1876-7.)

1872 FAYRER, Sir JOSEPH, K.C.S.I., M.D. F.R.S. Ed. (C.), Hon. Physician to the Queen, Surgeon-Major, Bengal Army, Examining Medical Officer to the Secretary of State for India in Council, 16, Granville-place, Portman-square, W. (C. 1880.)

1872 FENN, EDWARD L., M.B., The Old Palace, Richmond, Surrey.

1872 FENWICK, JOHN C. J., M.D., Physician to the Durham County Hospital, Chilton Hall, Ferry-hill, and 16, Old Elvet, Durham.

1863 FENWICK, SAMUEL, M.D., Physician, with charge of out-patients to, and Lecturer on Medicine at, the London Hospital, 29, Harley-street, W.

1846 FINCHAM, GEORGE T., M.D., Physician to the Westminster Hospital, 13, Belgrave-road, S.W. (C. 1855.)

1876 FINLAY, DAVID W., M.D., Assistant Physician to the Middlesex Hospital, 21, Montagu-street, Portman-square, W.

1870 FISH, JOHN CROCKETT, M.D., 92, Wimpole-street, W.

1859 FISHER, ALEXANDER, M.D., Assistant Surgeon, R.N., Her Majesty's Ship "Endymion."

1855 FLOWER, WILLIAM H., F.R.S., Conservator of the Museum, Royal College of Surgeons, 39, Lincoln's-inn-fields, W.C. (C. 1862-4.)

1872 FORBES, DANIEL MACKAY, L.R.C.P. Ed., 204, Hoxton-street, N.

†O.M. FORSTER, JOHN COOPER, Surgeon to Guy's Hospital, 29, Upper Grosvenor-street, W. (C. 1857-8. V.-P. 1871-3.)

‡1866 FOSTER, BALTHAZAR WALTER, M.D., Physician to the General Hospital, Birmingham, 16, Temple-row, Birmingham.

1872 FOTHERBY, HENRY J., M.D., Physician to the Metropolitan Free Hospital, 3, Finsbury-square, E.C.

1880 FOWLER, JAMES KINGSTON, B.A., M.B., 35, Clarges-street, Picadilly, W.

1878 FOX, THOMAS COLCOTT, M.B., B.A., 14, Harley-street, Cavendish-square, W.

1862 FOX, WILSON, M.D., Holme Professor of Clinical Medicine in University College, and Physician to University College Hospital, 67, Grosvenor-street, W. (C. 1868-70. V.-P. 1875-77.)

1858 FRANCIS, CHARLES RICHARD, M.B., Bengal Medical Establishment, Indian Army.

O.M. FRERE, J. C.

1864 FRODSHAM, JOHN MILL, M.D., Streatham, S.W.

1880 GABBETT, HENRY SINGER, M.B., 33, Upper Bedford-place, W.C.

‡1858 GAIRDNER, WILLIAM TENNANT, M.D., Professor of Medicine in the University of Glasgow, 225, St. Vincent-street, Glasgow.

Elected

1870 GALTON, EDMUND H., Springfield House, Brixton-hill, S.W.

1870 GALTON, JOHN H., M.D., 1, Woodside, Anerley-road, Upper Norwood, S.E.

1855 GAMGEE, JOSEPH SAMPSON, Surgeon to the Queen's Hospital, Birmingham, 20, Broad-street, Birmingham.

1855 GAMGEE, J.

1877 GARLICK, GEORGE, M.D., 33, Great James-street, Bedford-row, W.C.

1846 GARROD, ALFRED BARING, M.D., F.R.S., Consulting Physician to King's College Hospital, 10, Harley-street, Cavendish-square, W (C. 1851. V.-P. 1863-5.)

1879 GARSTANG, THOMAS WALTER HARROPP, Oakleigh, Dobcross, Manchester.

1872 GARTON, WILLIAM, Hardshaw-street, St. Helen's, Lancashire.

O.M. GAY, JOHN, Senior Surgeon to the Great Northern Hospital, 34, Finsbury-place, E.C. (C. 1852-4. V.-P. 1870-2.)

1880 GIBBES, HENEAGE, M.B., 42, Colville-terrace, Bayswater, W.

1853 GIBBON, SEPTIMUS, M.D., 39, Oxford-terrace, Hyde-park, W.

1878 GIBBONS, R. A., M.D., 88, Cadogan-place, S.W.

1876 GILL, JOHN, M.D., Newton Abbot, Devon.

1873 GODLEE, RICKMAN JOHN, M.B., B.S. (C.), Assistant Surgeon to University College Hospital; Demonstrator of Anatomy in University College; 22, Henrietta-street, Cavendish-square, W. (C. 1877-80.)

1875 GODSON, CLEMENT, M.D., Assistant Physician-Accoucheur to St. Bartholomew's Hospital, 9, Grosvenor-street, W.

1879 GODWIN, CHARLES HENRY YOUNG, Surgeon Major, Army, 23, The Common, Woolwich.

1878 GOLDING-BIRD, CUTHBERT H., M.B., Assistant Surgeon to Guy's Hospital, 13, St. Thomas's-street, S.E.

1871 GOODHART, JAMES FREDERICK, M.D., Assistant Physician to, and Teacher of Clinical Medicine at, Guy's Hospital, 27, Weymouth-street, Portland-place, W. (C. 1876-8.)

1875 GOULD, ALFRED PEARCE, M.S., Assistant Surgeon to, and Lecturer on Anatomy at, the Westminster Hospital, 16, Queen Anne-street, W.

1870 GOWERS, WILLIAM RICHARD, M.D. (C.), Assistant Physician to University College Hospital, 50, Queen Anne-street, W. (C. 1878-9.)

1858 GOWLLAND, PETER Y., Surgeon to St. Mark's Hospital, 34, Finsbury-square, E.C.

1867 GREEN, T. HENRY, M.D. (C.), Physician to Charing Cross Hospital, Assistant Physician to the Hospital for Consumption, Brompton, 74, Wimpole-street, W. (C. 1871-3, 1878-9. S. 1875-6.)

1873 GREENFIELD, WILLIAM SMITH, M.D., B.S. (C.), Assistant Physician to, and Lecturer on Morbid Anatomy at, St. Thomas's Hospital, 15, Palace-road, Albert Embankment, S.E. (C. 1877-80.)

1856 GREENHALGH, ROBERT, M.D., 72, Grosvenor-street, W.

‡1855 GREENHILL, WILLIAM ALEXANDER, M.D., Carlisle-parade, Hastings.

‡1863 GREENHOW, EDWARD HEADLAM, M.D., F.R.S., Consulting Physician to the Middlesex Hospital, 14A, Manchester-square, W. (C. 1867-9. V.-P. 1877-8.)

Elected

1876 Griffiths, Thomas D., M.D., Hearne Lodge, Swansea.

1861 Guéneau de Mussy, Henri, M.D., 15, Rue du Cirque, Paris.

1863 Gull, Sir William Withey, Bart., M.D., D.C.L., F.R.S., Consulting Physician to Guy's Hospital, 74, Brook-street, Grosvenor-square, W.

1880 Gunn, R. Marcus, M.B., C.M., Royal Ophthalmic Hospital, Moorfields.

1876 Gwyther, James, M.B. Lond., St. Mary Church, Torquay.

1849-59 Habershon, Samuel Osborne, M.D., Physician to Guy's Hospital, 70, Brook-street, Grosvenor-square, W. (Re-elected 1874.) (C. 1855-6.)

1851 Hacon, E. Dennis, 269, Mare-street, Hackney, N.E. (C. 1872.)

1879 Hadden, Walter Baugh, M.D.

1877 Hallowes, Frederick Blackwood, Redhill, Surrey.

1848 Hare, Charles John, M.D., late Physician to University College Hospital, 57, Brook-street, Grosvenor-square, W. (C. 1852-4. V.-P. 1874-7.)

†1856 Harley, George, M.D., F.R.S. (V.-P.), 25, Harley-street, Cavendish-square, W. (C. 1862-5. V.-P. 1878-80.)

1872 Harris, Henry, M.D., Trengweath-place, Redruth, Cornwall.

1879 Harris, Vincent Dormer, M.D., Casualty Physician to St. Bartholomew's Hospital, 23, Upper Berkeley-street, Portman-square, W.

†1858 Hart, Ernest, 38, Wimpole-street, Cavendish-square, W. (C. 1867-8.)

1870 Haward, John Warrington (C.), Surgeon to St. George's Hospital, 16, Savile-row, W. (C. 1879-80.)

O.M. Hawkins, Cæsar H., F.R.S., Consulting Surgeon to St. George's Hospital, 26, Grosvenor-street, W. (V.-P. 1846-51. *Pres.* 1852-3.)

1857 Hawksley, Thomas, M.D., Physician to the Margaret-street Dispensary for Consumption, 31, Grosvenor-street, W.

1856 Heath, Christopher (V.-P.), Holme Professor of Clinical Surgery in University College, and Surgeon to University College Hospital, 36, Cavendish-square, W. (C. 1866-7. V.-P. 1879-80.)

1878 Hellier, John B., M.B., Headingley, Leeds.

1879 Henderson, George Courtenay, M.B., University College Hospital.

1869 Hensley, Philip J., M.D., Assistant Physician to St. Bartholomew's Hospital, 4, Henrietta-street, Cavendish-square, W.

‡1868 Heslop, Thomas P., M.D., Physician to the Children's Hospital, Birmingham.

O.M. Hewett, Prescott G., F.R.S., Consulting Surgeon to St. George's Hospital, 1, Chesterfield-street, Mayfair, W. (C. 1846-52. V.-P. 1854-7. *Pres.* 1863-4. V.-P. 1865-8.)

1855 Hewitt, Graily, M.D., Obstetric Physician to University College Hospital, 36, Berkeley-square, W. (C. 1865-7.)

1864 Hickman, William, M.B., Surgeon to the Samaritan Free Hospital, 1, Dorset-square, N.W.

1860 Hill, M. Berkeley, M.B., Surgeon to University College Hospital, and Surgeon for Out-Patients to the Lock Hospital, 55, Wimpole-street, Cavendish-square, W. (C. 1874-5.)

1875 Hitchcock, Harry Knight, M.D., 1, Cliftonville, Bournemouth, Hants.

Elected

1880 HOBSON, JOHN MORRISON, M.D., 3, Addiscombe-villas, Lower Addiscombe-road, Croydon.

1874 HOGGAN, GEORGE, M.B., 7, Trevor-terrace, Rutland-gate, S.W.

1847 HOLMAN, H. MARTIN, M.D., Hurstpierpoint, Sussex.

1854 HOLMES, TIMOTHY, Surgeon-in-Chief to the Metropolitan Police, Surgeon to St. George's Hospital, 18, Great Cumberland-place, Hyde-park, W. (C. 1862-3. S. 1864-7. C. 1868. V.-P. 1869-71.)

1850 HOLT, BARNARD WIGHT, Consulting Surgeon to the Westminster Hospital, 14, Savile-row, W. (C. 1853.)

O.M. HOLTHOUSE, CARSTEN. (C. 1852-4, V.-P. 1874-5.)

1878 HOOD, DONALD WILLIAM CHARLES, M.D., 43, Green-street, Park Lane.

1864 HOOD, WHARTON P., M.D., 65, Upper Berkeley-street, Portman-square, W.

1870 HOPE, WILLIAM, M.D., 56, Curzon-street, Mayfair, W.

1879 HORROCKS, PETER, M.D., Guy's Hospital, 29, Merrick-square, S.E.

1877 HOUGHTON, WALTER B., M.D., Assistant Physician to Charing Cross Hospital, 26, Cavendish-square, W.

1880 HOVELL, T. MARK, Throat and Chest Hospital, Golden-square, Five Houses, Clapton, Middlesex.

1866 HOWARD, EDWARD, M.D.

1875 HOWSE, HENRY GREENWAY, M.S. (C.), Surgeon to Guy's Hospital, and to the Evelina Hospital for Sick Children, 10, St. Thomas's-street, S.E. (C. 1878-80.)

†1856 HUDSON, JOHN, M.D., 11, Cork-street, Bond-street, W.

1854 HULKE, JOHN WHITAKER, F.R.S., Surgeon to the Middlesex Hospital and Surgeon to the Royal London Ophthalmic Hospital, 10, Old Burlington-street, W. (C. 1863-5. S. 1868-72. V.-P. 1873-6, T. 1877-9.)

1854 HULME, EDWARD CHARLES, Woodbridge-road, Guildford.

1853 HUMBY, EDWIN, M.D., 83, Hamilton-terrace, St. John's Wood, N.W.

1874 HUMPHREYS, HENRY, M.D., Physician to the Children's Hospital at Pendlebury, 106, Eccles Old-road, Eccles, near Manchester.

1852 HUTCHINSON, JONATHAN (PRESIDENT), Surgeon to the London Hospital, and to the Royal London Ophthalmic Hospital, Moorfields, 15, Cavendish-square, W. (C. 1856-9. V.-P. 1872-3. P. 1879-80.)

1880 INGRAM, ERNEST FORTESCUE, Chelsea Infirmary, Call-street, Chelsea.

1865 JACKSON, J. HUGHLINGS, M.D., Physician to the London Hospital, Physician to the National Hospital for the Paralysed and Epileptic 3, Manchester-square, W. (C. 1872-3.)

1875 JALLAND, WILLIAM HAMERTON, St. Leonard's House, Museum-street, York.

‡1858 JARDINE, JOHN LEE, Capel, near Dorking, Surrey.

1847 JAY, EDWARD, 112, Park-street, Grosvenor-square, W.

O.M. JENNER, SIR WILLIAM, Bart., M.D., D.C.L., K.C.B., F.R.S., Consulting Physician to University College Hospital, 63, Brook-street, Grosvenor-square, W. (C. 1850-3. V.-P. 1862-4 1875-6. *Pres.* 1873-4

Elected

1875 JESSETT, FREDERIC BOWREMAN, Pier-road, Erith, Kent.

1879 JESSOP, CHARLES MOORE, Army Medical Department, China.

1866 JESSOP, THOMAS RICHARD, 31, Park-square, Leeds.

1878 JOHNSON, ARTHUR JUKES, Yorkville, Ontario, Canada.

1876 JOHNSON, CHARLES HENRY, late Staff Surgeon, Turkish Contingent, Repton, Burton-on-Trent.

O.M. JOHNSON, GEORGE, M.D., F.R.S. (*Treasurer*), Physician to King's College Hospital, 11, Savile-row, W. (C. 1846-50. V.-P. 1863-4. T. 1880.)

1854 JOHNSTONE, ATHOL A. W., St. Moritz House, 61, Dyke-road, Brighton.

1853 JONES, SYDNEY, M.B., Surgeon to St. Thomas's Hospital, 16, George-street, Hanover-square, W. (C. 1864-6.)

1862 JONES, THOMAS RIDGE, M.D., Physician to the Victoria Hospital for Sick Children, 4, Chesham-place, S.W.

1858 JONES, WILLIAM PRICE, M.D., Claremont-road, Surbiton, Kingston.

1867 KELLY, CHARLES, M.D., Professor of Hygiene, King's College, Strand. (C. 1874.)

1846 KENT, THOMAS J., 60, St. James's-street, S.W.

1852 KERSHAW, W. WAYLAND, M.D., Kingston-on-Thames.

1872 KESTEVEN, WILLIAM B., M.D. (C.), 401, Holloway-road, N. (C. 1879-80.)

1879 KESTEVEN, WILLIAM HENRY, 401, Holloway-road, N.

1859 KIALLMARK, HENRY WALTER, 5, Pembridge-gardens, Bayswater, W. (C. 1875-6.)

1867 KING, EDWIN HOLBOROW, Killcott, Godalming, Surrey.

1871 KING, ROBERT, M.B., 48, Harley-street, W.

1852 KINGDON, J. ABERNETHY, Surgeon to the City Dispensary, and to the City of London Truss Society, 2, New Bank-buildings, Lothbury, E.C.

‡1856 KINGSLEY, HENRY, M.D., Physician to the Stratford Infirmary, Stratford-on-Avon, Warwickshire.

1878 KLEIN, EDWARD EMANUEL, M.D., F.R.S., 5, Longridge-road, Earl's-court, S.W.

1877 KNIGHT, CHARLES FREDERICK, 8, Northampton-square, Clerkenwell, E.C.

1875 LACY, C. S. DE LACY, 5, Ovington-square, Brompton, S.W.

1878 LANCEREAUX, ETIENNE, M.D., 3, Rue St. Arnaud, Paris.

‡1865 LANCHESTER, HENRY THOMAS, M.D., 53, High-street, Croydon.

1877 LANG, ALEXANDER, M.B., 51, Warwick-road, S.W.

1851 LANGMORE, JOHN C., M.B., 20, Oxford-terrace, Hyde-park, W. (C. 1858-61.)

1865 LANGTON, JOHN, Assistant Surgeon to and Lecturer on Anatomy at St. Bartholomew's Hospital, and Surgeon to the City of London Truss Society, 2, Harley-street, Cavendish-square, W.

1869 LARCHER, O., M.D. Par., Laureate of the Institute of France, of the Medical Faculty and Academy of Paris, 97, Rue de Passy, Paris. [M. Kliensieck, Libraire, Rue de Lille, 11, Paris, per Messrs. Longman.]

Elected

1873 LATHAM, PETER WALLWORK, M.D., Physician to Addenbrooke Hospital, and Downing Professor of Medicine, Cambridge University, 17, Trumpington-street, Cambridge.

1876 LAW, WILLIAM THOMAS, M.D., 20, Warrior Gardens, St. Leonards-on-Sea.

1853 LAWRENCE, HENRY JOHN HUGHES, Surgeon, Grenadier Guards' Hospital, Rochester-row, Westminster, S.W. (C. 1873-5.)

1859 LAWSON, GEORGE, Surgeon to the Middlesex Hospital, and Surgeon to the Royal London Ophthalmic Hospital, Moorfields, 12, Harley-street, Cavendish-square, W. (C. 1870-1.)

1879 LAYCOCK, GEORGE LOCKWOOD, M.B., 12, Upper Berkeley-street, Portman-square, W.

1875 LEDIARD, HENRY AMBROSE, M.D., Surgeon to the Cumberland Infirmary, 78, Lowther-street, Carlisle.

1852 LEE, HENRY, Consulting Surgeon to St. George's Hospital, 9, Savile-row, W. (C. 1860-2. V.-P. 1875-6.)

1879 LEECH, DANIEL JOHN, M.D., 96, Mosley-street, Manchester.

1877 LEES, DAVID B., M.D., Assistant Physician to St. Mary's Hospital, and to the Hospital for Sick Children, 2, Thurloe Houses, Thurloe-square, S.W.

1867 LEES, JOSEPH, M.D., 21, Brixton-road, S.W.

1877 LEESON, ARTHUR EDMUND. M.A., M.D., 45, Devonshire-street, Portland-place, W.

1877 LEESON, JOHN RUDD, M.B., C.M., 6, Clifden-road, Twickenham.

1868 LEGG, JOHN WICKHAM, M.D., Assistant Physician to, and Lecturer on Pathological Anatomy at, St. Bartholomew's Hospital, 47, Green-street, Park-lane, W. (C. 1874-5.)

‡1867 LEUDET, T. EMILE, M.D. Par., Professor of Clinical Medicine, 49, Boulevard Cauchoise, Rouen, France. [M. Kliensieck, Libraire, Rue de Lille 11, Paris, per Messrs. Longman.]

1861 LICHTENBERG, GEORGE, M.D., 47, Finsbury-square, E.C.

1875 LINGARD, ALFRED, 2, Strand-terrace, Derby.

1877 LISTER, JOSEPH, D.C.L., LLD., F.R.S., (C.) Professor of Clinical Surgery at King's College, and Surgeon to King's College Hospital, 12, Park Crescent, Regent's Park, W. (C. 1880.)

1878 LITTLEJOHN, SALTER G., M.B., C.M., Central London District Schools, Hanwell.

1848 LITTLE, WILLIAM JOHN, M.D., 18, Park-street, Grosvenor-square, W. (C. 1851-2. V.-P. 1856-9.)

†1862 LITTLE, LOUIS S., China. [18, Park-street.]

1874 LIVEING, EDWARD, M.D., 52, Queen Anne-street, Cavendish-square, W.

1863 LIVEING, ROBERT, M.D., Physician to the Skin Department and Lecturer on Dermatology at the Middlesex Hospital, 11, Manchester-square, W. (C. 1876.)

1876 LONGHURST, ARTHUR EDWIN TEMPLE, M.D., 22, Wilton-street, Grosvenor-place, S.W.

Elected

1873 LUCAS, R. CLEMENT, M.B., M.S., Assistant Surgeon to Guy's Hospital, 18, Finsbury-square, E.C.

1873 LUCEY, WILLIAM C., M.D., Southampton, Hants.

1880 LUND, EDWARD, 22, St. John-street, Manchester.

1879 LUNN, JOHN REUBEN, St. Thomas's Hospital, Albert Embankment, S.E.

1876 LYELL, ROBERT WISHART, M.D., Assistant Surgeon to the Middlesex Hospital, and to the Royal London Ophthalmic Hospital, 26, Harley-street, Cavendish-square, W.

1871 MCCARTHY, JEREMIAH, M.A. (C.), Surgeon to the London Hospital, 15, Finsbury-square, E.C. (C. 1878-80.)

1873 MCCONNELL, J. F., Professor of Pathology, Medical College, Calcutta. [Per Grindlay & Co., Parliament-street.]

1871 MAC CORMAC, WILLIAM (C.), Surgeon to St. Thomas's Hospital, 13, Harley-street, W. (C. 1878-80.)

1875 MACKELLAR, ALEXANDER OBERLIN, Assistant Surgeon, St. Thomas's Hospital, Albert Embankment, S.E.

1873 MACKELLAR, PETER H., M.B., Medical Officer, Fever Hospital, Stockwell, S.W.

1870 MACKENZIE, GEORGE WELLAND, 13, William-street, Lowndes-square, S.W.

1870 MACKENZIE, JOHN T., Bombay, India. [East India United Service Club, 14, St. James's-square.]

1864 MACKENZIE, MORELL, M.D., Physician to the Hospital for Diseases of the Throat, and Lecturer on Diseases of the Throat at the London Hospital, 19, Harley-street, Cavendish-square, W.

1878 MACKENZIE, STEPHEN, M.D., Assistant Physician to, and Lecturer on Medicine at, the London Hospital, 26, Finsbury-square, E.C.

1879 MACLAGAN, THOMAS JOHN, M.D., 9, Cadogan-place, Belgrave-square, S.W.

1865 MACLAURIN, H. N., M.D.

1876 MACLEAN, THOMAS EDWIN, M.B., B.S.

1870 MACMAHON, JAMES THOMAS, L.K.Q.C.P.I., Beaumont Lodge, Howard-road, South Norwood, S.E.

1876 MACNAMARA, CHARLES, Surgeon to the Westminster Hospital, 13, Grosvenor-street, W.

1879 MACREADY, JONATHAN FORSTER, 125, Harley-street, W.

1875 MAHOMED, FREDERICK AKBAR, M.D., Medical Registrar, Guy's Hospital, 12, St. Thomas's-street, S.E.

1877 MAKINS, GEORGE HENRY, 134, York-road, Lambeth, S.E.

1876 MALLAM, BENJAMIN, Meadow Side, Lescroft-road, Staines.

1876 MAPLES, REGINALD, Spalding, Lincolnshire.

1857 MARCET, WILLIAM, M.D., F.R.S., Villa Bianca, Cannes, and 39, Grosvenor-street, W. (C. 1869-71.)

1868 MARSH, F. HOWARD, Assistant Surgeon to the Hospital for Sick Children, Assistant Surgeon to St. Bartholomew's Hospital, 36, Bruton-street, Berkeley-square. (C. 1876-7.)

1876 MARSHALL, FRANCIS JOHN, St. George's Hospital.

Elected

1846 MARSHALL, JOHN, F.R.S., Surgeon to University College Hospital, 10, Savile-row, W. (C. 1861.)

1856 MARTIN, ROBERT, M.D., Consulting Physician to St. Bartholomew's Hospital, 51, Queen Anne-street, Cavendish-square, W. (C. 1871-2.)

1860 MASON, FRANCIS, Surgeon to St. Thomas's Hospital, 5, Brook-street, Grosvenor-square, W. (C. 1873-5.)

1867 MASON, PHILIP BROOKES, Burton-on-Trent.

†1852 MAY, GEORGE, Jun., M.B., Surgeon, Royal Berkshire Hospital, Reading.

1874 MEREDITH, WILLIAM APPLETON, M.B., Assistant Surgeon to the Samaritan Hospital, 14, Old Burlington-street, W.

1859 MESSER, JOHN COCKBURN, M.D., Assistant Surgeon, R.N., Her Majesty's Ship "Edinburgh," Queensferry, N.B.

‡1867 MICKLEY, ARTHUR GEORGE, M.B., Derby-road, Nottingham.

1866 MICKLEY, GEORGE, M.A., M.B., St. Luke's Hospital, Old-street, E.C.

1877 MILNER, EDWARD, Surgeon to the Lock Hospital, 32, New Cavendish-street, Portland-place, W.

†1859 MONTEFIORE, NATHANIEL, 18, Portman-square, W.

1879 MOORE, NORMAN, M.D., Demonstrator of Morbid Anatomy and Warden of the College; the College, St. Bartholomew's Hospital.

1861 MOREHEAD, CHARLES, M.D., 11, North Manor-place, Edinburgh.

1847 MORGAN, JOHN, 3, Sussex-place, Hyde-park-gardens, W. (C. 1856-8.)

1875 MORGAN, JOHN H., Assistant Surgeon to the Charing Cross Hospital, and to the Hospital for Sick Children, 12, Chapel-street, Grosvenor-square, W.

1874 MORISON, ALEXANDER, M.B., C.M., 7, The Terrace, Green-lanes, N.

1869 MORRIS, HENRY, M.A., M.B., Surgeon to, and Lecturer on Anatomy and Practical Surgery at, the Middlesex Hospital, 2, Mansfield-street, Portland-place, W. (C. 1877-9.)

1879 MORRIS, MALCOLM ALEXANDER, Lecturer on Skin Diseases at St. Mary's Hospital, 63, Montagu-square, W.

1875 MORTON, JOHN, M.B., Guildford.

1879 MOULLIN, CHARLES W. MANSELL, M.B., 80, Porchester-terrace, W.

1860 MOXON, WALTER, M.D., Physician to Guy's Hospital, 6, Finsbury-circus, E.C. (C. 1868-70, V.P. 1876-8.)

1878 MUMFORD, WILLIAM LUGAR, M.D., 1, Bartlett's-passage, Holborn-circus, E.C.

1876 MUNRO, WILLIAM, M.D., C.M., 102, Carl-street, Lower Broughton-road, Manchester.

1872 MURRAY, J. JARDINE, 99, Montpellier-road, Brighton.

1864 MYERS, ARTHUR B. R., Surgeon to 1st Battalion Coldstream Guards, the Hospital, Vincent-square, Westminster, S.W. (C. 1872-3.)

1874 NANKIVELL, ARTHUR WOLCOT, St. Bartholomew's Hospital, Chatham.

1873 NETTLESHIP, EDWARD, Ophthalmic Surgeon to St. Thomas's Hospital, 4, Wimpole-street, Cavendish-square, W.

1875 NEWBY, CHARLES HENRY, 87, Adelaide-road, N.W.

Elected

1865 NEWMAN, WILLIAM, M.D., Stamford, Lincolnshire.

1868 NICHOLLS, JAMES, M.D., Chelmsford, Essex.

1876 NICHOLSON, JOHN FRANCIS, M.D., 29, Albion-street, Hull.

1878 NOOTT, W. M., 8, Kensington-park-road, W.

1864 NORTON, ARTHUR T., Surgeon to St. Mary's Hospital, 6, Wimpole-street, Cavendish-square, W. (C. 1877-9.)

1856 NUNN, THOMAS WILLIAM (V.-P.), Consulting Surgeon to the Middlesex Hospital, 8, Stratford-place, Oxford-street, W. (C. 1864-6. V.-P. 1878-80.)

1871 NUNNELEY, REV. FREDERICK BARHAM, M.D.

1873 O'FARRELL, GEORGE PLUNKETT, M.B., Tangier House, Boyle, Ireland.

1850 OGLE, JOHN W., M.D., Consulting Physician to St. George's Hospital 30, Cavendish-square, W. (C. 1855-6. S. 1857-60. C. 1861-3. V.-P. 1865-8.)

1876 OLIVER, JOHN FERENS, M.D., 12, Old Elvet, Durham.

1860 ORANGE, WILLIAM, M.D., Broadmoor, Wokingham, Berkshire.

1875 ORD, WILLIAM MILLER, M.D. (C.), Physician to, and Lecturer on Medicine at, St. Thomas's Hospital, 7, Brook-street, Hanover-square, W. (C. 1880.)

1878 ORLEBAR, HOTHAM GEORGE, M.D., House Physician, City of London Hospital for Diseases of the Chest, Victoria Park, E.

1879 ORMEROD, J. A., M.B., Casualty Physician to St. Bartholomew's Hospital, 25, Upper Wimpole-street, W.

1875 OSBORN, SAMUEL, 10, Maddox-street, Bond-street, W.

1876 OTTLEY, WALTER, M.B., 93, Ladbroke-grove, Notting-hill, W.

1865 OWLES, JAMES ALLDEN, M.D., 204, Burlington-street, Liverpool.

1875 PAGE, HERBERT WILLIAM, M.A., M.C. Cantab., Assistant Surgeon to and Lecturer on Operative and Practical Surgery at St. Mary's Hospital, 28, New Cavendish-street, W.

1870 PAGET, SIR JAMES, Bart., D.C.L., F.R.S., Consulting Surgeon to St. Bartholomew's Hospital, 1, Harewood-place, Hanover-square, W.

1872 PARKER, ROBERT WILLIAM, Assistant Surgeon to the East London Children's Hospital, 8, Old Cavendish-street, W.

1874 PARKER, RUSHTON, M.B., B.S., 69, Rodney-street, Liverpool.

1853 PARKINSON, GEORGE, 50, Brook-street, Grosvenor-square, W.

1865 PAVY, FREDERICK WILLIAM, M.D., F.R.S., Physician to, and Lecturer on Medicine at, Guy's Hospital, 35, Grosvenor-street, W. (C. 1872-4.)

1868 PAYNE, JOSEPH FRANK, B.A., M.D. (HON. SECRETARY), Assistant Physician to, and Lecturer on Pathological Anatomy at, St. Thomas's Hospital, 78, Wimpole-street, Cavendish-square, W. (C. 1873-5. S. 1880.)

O.M. PEACOCK, THOMAS BEVILL, M.D. (TRUSTEE), Consulting Physician to St. Thomas's Hospital, and Consulting Physician to the City of London Hospital for Diseases of the Chest, 20, Finsbury-circus, E.C. (C. 1846-9. S. 1850-1. V.-P. 1852-6. C. 1858-61. P. 1865-6. V.-P. 1867-70.)

Elected

1872 PEARCE, JOSEPH CHANING, M.D., C.M., The Manor House, Brixton-rise, S.W.

1878 PEARSE, THOMAS FREDERICK, M.D., Bramshott, Liphook, Hants.

1863 PEARSON, DAVID R., M.D., 23, Upper Phillimore-place, Kensington, W.

1879 PEEL, ROBERT, 130, Collins-street East, Melbourne, Victoria.

1878 PHILIPPS, SUTHERLAND REES, M.D., 3, Berkeley-place, Cheltenham.

1871 PHILLIPS, CHARLES DOUGLAS F., M.D., 2, Grosvenor-square, W.

1878 PHILLIPS, JOHN WALTER, Physician to the Benevolent Asylum of Melbourne, 30, Stanley-street, West Melbourne, Victoria.

1877 PHILLIPS, RICHARD, 27, Leinster-square, Bayswater, W.

1875 PHILPOT, HARVEY JOHN.

1863 PICK, THOMAS PICKERING, Surgeon to, and Lecturer on Anatomy at, St. George's Hospital, 13, South Eaton-place, S.W. (C. 1870-1.)

1875 PITMAN, HENRY A., M.D., Consulting Physician to St. George's Hospital, 28, Gordon-square, W.C.

1867 PITT, EDWARD G., M.D.

1876 PITTS, BERNARD, M.A., M.B., Resident Assistant Surgeon, St. Thomas's Hospital, S.E.

1846 POLLOCK, GEORGE D. (TRUSTEE), Consulting Surgeon to St. George's Hospital, 36, Grosvenor-street, W. (S. 1850-3. C. 1854-6. V.-P. 1863-5. P. 1875-6.)

1850 POLLOCK, JAMES EDWARD, M.D. (V.-P.), Physician to the Hospital for Consumption and Diseases of the Chest, Brompton, 52, Upper Brook-street, W. (C. 1862-4. V.-P. 1879-80.)

1870 POORE, GEORGE VIVIAN, M.B., Assistant Physician to University College Hospital, 30, Wimpole-street, W.

1876 PORT, HEINRICH, M.D., 48, Finsbury-square, E.C.

1879 POTTER, HENRY PERCY, St. Thomas's Hospital.

1866 POWELL, RICHARD DOUGLAS, M.D., Physician to the Hospital for Consumption and Diseases of the Chest, Brompton, 15, Henrietta-street, Cavendish-square, W. (C. 1873-5. S. 1877-9.)

1865 POWER, HENRY, Ophthalmic Surgeon to St. Bartholomew's Hospital, 37A, Great Cumberland-place, Hyde-park, W. (C. 1876-7.)

1856 PRIESTLEY, WILLIAM OVEREND, M.D., Consulting Physician-Accoucheur to King's College Hospital, and to the St. Marylebone Infirmary, 17, Hertford-street, Mayfair, W.

†1848 PURNELL, JOHN JAMES, Surgeon to the Royal General Dispensary, Woodlands, Streatham-hill, S.W. (C. 1858-61.)

1865 PYE-SMITH, PHILIP HENRY, M.D., Assistant Physician to, and Lecturer on Physiology at, Guy's Hospital, 56, Harley-street, Cavendish-square, W. (C. 1874-7.)

Elected

O.M. QUAIN, RICHARD, M.D., F.R.S. (TRUSTEE), Consulting Physician to the Hospital for Consumption and Diseases of the Chest, Brompton, 67, Harley-street, Cavendish-square, W. (C. 1846-51. S. 1852-6. T. 1857-68. *Pres.* 1869-70. V.-P. 1871-3.)

1859 RADCLIFFE, CHARLES BLAND, M.D., Physician to the Westminster Hospital, 25, Cavendish-square, W.

1872 RALFE, CHARLES HENRY, M.D., M.A., Assistant Physician to the London Hospital, 26, Queen Anne-street, W. (C. 1877-9.)

1857 RAMSKILL, J. SPENCE, M.D., Consulting Physician to the London Hospital, Physician to the National Hospital for the Paralysed and Epileptic, 5, St. Helen's-place, Bishopsgate-street, E.C.

1848 RANDALL, JOHN, M.D., Medical Officer, St. Marylebone Infirmary, 35, Nottingham-place, W. (C. 1864-6.)

1875 RANGER, W. GILL, 4, Finsbury-square, E.C.

1857 RANKE, HENRY, M.D., Munich.

1865 RASCH, ADOLPHUS A., M.D., Physician for Diseases of Women to the German Hospital, 7, South-street, Finsbury-square, E.C.

1870 RAY, EDWARD REYNOLDS, Dulwich, S.E.

1871 RAYNER, HENRY, M.D., Lecturer on Mental Diseases at St. Thomas' Hospital, Medical Superintendent, Middlesex County Lunatic Asylum, Hanwell, W.

1858 REED, FREDERICK GEORGE, M.D., 46, Hertford-street, Mayfair, W.

1866 REEVES, HENRY ALBERT, Assistant Surgeon to the London Hospital, 6, Grosvenor Street, W.

1875 REID, ROBERT WILLIAM, M.D., C.M., Senior Demonstrator of Anatomy and Joint Demonstrator of Morbid Anatomy at St. Thomas's Hospital, 10, Nottingham-place, W.

1854 REYNOLDS, J. RUSSELL, M.D., F.R.S., Consulting Physician to University College Hospital, 38, Grosvenor-street, W. (C. 1868-9.)

1871 RICHARDS, J. PEEKE, Medical Superintendent, Middlesex County Lunatic Asylum, Hanwell, W.

1866 RIVINGTON, WALTER, M.S. Lond., Surgeon to the London Hospital, 22, Finsbury-square, E.C.

‡1865 ROBERTS, DAVID LLOYD, M.D., Physician to St. Mary's Hospital, Manchester, 23, St. John's-street, Manchester.

1871 ROBERTS, FREDERICK THOMAS, M.D., Professor of Materia Medica at University College, and Physician to University College Hospital, and to the Hospital for Consumption, &c., Brompton, 53, Harley-street, Cavendish-square, W.

1878 ROBERTS, WILLIAM HOWLAND, M.D., Surgeon, Madras Army, Madras, [East India United Service Club, St. James's Square].

1856 ROBINSON, THOMAS, M.D., 5, Woburn-square, W.C.

1858 ROLLESTON, GEORGE, M.D., F.R.S., Linacre Professor of Anatomy, University of Oxford, Park Grange, Oxford.

1876 ROPER, ARTHUR, 17, Granville Park, Blackheath, S.E.

Elected

1858 Rose, Henry Cooper, M.D., Surgeon to the Hampstead Dispensary, High-street, Hampstead, N.W. (C. 1878-4.)

1876 Rose, William, M.B., B.S., Assistant Surgeon to King's College, 21, Welbeck Street, Cavendish-square, W.

1879 Ross, James, M.D., C.M., 335, Oxford-street, Manchester.

1875 Rossiter, George Frederick, 14, Melina-crescent, Weston-super-Mare.

1877 Roth, Bernard, M.S., 48, Wimpole Street, Cavendish-square, W., and 18, Grand Parade, Brighton.

1858 Rouse, James, Surgeon to St. George's Hospital, 2, Wilton-street, Grosvenor-place, S.W.

1869 Rutherford, William, M.D., F.R.S., Professor of Physiology in the University of Edinburgh, 14, Douglas Crescent, Edinburgh.

1853 Salter, S. James A., M.B., F.R.S. (V.-P,), Late Dental Surgeon to Guy's Hospital, 44, New Broad-street, City, E.C. (C. 1861-3. V.-P. 1880.)

1852 Sanderson, Hugh James, M.D., 26, Upper Berkeley-street, Portman-square, W.

1854 Sanderson, John Burdon, M.D., F.R.S., Jodrell Professor of Human Physiology at University College (C. 1864-7. V.-P. 1873-4.), 26, Gordon-square, W.C.

1877 Sangster, Alfred, M.B., B.A., 7, Old Burlington-street, W.

1875 Sangster, Charles, 148, Lambeth-road, S.E.

1877 Sankey, H. R. O., Sandywell-park, near Cheltenham.

‡1847 Sankey, W. H. Octavius, M.D., Sandywell-park, near Cheltenham. (C. 1855.)

1871 Saunders, Charles Edward, M.D., 21, Lower Seymour-street, Portman-square, W.

1873 Savage, George Henry, M.D., Bethlem Royal Hospital, St. George's-road, S.E.

1854 Scott, John, 10, Tavistock-square, W.C.

1877 Semon, Félix, M.D., 59, Welbeck-street, Cavendish-square.

1852 Semple, Robert Hunter, M.D., Physician to the Bloomsbury Dispensary, 8, Torrington-square, W.C. (C. 1859-61.)

1872 Sergeant, Edward, Medical Officer of Health, Bolton, Yorkshire.

1876 Sharkey, Seymour, M.B., Assistant Physician to St. Thomas's Hospital, 16, Palace-road, Albert Embankment, S.E.

1880 Shattock, S. G., Curator, University College Museum, 9, Downshire-hill, Hampstead.

1877 Sheppard, Charles E., 14, Addison-gardens, Kensington, W.

1856 Shilliton, Buxton, Surgeon to the Great Northern Hospital, and to the Lock Hospital, 2, Frederick's-place, Old Jewry, E.C.

1855 Sibley, Septimus W. (V.-P.), 7, Harley-street, Cavendish-square, W. (C. 1863-5. V.-P. 1879-80.)

1875 Siddall, Joseph Bower, M.D., C.M., Duxmere-house, Ross, Herefordshire.

Elected

1847 SIEVEKING, EDWARD H., M.D., Physician to St. Mary's Hospital, 17 Manchester-square, W. (C. 1854-7. V.-P. 1864-5.)

1880 SILCOCK, A. QUARRY, M.B., B.S., University College Hospital.

O.M. SIMON, JOHN, C.B., D.C.L., F.R.S., Consulting Surgeon to St. Thomas's Hospital, 40, Kensington-square, W. (C. 1846-8. V.-P. 1855-9. *Pres.* 1867-8. V.-P. 1869-71.)

1866 SIMS, FRANCIS MANLEY BOLDERO, Assistant Surgeon to the Hospital for Diseases of the Skin, and Surgeon to the St. George's Dispensary, 12, Hertford-street, May-fair, W.

1865 SIMS, J. MARION, M.D., 267, Madison-avenue, New York.

1877 SKINNER, WILLIAM A., 45, Upper Belgrave-street, S.W.

1875 SMEE, ALFRED HUTCHINSON, 7, Finsbury-circus, E.C.

1879 SMITH, E. NOBLE, 24, Queen Anne-street, Cavendish-square.

1872 SMITH, GILBART, M.B., Assistant Physician to the London Hospital, Physician to the Royal Hospital for Diseases of the Chest, City-road, Visiting Physician to the Margaret-street Infirmary for Consumption, 68, Harley-street, Cavendish-square, W.

1875 SMITH, GEORGE JOHN MALCOLM, M.B., Hurstpierpoint, Sussex.

1863 SMITH, HENRY, Surgeon to, and Professor of Surgery at, King's College Hospital, 82, Wimpole-street, Cavendish-square, W. (C. 1873-4.)

1866 SMITH, HEYWOOD, M.D., Physician to the Hospital for Women, 2, Portugal-street, Grosvenor-square, W.

SMITH (P. H. PYE), see PYE-SMITH.

1846 SMITH, PROTHEROE, M.D., Physician to the Hospital for Women, 42, Park-street, Grosvenor-square, W.

1873 SMITH, RICHARD T., M.D., Physician to the St. Pancras Dispensary, 53, Haverstock-hill, N.W.

1869 SMITH, ROBERT SHINGLETON, M.D., Lecturer on Physiology, Bristol Medical School, 9, Richmond-hill, Clifton, Bristol.

1878 SMITH, HERBERT URMSON, M.B., Cape Colony.

1879 SMITH, ROBERT, M.A., M.B., Assistant Physician to Charing Cross Hospital, W.C.

1856 SMITH, THOMAS, Surgeon to St. Bartholomew's Hospital, 5, Stratford-place, Oxford-street, W. (C. 1867-9. V.-P. 1877-8.)

1866 SMITH, WILLIAM, Melbourne, Australia.

1870 SMITH, WILLIAM JOHNSON (C.), Surgeon, Seamen's Hospital, Greenwich, S.E. (C. 1879-80.)

1869 SMITH, WILLIAM WILBERFORCE, M.D., 2, Eastbourne-terrace, Bishop's-road, W.

1870 SNOW, WILLIAM VICARY, M.D., Richmond Gardens, Bournemouth.

1868 SOUTHEY, REGINALD, M.D., Physician to St. Bartholomew's Hospital, 6, Harley-street, Cavendish-square, W.

1868 SPRY, G. FREDERICK HUME, M.D., 2nd Life Guards, Army and Navy Club, Pall-mall, S.W.

1855 SQUIRE, WILLIAM, M.D., 6, Orchard-street, Portman-square, W. (C. 1870-2.)

Elected

1861 SQUIRE, ALEXANDER BALMANNO, 24, Weymouth-street, Portland-place, W.

1876 STARTIN, JAMES, 17, Sackville-street, Piccadilly, W.

1854 STEWART, WILLIAM EDWARD, 16, Harley-street, Cavendish-square, W.

1879 STIRLING, EDWARD CHARLES, Lecturer on Physiology at St. George's Hospital, 60, Great Cumberland-place, Hyde-park, W.

†1853 STREATFEILD, J. F., Surgeon to the Royal London Ophthalmic Hospital, Moorfields, and Ophthalmic Surgeon to University College Hospital, 15, Upper Brook-street, W.

1875 STURGE, W. A., M.D., Assistant Physician to the Royal Free Hospital, 9, Wimpole-street, Cavendish-square, W.

1863 STURGES, OCTAVIUS, M.D., Physician to the Westminster Hospital, 85, Wimpole-street, Cavendish-square, W.

1871 SUTHERLAND, HENRY, M.D., 6, Richmond-terrace, Whitehall, S.W.

1876 SUTRO, SIGISMUND, M.D., Senior Physician to the German Hospital, 37A, Finsbury-square, E.C.

1864 SUTTON, HENRY G., M.B., Physician to and Lecturer on Pathology at, the London Hospital, Physician to the City of London Hospital for Diseases of the Chest, 9, Finsbury-square, E.C. (C. 1875-6.)

‡1867 SWAIN, WILLIAM PAUL, 20, Ker-street, Devonport.

‡1857 SYMONDS, FREDERICK, Surgeon to the Radcliffe Infirmary, 35, Beaumont-street, Oxford.

1870 TAIT, ROBERT LAWSON, Surgeon to the Birmingham and Midland Hospital for Women, 7, Great Charles-street, Birmingham.

‡1856 TAPP, W. DENNING, Hillside-house, Hatherley-road, Cheltenham.

1864 TATHAM, JOHN, M.D., Physician to the Hospital for Consumption and Diseases of the Chest, Brompton, 12, George-street, Hanover-square, W.

1870 TAY, WARREN, Surgeon to, and Demonstrator of Practical Anatomy at, the London Hospital, 4, Finsbury-square, E.C.

1871 TAYLOR, FREDERICK, M.D. (C.), Assistant Physician to Guy's Hospital, 15, St. Thomas's-street, S.E. (C. 1879-80.)

1880 TAYLOR, SEYMOUR, M.B., M.C., 140, South Lambeth-road.

1861 TREVAN, WILLIAM FREDERIC, Surgeon to the West London Hospital, 10, Portman-square, W.

1879 THIN, GEORGE, M.D., 22, Queen Anne-street, Cavendish-square, W.

1870 THOMAS, JOHN DAVIES, M.B., University College Hospital (India).

1852 THOMPSON, SIR HENRY, Knt., Emeritus Professor of Clinical Surgery in University College, 35, Wimpole-street, Cavendish-square, W. (S. 1859-63. C. 1865-67. V.-P. 1868-70.)

1874 THORNTON, JOHN KNOWSLEY, M.B., Surgeon to the Samaritan Free Hospital for Women and Children, 83, Park-street, Grosvenor-square.

1872 THORNTON, WILLIAM PUGIN, Surgeon to the Hospital for Diseases of the Throat, and to the St. Marylebone General Dispensary, 42, Devonshire-street, Portland-place, W.

Elected

1865 THOROWGOOD, J. C., M.D., Lecturer on Materia Medica at the Middlesex Hospital, Physician to the City of London Hospital for Diseases of the Chest, 61, Welbeck-street, W. (C. 1876-78.)

1877 TIBBITS, HERBERT, F.R.C.P. Ed., 68, Wimpole-street, W.

1880 TIRARD, NESTOR ISIDORE (C.), M.B.Lond., King's College Chambers, W.C.

1856 TOMES, J., F.R.S., Consulting Dental Surgeon to the Middlesex Hospital, Upwood Gorse, Caterham, Surrey. (C. 1867-9.)

1864 TONGE, MORRIS, M.D., Harrow-on-the-hill, Middlesex.

1872 TOWNSEND, THOMAS SUTTON, 68, Queen's Gate, South Kensington.

1851 TROTTER, JOHN W., Surgeon-Major, Coldstream Guards, Bossall Vicarage, York. (C. 1865-9.)

1859 TRUMAN, EDWIN THOMAS, Surgeon-Dentist in Ordinary to Her Majesty's Household, 23, Old Burlington-street, W.

1867 TUCKWELL, HENRY MATTHEWS, M.D., Physician to the Radcliffe Infirmary, 64, High-street, Oxford.

1858 TUDOR, JOHN, Dorchester, Dorset.

†1875 TURNER, FRANCIS CHARLEWOOD, M.D., Physician to the London Hospital, 15, Finsbury-square, E.C.

1863 TURNER, JAMES SMITH, Dental Surgeon to the Middlesex Hospital, 12, George-street, Hanover-square, W.

1858 TURTLE, FREDERICK, Clifton Lodge, Woodford, Essex.

1878 TYRRELL, WALTER.

1880 TYSON, WILLIAM JOSEPH, M.B., 89, Sandgate-road, Folkstone.

1854 VASEY, CHARLES, 5, Cavendish-place, Cavendish-square, W.

1867 VENNING, EDGCOMBE, late Surgeon, 1st Life Guards, 87, Sloane-street.

1868 VINCENT, OSMAN, Surgeon to the National Orthopædic Hospital, 45, Seymour-street, Portman-square, W.

†1867 WAGSTAFFE, WILLIAM WARWICK (C.), B.A., Assistant Surgeon to St. Thomas's Hospital, 2, Palace-road, Albert Embankment, S.E. (C. 1874, C. 1878-80. S. 1875-7.)

O.M. WAITE, CHARLES D., M.D., Senior Physician to the Westminster General Dispensary, 3, Old Burlington-street, W.

1873 WALSHAM, WILLIAM J., M.B., C.M., Demonstrator of Anatomy and Operative Surgery at St. Bartholomew's Hospital, Surgeon to the Metropolitan Free Hospital and to the Royal Hospital for Diseases of the Chest, 27, Weymouth-street, Portland-place.

1859 WALTERS, JOHN, M.B., Reigate, Surrey.

1847 WARD, T. OGIER, M.D., 12, Place de la Mare, Caen. (C. 1851-3.)

1858 WARDELL, JOHN RICHARD, M.D., Calverley-park, Tunbridge Wells.

1877 WARNER, FRANCIS, M.D., Assistant Physician to the London Hospital and to the East London Hospital for Children, 24, Harley-street.

1877 WATERHOUSE, CHARLES, M.B., M.C., Aigburth, Liverpool.

1879 WATERS, JOHN HENRY, M.D., 101, Jermyn-street, St. James's, S.W.

Elected

1878 WATNEY, HERBERT, M.D., Lecturer on Materia Medica at St. George's Hospital, 1, Wilton-crescent, S.W.

1855 WATSON, SIR THOMAS, Bart., M.D., F.R.S., 16, Henrietta-street, Cavendish-square, W. (*Pres.* 1857-8. V.-P. 1859-63.)

1865 WATSON, W. SPENCER, Surgeon to the Great Northern Hospital, Surgeon to the Royal South London Ophthalmic Hospital, 7, Henrietta-street, Cavendish-square, W. (C. 1875-6.)

1860 WAY, JOHN, M.D., 4, Eaton-square, S.W. (C. 1873-4.)

†1858 WEBER, HERMANN, M.D. (V.-P.), Physician to the German Hospital, 10, Grosvenor-street, Grosvenor-square, W. (C. 1867-70. V.-P. 1878-80.)

1876 WEIR, ARCHIBALD, M.D., St. Mungho's, Great Malvern.

1864 WELCH, THOMAS DAVIES, M.D., Wilton Lodge, Queen's-road, Weybridge, Surrey.

1853 WELLS, THOMAS SPENCER, Surgeon to the Samaritan Free Hospital for Women and Children, 3, Upper Grosvenor-street, W. (C. 1865-8. V.-P. 1876-7.)

†1851 WEST, CHARLES, M.D., Consulting Physician to the Hospital for Sick Children, Ascham House, Bournemouth. (C. 1856-7.)

1877 WEST, SAMUEL, M.B., Assistant Physician to the City of London Hospital for Diseases of the Chest, Victoria-park, Casualty Physician to St. Bartholomew's Hospital, 15, Wimpole-street, Cavendish-square, W.

1878 WHARTON, HENRY THORNTON, M.A., 39, St. George's-road, Kilburn.

1867 WHIPHAM, THOMAS TILLYER, M.D. (C.), Physician to, and Lecturer on Clinical Medicine at, St. George's Hospital, 37, Green-street, Grosvenor-square, W. (C. 1880.)

1869 WHIPPLE, JOHN H. C., M.D., Assistant Surgeon, 1st Battalion Coldstream Guards, Hospital, Vincent-square, Westminster, S.W.

1877 WHITE, CHARLES HAYDON, Brathay House, Tufnell-park, N.

‡1868 WHITEHEAD, WALTER, 248, Oxford-road, Manchester.

1877 WHITMORE, WILLIAM TICKLE, 7, Arlington-street, S.W.

1870 WICKSTEED, FRANCIS WILLIAM, Chester House, Weston-super-Mare.

1879 WILCOX, HENRY, M.B., Hurst-villa, Lewisham High-road, S.E.

1867 WILCOX, RICHARD WILSON, Temple-square, Aylesbury, Bucks.

1869 WILKIN, JOHN F., M.D., M.C., New Beckenham, Kent.

1871 WILKINSON, J. SEBASTIAN, Surgeon to the Central London Ophthalmic Hospital, 83, Wimpole-street, W.

1864 WILKS, ALFRED G. P., M.A., M.B., Charlemont House, Spencer-road, Ryde, Isle of Wight.

1855 WILKS, SAMUEL, M.D., F.R.S., Physician to Guy's Hospital, 77, Grosvenor-street, W. (C. 1857-60. V.-P. 1869-72.)

1879 WILLCOCKS, FREDERICK, M.B., 52, Narsdale-villas, Kensington.

1869 WILLIAMS, ALBERT, M.D., 60, Kirkdale, Sydenham, S.E.

O.M. WILLIAMS, C. J. B., M.D., F.R.S., Consulting Physician to the Hospital for Consumption and Diseases of the Chest, Brompton [47, Upper Brook-street, Grosvenor-square, W.]. (*Pres.* 1846-7. V.-P. 1848-52. C. 1853-5. V.-P. 1858-61.)

Elected

‡1858 WILLIAMS, CHARLES, Surgeon to the Norfolk and Norwich Hospital, 9, Prince of Wales-road, Norwich.

1866 WILLIAMS, CHARLES THEODORE, M.D., Physician to the Hospital for Consumption and Diseases of the Chest, Brompton, 47, Upper Brook-street, Grosvenor-square, W. (C. 1875-8.)

1872 WILLIAMS, JOHN, M.D. (C.), Assistant Obstetric Physician to University College Hospital, 28, Harley-street, Cavendish-square, W. (C. 1878-80.)

1864 WILLIAMS, W. RHYS, M.D., Commissioner in Lunacy, 19, Whitehall-place, S.W.

1876 WILLIAMSON, JAMES MANN, M.D., Ventnor, Isle of Wight.

1863 WILLIS, FRANCIS, M.D., Braceborough, Stamford.

1859 WILSON, EDWARD THOMAS, M.B., Montpelier-terrace, Cheltenham.

1859 WILSON, ROBERT JAMES, F.R.C.P. Ed., 7, Warrior-square, St. Leonard's-on-Sea.

1863 WILTSHIRE, ALFRED, M.D., Joint Lecturer on Midwifery at St. Mary's Hospital, 57, Wimpole-street, Cavendish-square, W.

‡1861 WINDSOR, THOMAS, Surgeon to the Salford Royal Hospital, Woodcroft, Dudley-road, Manchester.

1874 WISEMAN, JOHN GREAVES, Dearden-street, Ossett, Yorkshire.

1865 WITHERBY, WILLIAM H., M.D., Pitt-place, Coombe, Croydon.

1850 WOOD, JOHN, F.R.S., Surgeon to, and Professor of Clinical Surgery at, King's College Hospital, 68, Wimpole-street, W. (C. 1857-9. V.-P. 1872-4.)

1854 WOOD, WILLIAM, M.D., Physician to St. Luke's Hospital, 99, Harley-street, W.

1876 WOOD, WILLIAM EDWARD RAMSDEN, M.A., M.B. Cantab., Bethlem Royal Hospital, St. George's-road, S.E.

1877 WOODHOUSE, THOMAS JAMES, M.D., 85, High-street, Fulham, S.W.

1879 WOODWARD, G. P. M., M.D., Deputy Surgeon General, Puckeridge, Hertfordshire.

1865 WORKMAN, CHARLES JOHN, M.D., Titherley, Teignmouth, Devon.

1863 WORLEY, WILLIAM CHARLES, 43, De Beauvoir-road, N.

1869 WYMAN, W. S., M.D., Westlands, Upper Richmond-road, Putney, S.W.

1869 YEO, J. BURNEY, M.D., Physician with Charge of Out-Patients to King's College Hospital, and Assistant Physician to the Brompton Hospital for Consumption, 44, Hertford-street, Mayfair, W.

1872 YOUNG, HENRY, M.B., Monte Video, South America.

ANNUAL REPORT OF COUNCIL.

1879-80.

In presenting their Annual Report the Council are very glad to be able to congratulate the members, as usual, on the continuance of the Society's prosperity.

The total number of members is now 602; 28 new members having been elected during the Session of 1878-9.

Nine members have resigned.

The Society has to regret the loss of ten members by death:—Hermann Beigel, Charles Murchison, Tilbury Fox, Charles F. Maunder, Charles R. Nicoll, Arthur Leared, George W. Callender, Thomas Bell Hay (New Zealand), J. Soelberg Wells.

The names of many in this list will be recognised as those of members who have contributed largely to the 'Transactions,' and in other ways have rendered important services to the Society; but all will feel that foremost stands that of Dr. Charles Murchison.

For a long time to come the loss of Dr. Murchison must seem irreparable. He joined the Society in 1854, and the example which he set for twenty-five years of industry which never flagged, of extreme accuracy in clinical and pathological work, of bold and unhesitating expression in word and deed of what he thought right, must be reckoned of not less value than the more direct services which he rendered as Hon. Secretary, Treasurer, and President, and by nearly 150 contributions to the Society's 'Transactions.'

A report on Pyæmia, Septicæmia, and allied diseases was received at the end of the last Session of the Society from the Committee appointed to investigate those subjects, and is signed by William Smith Greenfield, M.D., Charles Henry Ralfe, M.D., Marcus Beck, and Jeremiah McCarthy.

It will be found printed at length in the current volume of the 'Transactions.' The Council feel that the Society, while heartily thanking those gentlemen who have taken upon themselves the labour of the inquiry, may congratulate itself upon this valuable contribution to its 'Proceedings,' representing, as it does, a summary of the knowledge now obtainable regarding those obscure affections of which it treats. The Council confidently hope that the Government, which contributed £350 towards the cost of the inquiry, will, by the result, feel strengthened in their efforts to promote the public welfare by the encouragement of scientific pathological research.

Lardaceous disease, in reference to its anatomical distribution and pathological relations, formed the special subject of debate in the last Session; and the Council feel that the Society is much indebted to Dr. Dickinson for the admirably clear and concise manner in which he introduced it, and to those members who brought forward illustrative specimens.

The record of the debate forms an important part of the current volume of the Society's 'Transactions.'

At the suggestion of the President, a Committee was appointed during the past Session to report to the Council on the advisability of permitting specimens to be shown without oral communication, and as a result, the Council determined on the adoption of a Code of Regulations, which has been for some weeks now in the hands of members of the Society. The plan has seemed, during the short time in which it has been in operation, to work well; and the Council hope that it will prove of great permanent value by economising the too short time which the Society has at its disposal for dealing with the large stores of pathological material submitted to it.

The income of the Society during the past year, excluding the Government Grant to the Pyæmia Committee, has amounted to £622 6s. 0d., of which the sum of £463 1s 0d. was formed by members' subscriptions and admission fees, and £61 0s. 3d. by sale of the Society's 'Transactions.'

The total expenditure during the year has been £588 17s. 3d., of which the sum of £417 1s. 9d. represents the cost to the Society of the volume of 'Transactions.'

JONATHAN HUTCHINSON.

January 6th, 1880.

THE PATHOLOGICAL SOCIETY,

Cr. *In Account with the Treasurer*, J. W. HULKE, F.R.S., *33rd Session*, 1878–79. **Dr.**

	£	s.	d.	£	s.	d.
By *Balance* at Union Bank of London, 1st January, 1879				354	9	8
(Mem. Of this amount, £298 12s. is the balance of £300, Government grant, for investigations on pyæmia.)						
Subscriptions, &c.:						
390 Annual Subscriptions, 1878-79	409	10	0			
4 Ditto, Arrears, 1877-78	4	4	0			
24 Admission Fees	25	4	0			
4 Composition Fee, Non-Resident	8	8	0			
1 Ditto, Resident	15	15	0			
				463	1	0
Sale of Transactions: May account	45	1	6			
November ditto	8	5	6			
December ditto	7	13	3			
				61	0	3
Dividends on £1067 15*s.* 1*d.* Consols, January	15	13	7			
July	15	13	7			
				31	7	2
Receipt from Dangerfield for use of Lithographic stones				11	0	0
				£920	18	1

	£	s.	d.	£	s.	d.
To *Meetings:*						
Payment to Royal Medical and Chirurgical Society for use of Rooms, Gas, &c.	63	0	0			
Refreshments, Waiters, Management	36	15	0			
Richard Coldrey, Meetings, &c.	8	0	0			
Microscopes and Lamps (Pillischer)	5	10	0			
Transactions: Vol. XXX (750 copies):				113	5	0
Printing, Binding, and Delivery (Adlard)	244	15	10			
Lithography and Woodcuts (Burgess)	36	14	0			
Ditto (West)	48	16	6			
Ditto (Smith)	24	0	0			
Ditto, ditto	5	3	0			
Ditto (Mintern)	54	9	5			
Index (Wheatley)	3	3	0			
				417	1	9
Collings, Woodcuts (previous year)				2	5	0
Stationery (Wodderspoon)	11	7	6			
(Odell and Ives)	1	1	6			
Ditto	3	8	6			
				15	17	6
Morbid Growths Committee				5	0	0
Secretariat and Treasury:						
Assistance to Hon. Secs. (Mr. Wheatley)	7	7	0			
Posting Ledgers (Mr. McDermott)	1	10	0			
Collecting Subscriptions, &c.	15	1	6			
Petty Cash (Hon. Secretaries)	4	4	10			
Ditto (Mr. Wheatley)	7	4	8			
				35	8	0
Committee for investigations on Pyæmia:						
*(Government grant £300.)						
Microscopes (Mr. McCarthy)	7	3	6			
Draughtsmen (ditto)	5	0	0			
Quarter of residue (ditto)	70	0	0			
Draughtsman (Dr. Greenfield)	7	0	0			
Quarter of residue (ditto)	70	0	0			
Ditto (Mr. M. Beck)	70	0	0			
Ditto (Dr. Ralfe)	69	8	6			
				298	12	0
Balance in hand				33	8	10
				£920	18	1

Audited and compared with the Vouchers and found correct.

* £1 8s. of the expenditure of this fund appeared in the last balance-sheet.

Auditors { HENRY A. LEDIARD, M.D.
W. J. WALSHAM.

LIST OF SPECIMENS AND REPORTS

BROUGHT BEFORE THE SOCIETY DURING THE SESSION 1879-80.

I.—DISEASES, ETC., OF THE NERVOUS SYSTEM.

PAGE

1. Ramifying cyst in the brain, associated with a congenital malformation of some of the cerebral vessels
By WILLIAM EWART, M.B. 1
2. Spinal cord from a case of tetanus following ovariotomy
By VINCENT HARRIS, M.D., and ALBAN DORAN 7
3. On degeneration and regeneration of the axis-cylinder in non-traumatic nerve-lesions, with special reference to gangrene of the cutaneous nerves
By GEORGE HOGGAN, M.B. 12
4. A case of supposed rupture of most of the roots of the brachial plexus By JONATHAN HUTCHINSON, F.R.C.S. 27

II.—DISEASES, ETC., OF ORGANS OF RESPIRATION.

1. Case of membranous inflammation of the larynx, trachea, and bronchial tubes in an adult
By P. H. PYE-SMITH, M.D. 30
2. Cases of necrosis of the cartilages of the larynx in smallpox and enteric fever By FREDERIC S. EVE 33
3. Ulceration of the larynx due to congenital syphilis
By W. ALLEN STURGE, M.D. 39

PAGE

4. Two cases of congenital syphilis of the larynx
By Felix Semon, M.D. 41

5. Laryngitis in congenital syphilis
By Thomas Barlow, M.D. 46

6. Atelectasis of lungs with emphysematous cyst; congenital heart disease By Thomas Barlow, M.D. 48

7. Two cases of complete excavation of one lung, with death in one case from exhaustion; in the other from rupture of an aneurysm of the pulmonary artery
By Samuel West, M.B. 50

8. Blood-casts of the bronchi By Samuel West, M.B. 53

9. Epithelioma of the larynx, leading to secondary deposits in the neighbouring lymphatic glands, and to secondary chondritis and perichondritis of the left wing of the thyroid cartilage (Card specimen)
Exhibited by Felix Semon, M.D. 55

10. Old syphilitic scars in the larynx, trachea, and bronchi; stricture of the bronchi, leading to chronic disease in the lungs (Card specimen)
Exhibited by Wm. Ewart, M.B. 57

III. DISEASES, ETC., OF THE ORGANS OF CIRCULATION.

1. Case of malformation of the heart, with transposition of the aorta and pulmonary artery
By David B. Lees, M.A., M.D. 58

2. Two cases of congenital malformation of the heart [With Plate I] By Stephen Mackenzie, M.D. 63

3. A case of suppurative myocarditis with scarlatinal nephritis By James F. Goodhart, M.D. 70

4. A case of fatty degeneration of the heart after hæmorrhage in typhoid fever
By James F. Goodhart, M.D. 71

PAGE

5. Case of rupture of right ventricle of the heart [With Plate II]
By Dr. PEACOCK for Mr. THOMAS FISHER (of Great Eccleston, Lancashire) 72

6. Incompetency of the aortic valves produced by a strain; subsequent endocarditis and formation of a polypoid body hanging into the left ventricle, and causing ulceration of the ventricular septum and erosion of the adjoining cusp of the valve
By EDWARD HEADLAM GREENHOW, M.D. 73

7. Fibroid patch of interventricular septum of heart; blood-clots in brachial, hepatic, and superior mesenteric arteries; gangrene of portion of jejunum
By HENRY T. BUTLIN 76

8. Aortic, mitral and tricuspid stenosis; firm organised clot in left auricle, leaving only a narrow channel for the blood By J. PEARSON IRVINE, M.D. 79

9. Aneurysm of aorta opening into right auricle
By NORMAN MOORE, M.D. 82

10. Extra-pericardial aneurysm of the ascending aorta, with an unusually small orifice; leakage into the pericardium without any visible perforation
By WILLIAM EWART, M.B. 82

11. Aneurysm of the abdominal aorta and external iliac artery opening into the vena cava
By P. H. PYE-SMITH, M.D. 85

12. A case of so-called aneurysm by anastomosis of the ear [With Plate III and Plate XVIII, fig. 3]
By FREDERIC S. EVE 88

13. Malformation of the heart; stenosis of the pulmonary artery; aorta communicating with both ventricles (Card specimen)
Exhibited by T. B. PEACOCK, M.D., and T. BARLOW, M.D. 91

14. Malformatiou of the heart; absence of the pulmonary artery (Card specimen)
Exhibited by T. B. PEACOCK, M.D., and W. CASH REED, M.B. 91

PAGE

15. Congenital malformation of the heart in a girl, æt. 13; transposition of the pulmonary artery and superior cava; incomplete septum ventriculorum; patent foramen ovale; constriction of pulmonary artery and mitral orifice. Aorta arises from the left ventricle, but receives blood mainly from the right. Ductus arteriosus is closed (Card specimen)
Exhibited by H. Radcliffe Crocker, M.D. 92
16. Complete occlusion of aortic orifice by a fibrinous and calcareous mass; perforation of one of the aortic valves (Card specimen)
Exhibited by H. Radcliffe Crocker, M.D. 93
17. Fibro-cretaceous ring surrounding the heart in the situation of the auriculo-ventricular sulcus (Card specimen) Exhibited by W. Ewart, M.B. 94
18. Intra-cardiac aneurysm at the root of the aorta, opening into the right auricle (Card specimen)
Exhibited by W. Ewart, M.B. 95
19. Aneurysm of mitral valve (two examples) (Card specimens) Exhibited by Norman Moore, M.D. 96
20. Intra-pericardial aneurysm of the aorta, opening into the left auricle (Card specimen)
Exhibited by Wm. Ewart, M.B. 96
21. Aneurysm and rupture of aortic valve (Card specimen)
Exhibited by H. G. Orlebar, M.D. 97
22. Aneurysm of aortic arch rupturing into trachea (Card specimen) Exhibited by H. G. Orlebar, M.D. 98
23. Complete occlusion of the right division of the pulmonary artery, the result of disease; atheroma of the pulmonary artery (Card specimen)
Exhibited by Wm. Ewart, M.B. 99
24. Persistent left superior vena cava (Card specimen)
Exhibited by W. J. Walsham 99

IV. DISEASES, ETC., OF THE ORGANS OF DIGESTION.

1. Gumma of tongue in hereditary syphilis (living specimen)
By Thomas Barlow, M.D. 101

PAGE

2. Epithelioma of the pharynx involving the larynx, trachea, and œsophagus By T. GILBART SMITH, M.D. 102
3. Ulcerations of stomach and duodenum By NORMAN MOORE, M.D. 106
4. Volvulus of the ileum By W. HARRISON CRIPPS 111
5. Imperforate rectum By W. HARRISON CRIPPS 112
6. Cancer of the sigmoid flexure; gangrene of the bowel (transverse and descending colon); peritonitis By JAMES F. GOODHART, M.D. 113
7. Congenital occlusion of the duodenum above the common bile-duct By JAMES F. GOODHART, M.D., for GEORGE EASTES, M.B. 114
8. A case of acute atrophy of the liver By SAMUEL WEST, M.D. 116
9. Cirrhosis of the liver in a child [With Plate IV] By FREDERICK TAYLOR, M.D. 119
10. Primary carcinoma of the liver By P. H. PYE-SMITH, M.D. 125
11. Primary diffuse malignant growth in the liver, in which the characters of sarcoma and carcinoma were apparently combined; rapid evolution of the disease, which was of great extent, but limited to the liver By SIDNEY COUPLAND, M.D. 130

Report. By J. F. GOODHART and H. T. BUTLIN, for *Committee on Morbid Growths* 135

12. Primary cancer (epithelioma) of the gall-bladder By SIDNEY COUPLAND, M.D. 136
13. Case of cancer (probably primary) of the gall-bladder By NORMAN MOORE, M.D. 138
14. Description of a large gall-stone passed per anum, with remarks on the structure and mode of formation of biliary calculi By WILLIAM M. ORD, M.D. 139
15. Œsophagus and stomach from a case of acute carbolic acid poisoning (Card specimen) Exhibited by ROBERT SMITH, M.D. 143
16. Acute fatty changes occurring in an enlarged liver (acute hepatitis?) (Card specimen) Exhibited by C. H. RALFE, M.D. 144

PAGE

17. Volvulus of small intestine due to a complete Meckel's diverticulum (Card specimen)
Exhibited by S. COUPLAND, M.D. 144
18. Carcinoma (medullary) of duodenum, just beyond pylorus, occluding and invading hepatic ducts (Card specimen) Exhibited by S. COUPLAND, M.D. 145
19. Hernia of ileum through a rent in the great omentum (Card specimen) Exhibited by S. COUPLAND, M.D. 146
20. Hernia of some of the abdominal viscera into the left pleura, probably congenital (Card specimen)
Exhibited by WM. EWART, M.B. 146
21. Hernia into the vaginal process of peritoneum and undescended testicle (Card specimen)
Exhibited by FREDERIC S. EVE 147
22. Patent vaginal process of peritoneum (Card specimen)
Exhibited by FREDERIC S. EVE 147

V. DISEASES, ETC., OF THE GENITO-URINARY ORGANS.

1. The histology of granular kidney [With Plates V and VI] By ROBERT SAUNDBY, M.D. 148
2. Granular contracted kidney [With Plate VII]
By W. S. GREENFIELD, M.D. 157
3. Case of cystic degeneration of the kidneys
By FREDERIC S. EVE 164
4. Cystic kidney removed from a child
By W. H. DAY, M.D., and
J. KNOWSLEY THORNTON, M.B., C.M. 167
5. Three cases of sarcomatous growths invading both kidneys from without By JOHN ABERCROMBIE, M.D. 168
6. Papilloma of the Fallopian tube associated with ascites and pleuritic effusion. [With Plate VIII]
By ALBAN DORAN 174
7. Ovarian cyst which had ruptured repeatedly during a period of nine years prior to its removal
By W. A. MEREDITH, M.B. 180

PAGE

8. Mixed calculus of cystine and oxalate of lime
By SAMUEL G. SHATTOCK 182
9. Calculus removed by supra-pubic lithotomy
By PAUL SWAIN 184
10. Calculus from the kidney By WILLIAM M. ORD, M.D. 185
11. Congenital malposition and cystic degeneration of the left kidney (Card specimen)
Exhibited by WILLIAM EWART, M.B. 187
12. Cystic degeneration of the left kidney and ureter during intra-uterine life (Card specimen)
Exhibited by WILLIAM EWART, M.B. 187
13. Two complete ureters on either side of the body (Card specimen) Exhibited by WILLIAM EWART, M.B. 188
14. Horseshoe kidney (Card specimen)
Exhibited by NORMAN MOORE, M.D. 188
15. Kidneys united by a fibrous band (Card specimen)
Exhibited by H. A. LEDIARD, M.D. 189
16. Branched renal calculus (Card specimen)
Exhibited by C. H. RALFE, M.D. 189
17. Mucous membrane of the bladder showing miliary tubercles; absence of tubercle in other parts of the body (Card specimen)
Exhibited by WILLIAM EWART, M.B. 190
18. Syphilitic disease of testicle (Card specimen)
Exhibited by FREDERIC S. EVE 190
19. Persistent communication between the rectum and genito-urinary track in a new-born male child (Card specimen) Exhibited by SAMUEL G. SHATTOCK 191
20. Uterus septus cum vaginâ duplici (Card specimen)
Exhibited by W. J. WALSHAM 191
21. Dilatation of Fallopian tubes (Card specimen)
Exhibited by ALBAN DORAN 192
22. An alternating calculus, consisting of layers of lithates and lithic acid, finally encrusted by oxalate of lime (Card specimen) Exhibited by J. HUTCHINSON 192
23. Gumma of testis from a boy the subject of inherited syphilis (Card specimen; a coloured sketch only)
Exhibited by J. HUTCHINSON 192

VI. DISEASES, ETC., OF THE OSSEOUS SYSTEM.

PAGE

1. Cases of osseous and articular lesions in tabes dorsalis By Thomas Buzzard, M.D. 193
2. Malformation of arm By Allen Sturge, M.D. 208
3. Bony outgrowth of the great trochanter, complicating a case of impacted fracture of the neck of the femur, and simulating a dorsal dislocation of the hip By Henry Morris, M.A., M.B. 214
4. Specimen of a recent dislocation of the first phalanx of the thumb forwards By Frederic S. Eve 216
5. Multiple sarcomata of cranial bones By John Abercrombie, M.D. 216

   Report. By Marcus Beck and R. J. Godlee for *Committee on Morbid Growths* 221
6. Ossifying chondro-sarcoma of both femora, with secondary deposits of a similar new growth in the lungs, in the bronchial, and in some lymphatic glands [With Plate IX] By Robert William Parker 223
7. Bone lesions in congenital syphilis [With Plate X] By Robert William Parker 226
8. Disease of growing ends of shafts of long bones in congenital syphilis By Thomas Barlow, M.D. 229
9. Case of disease of the bones in a fœtus, presumably syphilitic By Frederic S. Eve. 233
10. Cranio-tabes associated with congenital syphilitic disease of parietal bone By Thomas Barlow, M.D. 236
11. Two cases of disease of the skull-cap By Norman Moore, M.D. 238
12. Dislocation of the external semilunar fibro-cartilage of the knee-joint [With Plate XI] By Rickman J. Godlee 240
13. Diseased jaw-bone from case of cancrum oris By W. Harrison Cripps, F.R.C.S. 242
14. Ostitis (with ulceration) of skull; gummatous infiltration of dura mater; cerebral endarteritis; gummata in spleen and lung (?); fibroid testes. From a case of syphilis (Card specimen) Exhibited by S. Coupland, M.D. 243

PAGE

15. Cranial bosses (Card specimen)
Exhibited by J. Abercrombie, M.D. 244

16. A united fracture of right ulna from a case of locomotor ataxy (Card specimen)
Exhibited by W. B. Hadden, M.D. 245

17. Lower extremity of a right femur from a case of locomotor ataxy (Card specimen)
Exhibited by W. B. Hadden, M.D. 245

18. A dislocation upwards of the acromial end of clavicle with fracture of clavicle (Card specimen)
Exhibited by Frederic S. Eve 245

19. Ostitis of right os calcis or combined periostitis and myelitis (scrofulous) (Card specimen)
Exhibited by Walter Rivington 246

20. Caries of spine producing aortic deformity and probable obstruction (Card specimen)
Exhibited by Arthur E. Barker 246

21. Excision of knee-joint, bone twelve years afterwards (Card specimen)
Exhibited by Henry A. Lediard, M.D. 247

22. Dislocation of the hip-joint from disease (Card specimen) Exhibited by Henry A. Lediard, M.D. 247

23. Dislocation of the hip-joint from disease (Card specimen) Exhibited by Henry A. Lediard, M.D. 248

24. Ostitis of the ulna in connection with inherited syphilis (Card specimen)
Exhibited by Jonathan Hutchinson 248

25. Living subject showing dwarfing of the tibia following detachment of its lower epiphysis. (Card specimen)
Exhibited by Jonathan Hutchinson 249

26. Large recurrent enchondroma of the upper jaw (Card specimen; two photographs and tumour)
Exhibited by Jonathan Hutchinson for J. H. Keeling, M.D. (of Sheffield) 250

27. Chronic osteitis in connection with inherited syphilis, (Card specimen; part of a fibula which had been excised) Exhibited by Jonathan Hutchinson 250

VII. DISEASES, ETC., OF ORGANS OF SPECIAL SENSE.

PAGE

1. Optic nerve from a case of optic neuritis with good sight (Card specimen.) [With Plate XII]
Exhibited by E. NETTLESHIP 252
2. Eyeball degenerated and containing much cholesterin, from a child (Card specimen)
Exhibited by E. NETTLESHIP (for the President) 253
3. Spontaneous intra-ocular hæmorrhage in an infant (Card specimen) Exhibited by E. NETTLESHIP 253
4. Atrophy of optic nerve and retina, and other changes in an eye lost by erysipelas spreading to the orbit (Card specimen; microscopical specimens)
Exhibited by E. NETTLESHIP 254

VIII. MORBID GROWTHS.

1. Tumour of face, plexiform sarcoma (?). [With Plates XIII and XIV] By JEREMIAH MCCARTHY 256
2. Pulsating tumours of the left parietal bone, associated with other similar tumours of the right clavicle and both femora, and with great hypertrophy of the heart [With Plates XV and XVI]
By HENRY MORRIS, M.B. 259
Report. By M. BECK, HENRY T. BUTLIN, and RICKMAN J. GODLEE, for *Committee on Morbid Growths* 270
3. Recurrent mammary tumour; spindle-celled sarcoma (?); the sixth removal By JOHN GAY 272
4. Recurrent tumour of the breast removed seven years after first operation By T. W. NUNN 276
Report. By MARCUS BECK and RICKMAN J. GODLEE for *Committee on Morbid Growths* 276
5. Myeloid sarcomata of lower jaw and rib; mollities ossium [With Plate XVII] By HENRY T. BUTLIN 277
6. Lympho-sarcoma (lymphadenoma) of the mediastinum involving the pericardium By FREDERIC S. EVE 279
7. Lymphadenoma of the lymphatic glands, liver, spleen, lungs, and pleuræ By FREDERICK TAYLOR, M.D. 282

PAGE

8. Cartilaginous tumour of arm [With Plate XVIII, figs. 1 and 2]
By W. Harrison Cripps 287

9. Fatty tumour of abdomen, showing fibrous and osseous changes By J. Dreschfeld, M.D. 287

10. Diffuse (?) sarcoma of liver, probably congenital
By Robert William Parker 290

11. On some of the appearances observed in a case of cancer of the liver [With Plate XX]
By George Thin, M.D. 293

12. On the histology of a cancerous tumour of the mamma [With Plate XIX] By George Thin, M.D. 294

13. Epithelioma of the penis By T. W. Nunn 298

14. Melanosis of the little finger By T. W. Nunn 299

15. Myxo-sarcoma of the spermatic cord removed from a child thirteen months old [With Plate XXI, fig. 2]
By W. J. Walsham 299

16. Tumour of the spermatic cord from a child four years of age [With Plate XXI, figs. 1 and 3; Plate XXII, figs. 3 and 4] By W. J. Walsham 303

17. Horny growth from the lower eyelid of an old woman [With Plate XXII, figs. 1 and 2] By W. J. Walsham 306

18. Dermoid tumour from the rectum [With Plate XXIII]
By Heinrich Port, M.D. 307

19. Lymphoma of mediastinum pressing upon the right bronchus and invading the lung (Card specimen)
Exhibited by Henry A. Lediard, M.D. 309

20. Myxo-sarcoma of the head of the tibia (Card specimen)
Exhibited by W. J. Walsham for Mr. Anderson 309

21. Pedunculated fatty tumour, which grew over the anterior superior spine of the ilium (Card specimen)
Exhibited by W. J. Walsham 310

22. Myxo-fibroma of epididymis and cord (Card specimen)
Exhibited by James F. Goodhart for Mr. John Gay 310

23. Tumour found loose in abdominal cavity (Card specimen) Exhibited by Frederic S. Eve 311

24. Series of Fifteen Drawings of Cancer (Card specimens)
Exhibited by Mr. Hulke

(1.) Scirrhus of female breast 311

PAGE
(2.) Cancer of female breast 311
(3.) Scirrhus of female breasts 311
(4.) Scirrhus of female breast 312
(5.) Scirrhus of breast 312
(6.) Drawing of cancer of lower lip 312
(7.) Cancer of lower lip, and mole on cheek 312
(8.) Cancer of lower lip 312
(9.) Cancer beginning in lower lip 313
(10.) Cancer of lower lip and ichthyosis of tongue 313
(11.) Cancer of womb, invading vagina and rectum; colotomy 313
(12.) Cancer of anus 313
(13.) Chimney-sweep's cancer 313
(14.) Chimney-sweep's cancer 314
(15.) Cancer of penis and inguinal glands 314

IX.—DISEASES OF THE SKIN.

1. The histology and pathology of morphœa and its relation to scleroderma adultorum
By H. Radcliffe Crocker, M.D. 315
2. A case of scleroderma adultorum, illustrating the circumscribed and the diffuse forms of the malady
By Dyce Duckworth, M.D. 322
3. Case of sclerema By W. E. Steavenson, M.B., introduced by Dr. Barlow 326
4. Xanthelasma multiplex. Disappearance of the patches
By J. Wickham Legg. 329
5. A case of varicella gangrænosa
By John Abercrombie, M.D. 333
6. A case of lichen ruber (?) By W. Morrant Baker 334
7. Melanosis of finger By Rickman J. Godlee 336
8. On the histology of elephantiasis arabum and its relations to normal connective tissue [With Plate XX, figs. 1—4] By George Thin, M.D. 337

PAGE

9. On the fungus of tinea imbricata (Manson)
By GEORGE THIN, M.D. 339
10. Case of molluscum contagiosum. Illustrated by a drawing and microscopical sections By JAMES STARTIN 341
11. On a peculiar papulo-vesicular eruption (lupus lymphaticus) [With Plates XXIV and XXV]
By JONATHAN HUTCHINSON 342
Report of microscopical appearances By A. SANGSTER, M.B. 346
12. A pigmented mole, with elephantoid hypertrophy of the mons and labium; growth after excision and second operation (Card specimen)
Exhibited by JONATHAN HUTCHINSON 348
13. Photograph of a case of molluscum fibrosum, one of the tumours of very large size and pendulous (Card specimen) Exhibited by JONATHAN HUTCHINSON 349
14. A peculiar form of mole, "the cock's-comb mole" (Card specimen) Exhibited by JONATHAN HUTCHINSON 349

XI.—DISEASES, ETC., OF SUPRA-RENAL CAPSULES.

1. Case of disease of supra-renal capsules
By NORMAN MOORE, M.D. 350
2. Fibrous and calcareous changes in both supra-renal capsules, perhaps of syphilitic origin (Card specimen)
Exhibited by WM. EWART, M.D. 352

XII.—MISCELLANEOUS SPECIMENS.

1. On a peculiar, circular, wandering rash on the tongue
By ARTHUR E. J. BARKER 353
2. Enlargement of the temporal and masseter muscles on both sides By J. WICKHAM LEGG 361
3. On some appearances, probably of parasites, in the voluntary muscles in cases of enteric fever
By GEORGE BUCHANAN, M.D. 366
4. Congenital talipes varus By ROBERT WILLIAM PARKER 370

PAGE

5. An Achilles tendon, which had re-united, with the formation of one and a half inch of new tendon, after subcutaneous division four years previous to death
By WILLIAM ADAMS 372
6. Sequel to a case of syphilitic gummata recorded in the 'Transactions' of the Society (vol. xx, p. 309)
By WM. ADAMS 374
7. Two cases of late hereditary syphilis
By SIDNEY COUPLAND, M.D. 376
8. Micro-photographs of the blood in yellow fever
By W. SQUIRE, M.D. 380
9. Fatty metamorphosis of the muscles of the leg, with talipes equino-varus, from long-standing paralysis (Card specimen) Exhibited by FREDERIC S. EVE 381
10. Dissection of a leg atrophied from infantile paralysis and amputated. From a patient, æt. 20 (Card specimen) Exhibited by ALBAN DORAN 381
11. Recent division of the tendo Achillis (Card specimen)
Exhibited by SAMUEL G. SHATTOCK 382
12. The crown of a milk tooth which was exfoliated in the case of a syphilitic infant (Card specimen)
Exhibited by JONATHAN HUTCHINSON 382
13. Chronic enlargement of a bursa patellæ (Card specimen)
Exhibited by JONATHAN HUTCHINSON 383
14. Portrait of an infant with a pedunculated occipital meningocele; also the occipital bone removed after death, showing the opening in the bone (Card specimen, drawings only) Exhibited by the PRESIDENT for Dr. RODDICK (of Montreal) 383
15. Gummata in the lung and testis (Card specimen; drawings only) Specimens obtained by Mr. Macarthy.
Exhibited by JONATHAN HUTCHINSON 384
16. Cystine calculus (Card specimen)
By W. M. ORD, M.D. 384

XIII.—SPECIMENS FROM THE LOWER ANIMALS.

PAGE

1. Enterolith—an oriental bezoar
By WILLIAM M. ORD, M.D. 385
2. Colon of a sheep, showing colotomy performed by a parrot By JOHN WOOD, for HARRY A. DE LAUTOUR 386

APPENDIX.

Report of the Committee on Morbid Growths on Mr. Gay's specimen of recurrent mammary tumour (See page 272) 389

REPORTS OF THE COMMITTEE ON MORBID GROWTHS.

PAGE

1. On S. Coupland's specimen of primary sarcoma of the liver (J. F. Goodhart and H. T. Butlin) . . 135

2. On John Abercrombie's case of tumours of the vault of the skull (Marcus Beck, and R. J. Godlee) . 221

3. On H. Morris's specimen of pulsating tumour of cranium (M. Beck, H. T. Butlin, and R. J. Godlee) . 270

4. On T. W. Nunn's case of recurrent tumours of the breast (M. Beck and R. J. Godlee) . . . 276

5. On John Gay's specimen of recurrent mammary tumour (H. G. Howse and Fred. Taylor) . . 389

LIST OF PLATES.

		PAGE
I.	Two cases of Congenital Malformation of the Heart (Page 63) . . . . . Fig. 1, Case 1. Contraction of Pulmonary Artery Fig. 2. Case 2. Supernumerary Ventricle, &c. (STEPHEN MACKENZIE) . .	62
II.	Case of Rupture of the Right Ventricle. (T. B. PEACOCK). (Page 72.) . . .	72
III.	Pinna of the Right Ear affected with (so-called) Aneurysm by Anastomosis. (Page 88.) (F. S. EVE)	88
IV.	Case of Cirrhosis of the Liver of a Child. (Page 119.) (F. TAYLOR)	120
V.	The Histology of Granular Kidney. (Page 148.) (R. SAUNDBY.) Figs. 1 to 9 . . .	148
VI.	Ditto. Figs. 10 to 13. . . .	148
VII.	Changes in the Granular Contracted Kidney and allied conditions. (Page 157.) (W. S. GREENFIELD)	158
VIII.	Case of Papilloma of the Fallopian Tube. (Page 174.) . . . . . Figs. 1 to 4. Microscopical appearances of different portions of the growth . . Fig. 5. The Fallopian Tube laid open to show the growth. (ALBAN DORAN) . .	174
IX.	Case of Ossifying Chondro-sarcoma. (Page 223.) (R. W. PARKER)	224
X.	Cases of Syphilitic Bone Lesions. (Page 226.) Figs. 1 and 2, from Case 2. Julia B—, æt. 13 years Figs. 3, 4, and 5, from Case 1. (R. W. PARKER)	226
XI.	Case of Dislocation of External Semilunar Cartilage. (R. J. GODLEE)	240
XII.	Case of Optic Neuritis with good Sight. (Page 252.) (E. NETTLESHIP)	252
XIII.	Tumour of the Face. (Page 256.) A Front View of the Tumour as it appeared during life. (J. MACCARTHY)	256
XIV.	Microscopical Structure of the Tumour of the Face represented in Plate XIII. (J. MACCARTHY) .	256

PAGE

XV. Case of Pulsating Cranial Tumour. (Page 260.) The upper figure is taken from a Photograph, and shows the appearance of the tumour four years and two months before death . . The lower figure represents a Vertical Section through the centre of the cranial tumour, scalp, skull, and dura mater. (HENRY MORRIS) 260

XVI. Microscopic Structure of Pulsating Cranial Tumour represented in Plate XV. (R. J. GODLEE, for the *Committee on Morbid Growths*) . . 270

XVII. Myeloid Tumours associated with Mollities Ossium. (Page 277.) (H. T. BUTLIN) . . 279

XVIII. Figs. 1 and 2. Microscopical Structure of Cartilaginous Tumour of Arm. (Page 287.) (W. HARRISON CRIPPS) . . . Fig. 3. Section of the Injected Pinna in the case of so-called Aneurysm by Anastomosis figured in Plate III. (Page 88.) (FREDERIC S. EVE) 286

XIX. Histology of a Cancerous Tumour of the Mamma. (GEORGE THIN) 294

XX. Figs. 1, 2, 3, and 4. The Pathological Histology of Elephantiasis. (Page 337.) (G. THIN) Figs. 5, 6, 7, 8, and 9. Appearances observed in a Case of Cancer of the Liver. (Page 293.) (G. THIN.) . . . 294

XXI. Figs. 1 and 3. Tumour of Spermatic Cord. (Page 303.) (See also Plate XXII, Figs. 3 and 4.) . . . . Fig. 2. Myxo-sarcoma of Spermatic Cord. (Page 299.) (W. J. WALSHAM) . . 302

XXII. Figs. 1 and 2. Horny Growth from the Eyelid. (Page 306) . . . Figs. 3 and 4. Tumour of the Spermatic Cord. (Page 303.) (See also Plate XXI, Figs. 1 and 3.) (W. J. WALSHAM) . . 302

XXIII. Case of Dermoid Tumour from the Rectum. (Page 307.) (H. PORT) . . . 308

XXIV. Case of Papulo-vesicular Eruption on Skin, or *Lupus lymphaticus*. (JONATHAN HUTCHINSON) . 342

XXV. Microscopical Structure of Mr. Hutchinson's Case of Papulo-vesicular Growth on Chin. (Page 342.) (A. SANGSTER) . . 346

WOODCUTS.

PAGE

1. Calculus removed by supra-pubic lithotomy (Paul Swain) 184

2. Calculus from the kidney. Fig. 1. Section. Fig. 2. Outer surface. Fig. 3. Outer surface of nucleus, showing erosions (W. M. Ord) 185

3. Myxo-sarcoma of the spermatic cord from a child (W. J. Walsham) 300

4-5. Circular wandering rash on the tongue, as seen at different times (A. E. J. Barker) . . . 355-6

REPORT.

SESSION 1879-80.

I. DISEASES, ETC., OF THE NERVOUS SYSTEM.

1. *Ramifying cyst in the brain, associated with a congenital malformation of some of the cerebral vessels.*

By WILLIAM EWART, M.B.

THE patient from whom the specimen was derived, a man, æt. 30, was admitted into St. George's Hospital, under Dr. Whipham's care, in July, 1878. His previous health appears to have been uninterruptedly good, but at the close of the year 1876 he was seized with severe frontal headache and occasional vomiting. A similar attack, complicated with diarrhœa, occurred in August, 1877. In January, 1878, the symptoms returned, associated with constipation, and early in February, signs of mental derangement were noted for the first time; the patient would tear his sheets, leave his bed and wander about, talk incoherently, &c., but these paroxysms were temporary, and passed away without leaving any trace of their occurrence. The cephalalgia and vomiting persisted till the middle of March. No note was made of the condition of the mind during the interval that preceded the patient's admission. When admitted into the hospital he was found to be suffering, in addition to headache and vomiting, from attacks of numbness in both hands; there was no other evidence pointing to loss of nerve power. The pulse and respiration were normal and the general health good, but the mind wandered occasionally. Slight turgidity of the retinal veins was detected by the ophthalmoscope. Rapid deterioration occurred

during the month of July, and the intellect became greatly obscured. The patient grew very restless, and on August 2nd had to be removed from the general ward. On the 17th he was readmitted, being quieter in his manner. Occasional vomiting was again noted on August 20th; he became unconscious and comatose, and twitchings of the mouth and face were observed. Two days later he had so far improved as to recognise his wife and converse with her. Consciousness was in abeyance on the 24th, but returned on the 26th. The mind became finally obscured on the 29th, drowsiness supervened, and on September 3rd, after a slight convulsive fit, he died.

The brain presented externally no striking abnormality. There was a slight excess of fluid under the arachnoid, but the membranes appeared natural and free from congestion. An incision made into the right hemisphere brought into view a delicate cyst-membrane, which was thought at the time to be a hydatid, but the specimen appearing to possess more than ordinary interest was laid into strong spirit and preserved for a complete examination by the present reporter. This examination was not made until the brain had become completely hardened by the alcohol. The consistence of the brain matter was described as normal at the time of the autopsy, excepting in the neighbourhood of the cyst, where it seemed rather soft. The following appearances were found on subsequent inspection. The membranes were normal at the convexity of the brain. The arachnoid was much thickened over the interpeduncular space; the right fissure of Sylvius was closed by strong adhesions, and a patch of tough membrane, slightly raised above the normal surface, covered the posterior third of the olfactory region of the right frontal lobe. A smaller patch of thickened arachnoid was seen at the base of the left frontal lobe close to the interpeduncular space. Both these patches were found to constitute part of the boundary of the abnormal cavity, to be further described.

Nothing unusual was at first noticed in connection with the vessels at the base, and the posterior segment of the circle of Willis was seen to be quite natural, but the anterior cerebral arteries and their communicating branch were entirely hidden from view. In searching for these vessels one of the toughened patches of arachnoid was incised, and from under its edge there bulged forward a delicate membrane, which lay closely packed in a smooth-walled,

shallow, depression of the brain surface. This cyst was empty, and folded upon itself; when unravelled it was found to extend backwards into the substance of the brain by means of a slender tubular peduncle, contained within a narrow smooth-walled canal. A similar formation was discovered at the base of the other frontal lobe; the interpeduncular space also concealed cystic expansions. It was noticed that when traction was made upon one of the terminal cysts, a slight degree of movement was set up at a distance in other cyst membranes, deemed at first sight to be thoroughly independent. In reality, there existed but one cyst possessing many branches, which ramified by means of tunnels and foramina through a portion of the brain, here and there expanding into membranous bags. The cystic growths had taken place mainly along the right Sylvian fissure, in the depths of which the brain was excavated. Posteriorly the disease reached as far as a vertical plane drawn across the posterior genu of the corpus callosum, whilst at the base it occupied the interpeduncular space and the posterior extremity of both frontal lobes, chiefly the right. The lateral ventricle was not opened up by the excavation, and the grey central ganglia were undisturbed, but the white substance intervening between the ventricle and the lateral surface of the brain, and the cortical matter of the Sylvian convolutions, and of the gyri operti were extensively destroyed.

The ramifications of the cyst were contained within a continuous cavity formed at the expense of the brain substance and moulded for their reception. Numerous septa and pillars, of varying thickness, but all very tough, subdivided the brain cavity into irregular chambers, which were tightly packed with membranous pouches. Some of the latter showed a tendency to the formation of secondary outgrowths or digitations. The surface of the cavity was uneven, but perfectly smooth; its lining membrane was comparatively thick and tough, and presented much analogy with the thickened lining of the lateral ventricles in the same brain; it could not be peeled off as a distinct elastic layer, but admitted of easy removal in the shape of shreds and flakes from the subjacent brain tissue. The walls were here and there marked by slightly projecting pillars; these, as well as the columns traversing the cavity, consisted of thick-walled vascular branches, a fact which gave the first clue to the close inter-dependence of the vessels and of the ramifying cyst.

The anterior cerebral arteries took their origin at a slightly deeper level than normal, especially on the right side; their size was rather in excess of the average. The left artery, instead of running straight forwards, traversed the middle line so as to lie within the right frontal lobe. In this situation an anterior communication was given off, which joined, at a considerable depth, the short but stout right anterior cerebral. Both vessels were at this stage invested in a thick membrane, and formed part of the wall of the abnormal cavity. Their general aspect suggested that they had been abnormally developed; the absence of symmetry in their course and the unevenness of their calibre pointed directly to this conclusion. About half an inch in front of the communicating branch a second communication took place between the two vessels, and by this means an arterial ring was produced, in the centre of which one of the saccular membranous expansions was stowed away. The left anterior cerebral ended in a pointed extremity, just beyond the second communicating branch. The right anterior cerebral, continuing its course alone, assumed a vertical direction parallel with the bend of the corpus callosum, and, after ascending for a distance of rather more than half an inch, it ended in a clumsy knob, from which arose several branches clothed with shreddy membranes. The membranous investment was not, however, continued along the two largest divisions, which exactly resembled the normal terminations of the anterior cerebral arteries, and ran backwards to be distributed to the pia mater behind the corpus callosum.

The left middle cerebral was in every respect normal. On the right side the corresponding vessel was irregular in its distribution, larger than normal, and, at its origin, more deeply situated. Its course lay nearly entirely within the cavity previously described, the accidents of which were mainly due to the peculiarities of the arterial distribution. The branches were more numerous and larger than those of a healthy Sylvian artery, and their calibre was irregular; they traversed the cavity in every direction.

Under the microscope the abnormal vessels were found to be possessed of a greatly thickened intima; their lumen was nearly obliterated by an irregular growth of flat cells, undergoing at the periphery, near the fenestrated membrane, a distinct fibrillation. The general outline of the vessels was uneven, and the transverse section often not circular.

The tough membrane investing the vessels and lining the cavities consisted of a thick layer of minute round cells, showing but faint indications of fibrillation, and, close to the surface, of a thin layer of loosely arranged round cells with granular contents, not exceeding red-blood cells in diameter. Owing to the prolonged maceration in spirit which had preceded the microscopical examination, it could not be determined with certainty whether the free surface was formed by flattened cells or by a simple condensation of the structureless matrix. The appearances were in favour of the latter view.

The cyst was not dragged out completely from what might be termed its shell; this would have been impracticable, owing to the small size of some of the passages through which its ramifications were transmitted. In the extensive portion which came into view the membrane was perfectly free, apparently a floating cyst. It was evident however, from the presence within its thickness of capillaries, that it must have posessed some point of attachment. It has already been stated that the cavity within which it ramified did not communicate with the general ventricular space, and there existed no connection between the membrane itself and the choroid plexus.

Under the microscope the membrane presented very unusual features. Viewed under a low power, which allowed a large surface to come within the field, it showed externally a system of minute mammillations contiguous to each other, all of spherical outline and of even size. These were thought to be the result of the wrinkling of a delicate transparent superficial layer, beneath which ramifying capillaries could be seen. Under a high power, the section of the membrane presented a hyaline homogeneous aspect. Numerous capillaries, some of which were very wide, ran a more or less horizontal course in its deeper strata. Close to the surface a double row of very delicate round cells, about as large as red blood-cells, provided with a nucleus, marked the zone, beyond which the capillaries did not extend. A clear zone of little thickness intervened between the cells and the base of the mammillations. The latter resembled hollow domes, and were formed by a membrane closely analogous in its thinness and transparency with the wall of a capillary, but devoid of any structure. No connection could be traced between these formations and the capillaries of the deeper layer.

Remarks.—Putting aside parasitic cysts and cases of encysted

hæmorrhagic or inflammatory products, true cysts in the brain are of extreme rarity. In the few instances met with in reviewing the literature of this subject, the cysts were the result of the accidental separation from the body of the ventricle of a portion of the ventricular space, and its conversion into a closed and independent cavity. Such an interpretation is inapplicable to the present specimen. The ventricles were normal and complete, and the disease was situated at a distance from them. The walls showed some analogy, to the naked eye as well as microscopically, with the ventricular lining, and the cyst-membrane coincided with the type of a choroid plexus inasmuch as it contained capillaries and ramified freely within a cavity. With the latter structure it may have possessed some functional resemblance, but in anatomical features it was entirely different. That the disease was congenital is tolerably evident from the striking abnormality of some of the larger vessels; it would therefore appear most reasonable to look upon the cyst as an integral part of a structural malformation dating from an early stage of development. This view would afford a satisfactory explanation for the extremely rare, if not unique, occurrence of similar conditions. The 'Transactions' of this Society and of the Royal Medical and Chirurgical Society, 'Virchow's Archiv,' the works of Rokitansky and of von Ziemssen, contain no parallel instance. Perhaps the early closure by adhesions of the right fissure of Sylvius may have been the starting-point of the disturbance in development. Even this supposition throws but little light upon the process which led to the singular condition which has been described.

To whatever cause it may have been due, the destruction of a large tract of white matter, involving a considerable loss of cortex, was borne up to the age of twenty-eight without any evil consequences; a similar condition, had it affected the left hemisphere, might have resulted in congenital aphasia. The first onset of the symptoms and their subsequent aggravation leading to death were probably due to a recrudescence in the growth of the membrane and to pressure resulting from increasing secretion.

April 20th, 1880.

---

2. *Spinal cord from a case of tetanus following ovariotomy.*

By VINCENT HARRIS, M.D., and ALBAN DORAN.

ON November 28th, 1879, Dr. Bantock removed a unilocular parovarian cyst from a robust young countrywoman, æt. 24, at the Samaritan Hospital. The pedicle was found to be twisted; it was readily secured by a single ligature. The patient was removed, on the fourth day after the operation, to another ward, and placed in a bed between a window and the fireplace. She progressed very favorably until the morning of the seventh day, when she complained of stiffness of the muscles of mastication on the side of the face which was turned towards the window. Her bed was moved, but undoubted symptoms of trismus and tetanic spasms of the sterno-mastoids and trapezii developed themselves before nightfall. By the next morning the attacks of trismus had become very frequent, and added to them was very severe spasm of the inspiratory muscles, so that during each paroxysm the thorax remained violently expanded; on the other hand, there was little opisthotonos, and the muscles of the abdomen and lower extremities were hardly affected. The patient died asphyxiated at the end of the second day of the tetanic symptoms, and the eighth after ovariotomy. To alleviate her sufferings, chloroform had been freely administered, and within twelve hours of her death she had taken sixty grains of chloral and two drachms of tincture of Indian hemp by enemata, as well as two thirds of a grain of extract of Calabar bean hypodermically. The effects produced by these drugs were very transient.

The case occurred during the intense cold of the past winter, and the *post-mortem* examination was made twelve hours after death in a room the temperature of which was 20° F.; the body had lain there for several hours. The cord was immediately removed, stripped of its membranes, and notched by the scalpel at intervals of two or three inches. It was then placed in Müller's fluid, and afterwards hardened in chromic acid and spirit. In the cervical and upper dorsal region the distinction between the grey and the white matter did not appear so plain as in a normal specimen. The posterior columns and the entire grey matter were here very red. There was deep congestion of the pia mater between the origins of the pos-

terior roots throughout the cord; internally the lumbar region appeared, to the naked eye, quite normal.

About forty sections of the cord were made by Dr. Harris; Williams' apparatus was employed for the purpose. They were examined separately by us, together with sections of normal cord, and on comparing notes we have agreed upon the following conclusions with regard to the appearances observed in these preparations.

In the lumbar region the sections appear almost normal; the connective tissue and axis cylinders of the white columns show distinctly; the ganglion cells of the grey matter are very perfect and surrounded by a wide space. The central canal is very wide in nearly all the sections, and lined with a distinct layer of columnar epithelium, under which are great numbers of nuclei, extending in some specimens for a considerable distance along the grey commissure. In some examples these nuclei are so abundant as to cause the epithelial lining of the canal to bulge prominently into its lumen. Such nuclei are now admitted to be part of the neuroglia, but in healthy cords they are never found in such numbers as in these specimens.[1] This great abundance denotes morbid proliferation, especially when the still more evidently abnormal condition of the cervico-dorsal portion of the grey commissure comes to be considered. A proliferation is simulated when the razor has detached more epithelial cells than actually belong to the portion of the canal included in the section, the cells being torn from an adjacent part of the canal. The tops of these displaced cells are then seen projecting into the lumen of the canal or pressed backwards against the surrounding tissue, so as to mingle with the neuroglia nuclei, from which they can be so clearly distinguished as to prevent all fallacy; moreover, in this case they do not lie in the same focus as the nuclei. In some of the sections dilated vessels can be detected, especially in the anterior columns, close to the median fissure.

The sections taken from the lower cervical, and still more those from the upper dorsal region, are more evidently morbid. They all appear more or less unsymmetrical. In none is there any complete breaking down of grey or white matter; several sections exhibit large patches of transparent homogeneous material, which have not become stained; they are apparently identical with

[1] See Klein and Noble Smith, 'Atlas of Histology,' plate xix, fig. 3.

Clarke's "transparent patches,"[1] Dickinson's "transparent exudation,"[2] and Coats's "area, in which the nerve-fibres and connective tissue do not take on the carmine."[3] An examination of another tetanic cord sent to us by a distinguished surgeon confirms our belief that these transparent patches are the result of partial decomposition. This cord was sent to us in a weak solution of spirit, but the membranes had not been removed nor the cord notched. A vain attempt was made to thoroughly harden this cord; the few sections that could be prepared all presented numerous transparent blotches, which it was found impossible to colour by any medium. Hence, in the ovarian case, the few sections where these patches could be seen were probably from a part of the cord too far from some of the notches made into it to allow perfect permeation of the hardening medium.

The appearance of the grey commissure immediately surrounding the central canal in the upper dorsal region was as follows:—Here morbid changes are more advanced than in the lower part of the cord. The want of symmetry seen in the entire section extends to its central canal, across which there passes a band of homogeneous yellowish material, apparently continuous with the protoplasm of the epithelium, with which it is connected at both ends. It bears three or four nuclei in its broader portion; these are probably derived from the epithelium. The neuroglia-nuclei are, in most of the sections from the upper part of the cord, as abnormally abundant as in the lumbar region; in the specimen here figured they appear less conspicuously numerous. The band across the canal was found in eleven sections, all from the upper dorsal region, and all free from transparent patches. It appears to be exudation thrown off from the epithelium, and probably represents an inflammatory condition, which was commencing to spread down to the lumbar region when the patient died. The vessels in the grey commissure posterior to the canal are much distended in all specimens where the canal is traversed by the band above referred to, and the lymph spaces round them appear wider than usual.

In the cervico-dorsal sections the fine reticulated stroma of the anterior columns shows irregular thickening of its interlacing fibres,

[1] 'Med.-Chir. Trans.,' vol. xlviii, pp. 258, 259.

[2] Ibid., vol. li.

[3] Ibid., vol. lxi, p. 82.

most marked towards the *cul-de-sac* of the anterior median fissure, where the stroma is in parts converted into a solid granular material; in this the nerve-fibres are imbedded; some of them remain perfect, but most are disintegrated. In several specimens a similar change can be seen in the posterior columns close to the grey commissure. The alteration in the stroma appears to commence by thickening of the fibres, followed by exudation. The lateral columns remain normal. In the anterior cornua the vessels are, in most specimens, dilated, and leucocytes surround some of them in great numbers. The ganglion cells are mostly well formed, and surrounded by wide spaces, but in several cases they are shrunken, ill-defined, and not separated from the stroma by any space. In the tractus intermedio-lateralis the cells are mostly distinct; in the posterior cornua they appear in many specimens altered, as in the anterior. This shrinking of the ganglion cells has already been observed by Dr. Ross, and described in the thirtieth volume of the Society's 'Transactions' (p. 217). The thickening of the stroma in the posterior columns causes the fibres of the posterior roots of the spinal nerves to appear very indistinct, or to disappear entirely, at the part where they sweep round the posterior towards the inner aspect of the posterior cornua.

At the *post-mortem* examination of this case the pedicle of the tumour was found to be undergoing the normal changes which follow complete intra-peritoneal ligature. The broad ligament was split and dissected up as far as the ligature, but no bruised nor enlarged nerves could be detected by the pocket-lens. The ligature itself had been drawn very tightly, the distal and proximal sides of the stump of the pedicle had bulged over the constricting silk and become united by adhesions, which prevented sloughing of the distal portion. Olshausen[1] gives a table of twenty-four cases of tetanus following ovariotomy, and we find that one operator lost seven out of a total of twenty-nine cases from this deadly complication. There is strong evidence that this high mortality was due to irritation of the pedicle by retained harelip pins and to its frequent disturbance, partly perhaps through the over-anxiety of the surgeon, but in some cases through secondary hæmorrhage, which indicates, according to Olshausen, an insufficient tightness

[1] "Krankheiten der Ovarien," Pitha u. Billroth, 'Handbuch der allgemeinen u. speciellen Chirurgie,' Band iv, Lief. 6, p. 367.

of the clamp, so that the nerves of the pedicle were not so thoroughly crushed as to be rendered powerless in exerting morbid reflex action.

On the other hand, the pedicle had been very tightly ligatured in the case from which these sections were taken. It is most probable that the tetanus was not caused by irritation of the nerves of the pedicle, but from the influence of a draught on the patient's cheek, which induced inflammatory changes in the cord, partly as an interstitial inflammation, partly as a kind of catarrh of the lining membrane of the central canal.

That these changes may be found as the result of other diseases, we have no doubt, nor shall we be surprised if many consider them as artificially produced by media employed in hardening and staining the sections, or as the result of decomposition. The fact that exudations, dilated vessels, and abnormal appearances about the central canal are observed in affections differing from tetanus does not of itself prove that similar conditions may not exist in this disease. Indeed, its clinical symptoms do not encourage us in the expectation of finding any specific change in the cord, which, on the other hand, we feel must be the structure partly if not chiefly at fault. As for artificial appearances, we fail to observe the above-described changes in any of the numerous sections of normal cord which we have prepared in precisely the same manner as these specimens, whilst we have rejected all belief in the morbid nature of the transparent patches seen in a few of the sections since we have found such patches constant, and widely diffused over sections taken from a cord evidently decomposed. These alterations, the source of which is so evident, are very different from those to which we call attention, namely the dilated vessels, the interstitial exudation, and the singular changes around the central canal. Hence the opinion that these changes are truly morbid seems far more reasonable than the hypothesis that they are produced by chromic acid, decomposition, or logwood. *April 6th*, 1880.

---

3. *On degeneration and regeneration of the axis-cylinder in non-traumatic nerve lesions, with special reference to gangrene of the cutaneous nerves.*

By George Hoggan, M.B.

In submitting to the Society preparations showing the condition of the axis-cylinder in degenerating and regenerating nerve-fibres, we only profess to bring before it a part of a general research into the changes of the nerves in a case of gangrene of the leg, but that part constitutes what is by far the most important question in the pathology and physiology of the nerve-fibre.

Up to the present time, as far as we are aware, all investigations into the changes in the axis-cylinder have been made by means of experimental lesions in the lower animals, and the results thus obtained have been generally accepted as applying to lesions of the same element in man. Until lately we also have been of this opinion; but as the result of certain investigations in non-traumatic lesions, we have been led to recognise that the nature of the lesion may modify profoundly the characters and sequence of the changes, more especially in regard to traumatic lesions. As the complete history of the later investigations is given in Ranvier's recently published classic work, 'Leçons sur l'histologie du système nerveux,' it may be considered sufficient, when we have to make a statement with regard to previously ascertained fact, that we should merely give the reference to it in that work, instead of explaining it at length in this paper.

Hitherto it has been the habit, when producing experimental lesions in the lower animals, to inflict at the same time a wound; and although Ranvier informs us that whether the lesion be effected by cutting with the scalpel, or crushing with pincers, the results are always the same (loc. cit. p. 28, vol. ii), yet it is always advisable to cause as little disturbance as possible. The greatest care, however, that can be taken is equally successful with the greatest disturbance in giving results differing from those found in non-traumatic lesions. The gentle cut of a sharp scalpel, when it is practised upon a healthy nerve, localizes the point of lesion even to the interannular segment through which it passes, and thus severs the connection of a healthy peripheral portion of nerve from the

healthy central portion, and permits the latter to begin at once its efforts of regeneration, even although for the first few days these may be microscopically imperceptible. In non-traumatic lesions in general, as, for instance, in leprosy, we have no such localization; but in gangrene of the leg we have the nearest possible approach to it, and it is for that reason that we specially bring the condition of the axis-cylinders in this lesion before you.

The history of the present case may be stated in a few words. The patient was an aged man in poor circumstances, the same medical man had not treated him throughout his illness, and no notes had been taken of the case. There was very distinct evidence of vegetations on the cardiac valves, justifying the belief that a portion of these had become detached, and had formed an embolism in some one of the arteries of the leg, thus causing the gangrene. In reply to direct inquiry we learned from one of his medical attendants that on several occasions a line of demarcation seemed about to form low down in the leg, but on each occasion a relapse had occurred until a healthy line had formed below the knee, and he was finally admitted into the Temperance Hospital, where amputation was performed by our friend Dr. James Edmunds, to whose kindness we are indebted for the material we have investigated. We carefully laid bare the internal and external cutaneous nerves, upon which the line of demarcation was as distinctly marked as upon the skin of the leg; we next placed two ligatures gently upon each nerve, five millimeters above and below the line of gangrene; other ligatures were then placed ten millimeters below and fifteen above the former ligatures, and the nerves having then been dissected out without tension being applied, were placed respectively in osmic and chromic acid solutions. When the desired reaction had taken place they were placed for a fortnight in a carmine-staining solution. Transverse sections were then made immediately below each of the upper three ligatures, and the remaining portions were prepared as teased specimens and preserved in glycerine and varnish.

In an experimental lesion, the cutting of the nerve leads to the separate consideration of the elements in the central and peripheral portions respectively, as well as of certain phenomena dependent on the infliction of a wound. In gangrene no such distinct divisions exist, but the healthy and degenerating portions of the nerve or axis-cylinder may be considered separately, and held roughly to represent the central and peripheral portions.

Axis-cylinder in healthy portion of nerve.

To understand the difference between the appearances we have obtained and those obtained in experimental lesions, a short review of the opposite opinions held by different observers may be necessary, the review, however, being confined to the history of the last ten years since Ranvier first announced the discovery of the mononucleated interannular segment. Of these opinions only two are serious enough to require consideration. On the one hand, we have Engelmann, Neumann, and others, who, consistently with their theory that the axis-cylinder is formed of portions corresponding in length to the interannular segments and joined together at the annular constrictions (loc. cit., p. 41, vol. ii), hold that, when the knife has passed through the interannular segment, the portion of axis-cylinder between the point of section and the first constriction on the central side breaks off and degenerates, as it degenerates in the peripheral portion of the nerve (loc. cit., p. 40). Ranvier, on the other hand, who believes that the axis-cylinder proceeds from and is continuous with the nerve-cell in the nerve-centre, holds that the portion of axis-cylinder between the point of section and the first constriction on the central side not only undergoes no retrogression (loc. cit., p. 40), but, on the contrary, becomes hypertrophied and striated longitudinally (loc. cit., p. 37), as if formed of a bundle of smaller fibrils (loc. cit., p. 36). However much these observers may differ in the foregoing opinions, they all agree that the changes in the axis-cylinder do not pass up beyond the first constriction.

Not only in the peculiar form of the termination, but also in its not being limited to any special level, there is the utmost diversity from the above-mentioned conditions in the case before us. In some fibres we have found the termination ten or twelve centimeters above the line of gangrene, and in other fibres the terminations are found eight centimeters below the line of demarcation, and actually disintegrating in the midst of the gangrenous blood and tissue. Although the destructive agent may be supposed to have encroached or mounted up the nerves on one level, there is diversity between difierent nerves, different funiculi in the same nerve, and the individual fibres in the same funiculus; and this diversity is even better marked in the other elements of the nerve fibre than it is in the termination of the axis-cylinders. In this

respect, therefore, it may be fairly assumed that the conditions in traumatic and non-traumatic lesions are unlike.

In the form of the axis-cylinder termination an even greater dissimilarity exists, for we there find an appearance for which it is difficult to account. Perhaps, by way of explaining this, we may be allowed to suggest the example of the stalk of the *Vallisneria spiralis*, and the appearances it presents when it elongates and retracts, as being similar to that shown by the end of the axis-cylinder respectively in regeneration and degeneration.

It is not meant by this to hold that the cause of the similar appearances is the same in each. That cause may really exist in the movements of the inner layer of protoplasm of Mauthner, which surrounds the axis-cylinder and lies between it and the myeline, and which, by some peculiar form of contraction, may cause the termination of the axis-cylinder in retracting from the point of rupture to assume the spiral form. Or the cause may exist in some tendency of the axis-cylinder to retract as a spiral spring would retract when, after being kept extended as a straight wire, it returns into the spiral form when its connection with the extending agent is broken. Either of these causes might produce the appearance we refer to; but although the latter may be reproduced to a slight extent artifically by the act of teasing, it is more probable that the spiral is due to the action of the surrounding protoplasm.

From a comparative study of numerous spiral terminations, we are inclined to believe that the spiral is formed very gradually, being at first no more complicated in appearance than an ordinary corkscrew. Retraction may go on slowly through several interannular segments without disturbing in any way their myeline or other elements, the shortening being provided for by the coiling of the axis in the spiral. This spiral, though at first comparatively open, gradually closes up, until in many cases we only see a transverse or slightly oblique striation as the evidence of the successive coils of the axis-cylinder, and we generally notice also that the surrounding elements or sheaths become bulged out by the coil within them.

It some cases it is seen that, in the interannular segment immediately below the one containing the spiral coil, the myeline and segmental nuclei have undergone the usual segmentation of degenerating nerves, but this condition is by no means invariable, for in several instances two and even three interannular segments may be seen with their elements intact beneath the one containing the spiral

termination. Indeed, it would seem as if the destruction of the other elements in an interannular segment may depend upon their being left by the axis-cylinder, the fact that at one time there may be two or three segments unaltered in myeline or nuclei, and that at another time degeneration may have overtaken the segment next to the one containing the axis-cylinder termination, being explained by the interval of time elapsing between the period of retraction and the period of examination.

In some cases we may find the long spiral coil occupying a large portion of two contiguous interannular segments, and at the point where the axis-cylinder passes from the one to the other it remains straight for a short distance. At other times we may find two, or it may be three, close spirals within a short distance of each other in the same nerve-fibre. This may be due to synchronous retraction and formation of coils, or it may be the result of a second retraction following upon incomplete regeneration, a process which is very common and well marked in this case upon the other elements of the interannular segment. It must, however, be understood that the formation of a spiral depends upon the fact that above the point of rupture of the axis-cylinder that element is healthy and retains its normal properties. In several cases we find some exceptional appearances where the termination of the axis-cylinder has been encroached upon by the gangrenous fluids or elements without causing subsequent rupture. In such cases the termination may be bulbous or unchanged in shape from the rest of the axis-cylinder, but it will generally be found to be granular, presenting a decided contrast with the clear hyaline condition of the axis-cylinder in the same fibre some distance further up. In short, in such cases the axis-cylinder termination on the central side is evidently undergoing the same peculiar changes which it undergoes in the peripheral or degenerated portion of the nerve-fibre, without becoming separated. This condition will be explained when we come to speak of the destruction of the axis-cylinder in that portion.

It will be understood from the foregoing that there is no resemblance between the spiral termination of the axis-cylinder in non-traumatic lesions on the central side of the nerve, and the descriptions or hypotheses given by other observers in experimental lesions. The fact that in no case have the terminations any definite relations with the annular constrictions independently of their spiral

condition, excludes any comparison with the opinion of Engelmann. With the opinions of Ranvier it has equally nothing in common, for that observer noticed that the axis-cylinder between the point of lesion and the nearest constriction not only underwent no retrogression, but had hypertrophied and become fissured longitudinally.

The existence of the distinct spiral termination having been clearly demonstrated and admitted, one may be fairly met by the suggestion that such appearances were *post-mortem* ones, and due perhaps to the mechanical action of the teasing needles. So legitimate an objection has been anticipated, and I may therefore detail the precaution taken to meet it. For investigating the condition of the axis-cylinder in nerves, it is necessary that these should be fixed in solutions of chromic acid, or of the chromates, and the axis-cylinder and nuclei stained with carmine. The individual fibres have then to be carefully separated by teasing needles, and finally clarified by essential oils (for here glycerine is of no use, owing to the opacity of the myeline), and mounted in varnish. These various steps entail a perfect host of distortions and damages to the nerve-fibres, with which all working histologists are only too well acquainted. How far, then, may these have affected the elements in question? It is well know that chromates have the effect of fixing and hardening the axis-cylinder in an especial manner, so that if it possesses any peculiar form when placed within it, it is certain to retain the same form afterwards. This is seen continually in the kind of preparation referred to, where the teasing needles often break off the protoplasm and myeline sheaths from the axis-cylinder, leaving that element naked and straight as a cane, with portions of the aforementioned sheaths still adhering to it. In the present case the needles have in many instances broken in upon the spiral endings, and ruptured or drawn them out of the en-sheathing elements. But in such cases the spiral axis-cylinders still retain the spiral form, showing that they had been fixed in that condition, and that they had existed before being placed in the chromic acid solution. At the same time it must be admitted that in nerve-fibres which are known to be perfectly normal, belonging, in fact, to the lower animals, this tendency to form *loose* spirals is constantly seen. These loose spirals (and sometimes dilated portions of the axis-cylinder) are apparently due to contraction of the protoplasm of the surrounding interannular segments, which forces

the comparatively rigid axis-cylinder to adapt itself to changes in their length. We are, therefore, of opinion that the tendency to form a spiral is a natural one in normal nerves, and that the pathological coils we have described are merely exaggerations of a natural tendency.

The next serious question is how far the mechanical injuries inflicted by the teasing needles may account for these appearances. This question may be fully met in two ways. In the first place, we have made sections across such nerves with the razor, and found it pass in some places through such spirals, examples of which are shown under the microscope. In the second place, we show examples of such spirals within nerves still undisturbed in the bundle where they lie with several other unaffected nerves, so that, according to these facts, we may fairly claim that no undue tension or action of the teasing needles has led to the formation of spirals. The action of the needles, however, in causing mere breaks or endings in the axis-cylinder is a very common one. The longer the axis-cylinders have been exposed to the fixing agent, the greater is the number of the broken axis-cylinders that one has to expect in such preparations, and undoubtedly there are many cases where it is difficult to decide whether the breaks are natural or artificial ones; but it is in full consciousness of the foregoing objection that we offer the spiral termination as the natural condition in non-traumatic lesions.

II. *Regeneration of the axis-cylinder.*

According to Ranvier, and consistently with the hypertrophied and fibrillated condition which he describes in the terminal portion of the axis-cylinder on the central side intervening between the point of lesion and the first annular constriction, the regenerating axis-cylinder, or rather cylinders, are formed from the fibrillated portion, in which the longitudinal striæ are supposed to deepen until they end by dividing the original axis-cylinder into separate fibrillæ or axis-cylinders, around each of which a new medullary sheath is supposed to form (loc. cit., p. 71, vol. ii). Beyond the fact that Ranvier has found a leash of young segments growing from the extreme constriction on the central portion of the nerve, we fail to find any direct observation of the axis-cylinders in such cases (as, for example, in a chromic acid preparation), which

would warrant the assertion or assumption that the old axis-cylinder splits up into several young axis-cylinders.

Even were such the case in experimental lesions, it cannot apply to non-traumatic lesions, for although we have found and examined several hundreds of instances of regeneration in nerve-fibres in non-traumatic lesions in man, we have never yet met with a single case where two or more young interannular segments proceeded from the same constriction. In all cases the young or new segments were either interposed between the normal segments on the healthy or central part of the nerve-fibre, or, when added peripherally, a considerable distance or break generally existed between the young or newly developed segments; both conditions being, therefore, incompatible with Ranvier's hypothesis, however applicable it might be to traumatic lesions.

It is also to be borne in mind that, in regenerating nerves prepared with osmic acid, carmine, and glycerine, although the myeline in the very smallest young segments may be made abundantly evident, it is impossible to observe the axis-cylinder. On the other hand, in such nerves prepared with chromic acid, carmine, and varnish, it is with great difficulty that the axis-cylinder is made evident, and it is almost an impossibility to detect the myeline of a newly forming segment as it lies within the contorted sheath of the formerly degenerated segment. These conditions show that, in our present state of histological processes, it is almost impossible to give a precise opinion on the various conditions of axis-cylinder regeneration.

Nevertheless, certain appearances seem to warrant us in stating that the process of regeneration is a very simple one, being merely the reversal of the movement of retraction into a coil; that is to say, when regeneration is about to take place from a healthy termination, the lower part of the spiral uncoils itself, and in doing so naturally elongates itself in the peripheral direction, and thus passes into and through the regenerating segments which may have been developed peripherally in the irregular manner already described. Such an example is seen under one of the microscopes, and the likeliest interpretation that can be placed upon the wavy fibre passing down from the long spiral coil is that it is elongating itself peripherally. It may be said, for the sake of argument, that where we have the termination of an axis-cylinder equally exposed to degeneration and regeneration, it is impossible to state with

certainty whether the long tail-like fibre, such as is seen in that example, is in the act of retraction or elongation. Such an objection is quite admissible, and one is really forced to rely to a great extent upon one's judgment to decide the matter. In the present case, however, independently of the support that similar fibres, in more or less advanced conditions, of the same kind lend to the hypothesis, more especially when the tailed spiral is followed by a slender regenerating segment, we continually observe that in spiral endings, such as that seen in another specimen to be lying within the gangrenous zone, and therefore not likely to regenerate, the termination is truncated or abrupt. The same abrupt termination as a spiral without the tail is seen in many other specimens in the healthy portion of the nerve trunk; and this condition, therefore, we hold to represent the retraction of degeneration before it begins to show the elongation of regeneration. We, therefore, offer the tailed spiral specimen as a typical example of regeneration of the axis-cylinder, that regeneration by peripheral elongation being entirely in accord with the development of nerves as studied in the tail of the tadpole, &c. The whole process of retraction of the axis-cylinder from a considerable length of nerve-fibre, and coiling itself up as a spiral, which acts as a reserve magazine, appears to be a beneficent provision in anticipation of subsequent regeneration.

We have not entered into the question of regeneration of other elements of the nerve-fibres in this research, but under the microscope some specimens of medullated interannular segments in the act of regeneration, as well as some regenerating segments undergoing the normal form of degeneration before they had completed regeneration, amply testify to the irregular conditions of regeneration and degeneration which characterise the nerves in the present case of gangrene. This same appearance of degeneration supervening upon regeneration, and regeneration taking place in degenerated axis-cylinders is also seen in two of our specimens, one of these axis-cylinders being in an entirely newly regenerated fibre, as shown by the peculiar elongated form of the segmental nucleus, the other being a small portion of a very slender regenerated axis-cylinder adhering to the older and larger axis cylinder, at the ends of both of which degeneration, or rather disintegration, is going on at the same time. The termination here, however, is unlike the form already described, being modified by the altered circumstances which will be explained under the third head.

III. *Axis-cylinder in degenerating portion of nerve.*

If the termination of the axis-cylinder on the healthy side be of most importance, on account of its relation to regeneration, its condition on the degenerated side is interesting as involving the process of disappearance or absorption, a process which has not yet been explained by any one.

It is scarcely necessary at the present day to invoke the opinions of Remak, Schiff, and others (loc. cit., p. 325 vol. i.), that the axis-cylinder persists indefinitely in the peripheral portion of a cut nerve; for it is now generally admitted that the axis-cylinder breaks up into portions of a greater or less size, but beyond this fact nothing further seems to be known of its final disappearance. The manner in which it breaks up is supposed by Ranvier to be due to swelling of the protoplasm (loc. cit., p. 323) immediately surrounding the segmental nucleus; while, according to Engelmann's theory, it first breaks up at the annular constriction by a kind of unsoldering or disjointing of itself into its primary portions, each of these portions being supposed by both observers to break up afterwards into smaller pieces. It may be mentioned here that the great irregularity found to exist in the length of the broken portions, and the absence of any regular relationship to either annular constriction or segmental nucleus in the case under consideration, makes it evident that neither view nor the limitation to any one locality can be invariably correct.

The first question of importance to be settled is the distance that may intervene between the central and peripheral termination of a broken axis-cylinder. No one, to our knowledge, even refers to this question, although the respective theories could not admit in any case of more than the length of the one interannular segment. We have found, as already mentioned, greater distances than this intervening, so great a distance, indeed, that the two terminations are not often to be seen in the one preparation of nerve. Under the microscope, however, we have placed a specimen which shows both termination and their character at the distance of about three millimeters from each other.

The peripheral portion in that case appears to have retracted in an irregular spiral, or rather zigzag, like the central portion, and it may also be remarked that that peripheral termination bears a close resemblance to the peripheral portion in an experimental lesion, as

figured by Ranvier. This particular form of peripheral termination only seems to take place in healthy elements, where the axis-cylinder may have preserved its elasticity, or the protoplasm its contractile power; for when we examine the condition of the axis-cylinder in portions of the nerve invaded by the gangrenous fluids, we find altogether dissimilar appearances or conditions in existence.

While, in what are commonly called degenerating nerves, the changes undergone by all the elements are really embryonic and not morbific, in the present case we have true death supervening in them all, and this death is best marked in the axis-cylinder.

In examining the many diverse forms assumed by the perishing axis-cylinder, the first thing which makes itself prominent is the evidence of the existence of a cavity or canal within that element. This may be considered only another form of expressing the views of certain authors (loc. cit., p. 88, vol. i), that the axis-cylinder possesses an enveloping membrane. We, however, hold it to be entirely distinct, as shown by its pathological consequences. It appears to exist in the centre of the axis-cylinder, and when death approaches in this element, we find the external portion becoming finely granular in consistence and the central element clear. That central element begins to swell, forming great bulgings or dilatations at different parts of the axis-cylinder, and almost invariably at the termination (or ends of the broken, portion, when such exist). These dilatations may be either globular, oval, or most commonly elongated upon the axis-cylinder, and bearing apparently the same relation to that element as the *receptaculum chyli* does to the thoracic duct.

When such swellings exist we commonly observe that not only is the granular matter compressed on the periphery, but at many places it does not seem to have sufficed to occupy the whole of the periphery, but leaves large clear spaces, which look like windows, in the granular wall, an appearance which may really be due to the existence of a membrane in addition to an axile canal. This appearance is shown in several of our specimens.

After a certain time these dilatations may burst like vacuolated cells, and then we may observe a torn or lacerated condition of the wall in certain specimens which have burst; this condition, moreover, is seen to exist in the terminations of axis-cylinders whose connection with the nervous central system appears to be unbroken, as if the unbroken axis-cylinder was undergoing destruction without

previous separation, in the same way that the fingers of a living being might be charred and burnt. At other times the elongated dilatation may become contorted or bent round like a shepherd's crook, as shown in one specimen.

This appearance is probably due to the irregular action of the protoplasm surrounding it, but this action is perhaps better shown in the fragments of axis-cylinder that have been cut off from the parent stem. In these smaller portions the subsequent history of the disintegration of the axis-cylinder may be traced, for in many of the specimens not a single stage is awanting. The axis-cylinder may be broken up before the bulging takes place, and then we may observe the vacuolation or bulging taking place in the separated portions; and, when they burst, the granular material which distinguishes even their *débris* may be observed mixing with and becoming lost amongst the *débris* of the other elements constituting a nerve-fibre.

In the present case the line of demarcation, and at least six centimeters below it, merely represented staining by blood-pigments and not distinct death; below that interval, however, distinct death existed, and innumerable pus-cells were to be found both between and within the degenerated fibres, as shown in the specimens. Large numbers of altered blood-corpuscles also lay between the fibres, but not distinctly within them, and the nutrient blood-vessels of the nerves in this locality were distended by them. It will, of course, be understood that for the present the conditions we are describing are only given as applicable to gangrene, and not to other non-traumatic lesions. The appearance of the spiral terminations is, however, common to other non-traumatic lesions, as, for example, in the nerves of anæsthetic leprosy.

It is also of consequence to inquire into the relation between the spiral endings in healthy axis-cylinders and the multiform terminations found within the gangrenous zone. Luckily enough, certain connecting links exist where a spiral ending is seen to be undergoing the same granular disintegration that characterises the broken-up portions of disintegrating axis-cylinder in the completely degenerated nerve. These granular spiral terminations are found a little way up to be continuous with perfectly healthy segments and hyaline axis-cylinder, proving indubitably that a healthy spiral termination had formed, at that point, subsequent to separation of the axis-cylinder further down the nerve at a time when the gangrene had not extended up to its final line of demarcation.

When, however, that extension had taken place upwards, it had enveloped the spiral without causing subsequent separation ; granular disintegration followed in due course, and thus the partially disintegrated spiral attached to a healthy axis-cylinder remained as a link connecting the one process (the spiral ending) with the other (the granular distension), and showing that that spiral ending had existed for a long period, it might be many days, or even weeks, before the nerve while still alive was taken by us from the patient's limb. This, therefore, formed a third proof, and one even more convincing than the spiral shown in transverse section, and also those shown in an undisturbed nerve bundle, as evidence that the spiral form of termination was neither due to reagents nor mechanical injury, but was truly an *ante-mortem*, and therefore natural, appearance.

While, in the gangrenous zone, the presence of a granular and disintegrating termination of an unbroken but unhealthy axis-cylinder enabled one to establish the connection between it and the round or oval fragments of broken-up axis-cylinder which were also granular and as if vacuolating, the information thus given, when applied to the nerve-tubes destitute of axis-cylinder, enabled us to discover the vestiges of the remains of that axis-cylinder in elements that would certainly not have been recognised as such at first sight. It can also be understood that the wide internal left between the spiral termination of healthy (?) axis-cylinder of both central and peripheral portions is so great that only by the rarest chance can they be observable in the same preparation. The consequence of this has been that the final changes in the broken-up and disintegrating axis-cylinder have not hitherto been recognised. The information we have just referred to has enabled us to understand what takes place in such peripheral portions of healthy (?) axis-cylinder. It breaks up into portions which retract into shorter lengths along the whole line of axis-cylinder; these in turn may again subdivide until they appear oval or globular, and finally become granular or pseudo-vacuolated, and as they refuse to take any colour stain they are only to be recognised as transparent vacuoles. These, when treated with osmic acid in excess, appear as balls of black granular matter within the tubes. These granular balls have long been recognised, but no one knew precisely what their origin was, just as they did not know how the axis-cylinder disappeared, the answer of the one being the answer to the other.

It is perhaps of little use here to enumerate the various theories of their origin;—whether they were granules developing in protoplasm or evidence of duality in the composition of myeline, as Ranvier has endeavoured to prove (loc. cit., p. 9, vol. ii). The interpretation we give may suffice. But the manner in which the axis-cylinder breaks up and disappears gives valuable evidence on two most important points. In one of the nerve-fibres under the microscope the axis-cylinder is seen to terminate, and the fragments which have broken off from it are seen to occur at intervals along the nerve for a distance of at least three interannular segments, and these fragments have become globular and granular; they are, indeed, dead and disintegrating. It is also evident that in the three interannular segments containing the disintegrating fragments of axis-cylinder none of their elements have undergone any change, the segmental nuclei being remarkably distinct and showing no tendency to proliferate. This may be held to prove that the axis-cylinder may degenerate independently of any change in the elements of the interannular segment, and that, in opposition to the school represented by Engelmann, the axis-cylinder within an interannular segment has no biological connection with it.

It is further evident that, when portions break off an axis-cylinder in connection with its nerve centre, they evidently die and disintegrate when in the same fibre, or in similar conditions the elements of the interannular segment merely undergo the embryonic degeneration of inflammation. This fact gives the strongest possible support to the hypothesis emitted by Waller and Ranvier (loc. cit., p. 73, vol. ii), that the axis-cylinder is merely a portion or prolongation from the nerve-cell in the nerve-centre; the portions broken off being like portions broken off a living cell, they die but do not proliferate. This behaviour is also incompatible with the view that the axis-cylinder is made up of independent elements corresponding to the interannular segments, as held by Engelmann (loc. cit., p. 128, vol. i), for in that case, even when separated from the nerve-cell in the nerve-centre, they ought to possess independent life and action, as do the interannular segments when separated from the rest of the nerve.

Conclusions.

The conclusions arrived at in the foregoing pages are the following:

1. In non-traumatic lesion or break in the healthy axis-cylinder,

both extremities retract in the form of a more or less irregular spiral, the interval between them increasing gradually up to an uncertain limit, which may include several interannular segments.

2. There is no regularity as to the level at which separation in a healthy axis-cylinder may take place, and this irregularity holds good, not merely as regards different nerves at the same level, but in different funiculi of the same nerve and the different individual fibres within the same nerve-funiculus. In the case of gangrene, the irregularities were seen beyond a range of five centimeters. The same irregularity holds good in degeneration of the segmental elements.

3. In general, withdrawal or retraction of the axis-cylinder termination precedes the changes in other elements of the forsaken interannular segments, segmental nuclei unaltered being detectable at and beyond the central spiral termination.

4. In regeneration of the axis-cylinder the central spiral ending seems to have acted as a reserve, and its termination uncoils, so as to push as a straight fibre towards the periphery, and it receives no aid from the peripheral portion of the axis-cylinder.

5. When the new or young interannular segments are added at the extremity of the central portion of the nerve, the axis-cylinder seems to push into and through them. When, however, they are interposed between the already existing healthy segments, the axis-cylinder is seen to be even thicker within such half-grown segments than within the more peripherally placed normal segments.

6. In the peripheral or degenerated portion of the nerve (in *gangrene*) the axis-cylinder breaks up very irregularly into pieces of greatly varying size. After it breaks, or before it breaks, granular disintegration and pseudo-vacuolation of the whole or portions of the axis-cylinder take place. These pseudo-vacuolations burst, and their *débris* becomes absorbed or mixed with the *débris* of the other elements of the degenerated nerve-fibre.

7. The fragments which break off the axis-cylinder undergo morbid degeneration, although the elements of the interannular segments within which they lie remain unchanged, proving that there is no biological connection between segment and axis-cylinder.

8. As the above-mentioned fragments undergo morbid degeneration, when in similar circumstances the elements of the interannular segments undergo the embryonic degeneration of inflam-

mation, it is clear that the former are not independent entities like the latter, but are probably, as supposed by Waller and Ranvier, in dependent continuation with the central nerve-cell.

9. The behaviour and appearances in the axis-cylinder that we have described differ in almost every particular from those seen in experimental lesions in the lower animals. Assuming the latter observations to be correct, the difference is probably due to the irritation and destruction of the segmental elements by the action of the knife or pincers employed to cause the lesion.

10. The granular balls seen in advanced degeneration of nerves in osmic acid preparations are in most cases the degenerated *débris* of fragments of axis-cylinder. *2nd March*, 1880.

---

4. *A case of supposed rupture of most of the roots of the brachial plexus.*

By Jonathan Hutchinson, F.R.C.S.

The subject of this case was a young sailor named Little. His injury was received in a fall from the rigging, a height of thirty feet or more. It could not be ascertained that his arm was caught in any way, but it is probable that he fell on his shoulder. He recovered quickly from the stunning, and as soon as he had done so it was found that his arm was paralysed. He could neither move it, nor had he any sensation below the elbow.

It was about four months after the accident that J. Little came under my observation as an in-patient at the London Hospital. In addition to the above facts, I was told that five weeks after the accident a surgeon was believed to have reduced a dislocation at the shoulder. I much doubt, however, whether the man had been correctly informed on this matter, for he said that the surgeon had no assistance and was only a few seconds about it. The condition of the arm when the man came to me was such as to suggest the diagnosis of rupture of the four lower roots of the brachial plexus. With the exception of the triceps, brachialis anticus and coraco-brachialis, the muscles of the upper extremity were wholly paralysed. The deltoid was also quite paralysed, as also the latissimus

dorsi and the lower part of the great pectoral, whilst the upper part of the latter and the rotators of the humerus arising from the scapula had escaped. The forearm and hand hung helpless, but the elbow could be flexed and the forearm supinated. There was no sensation below the elbow, and it was very defective over most of the upper arm and deltoid region. The hand was chilly and dusky, its temperature and colour varying with the heat of the ward. The muscles were much wasted, the girth of the arm being only seven inches, whilst that of the injured one was nine and a half. No lesions of nutrition had occurred excepting that the skin generally was flabby, and the finger-ends a little tumid. The condition of the eye was of great interest, and gave strong support to the diagnosis. In strong light no great difference could be observed in the size of the pupils, but when shaded the right dilated much more than the left. The palpebral fissure was distinctly narrower than the other, and the eye had the appearance of being smaller (due to slight retraction). The pulse at the wrist of the paralysed arm was extremely feeble, contrasting very greatly with that of the other side.

Amongst the reasons which incline me to believe that in this case the lower roots of the brachial plexus have been torn, are the following:

1. Both sensation and motion are involved in the paralysis.
2. There were no cerebral or spinal symptoms at any time.
3. The paralysis in the parts involved is complete.
4. The sympathetic trunk of the neck, which takes its origin from the brachial tract, is in part involved.
5. The parts which have escaped are mainly those which are supplied by the first root of the plexus.[1]
6. The case is very similar to others which have been recorded.

My conjecture is that, in falling, the arm was probably caught and dragged away from the side in a direction obliquely upwards, and that the nerve-roots were dragged away from their attachments to the cord. I have never had an opportunity for dissecting such a lesion, but have seen several cases in which this diagnosis was the only one which explained the facts. That laceration at this point may occur when the arm is forcibly dragged away from the body was proved by *post-mortem* examination in a case recorded in Paris,

[1] I am aware of a few minor points in anatomy which may seem unexplained, but I do not think that they really are so.

in which brachial paralysis resulted from the efforts used to reduce a dislocated humerus.

The patient whose case is here narrated was exhibited to the Society. He still remains under my observation, and I purpose at some future time to record the sequel.[1]

[1] See a case published by Sir James Paget, 'Med. Times and Gazette,' March 26th, 1864; also one by Dr. Weir Mitchell, on 'Gunshot Injuries of Nerves,' p. 43; and a case of my own, 'Illustrations of Clinical Surgery,' vol. i, p. 206.

II. DISEASES, ETC., OF ORGANS OF RESPIRATION.

1. *Case of membranous inflammation of the larynx, trachea, and bronchial tubes in an adult.*

By P. H. Pye-Smith, M.D.

Harriet G—, a married woman, æt. 24, was admitted into Guy's Hospital, under my care, on the evening of December 28th, 1879.

She was advanced in pregnancy, but had been well until four days before, when, after increasing a slight cold by sitting in a room with linen drying, she went out of doors and was exposed to the severe weather of Christmas eve. Next day she shivered and vomited, and on the 26th brought up two thick pieces of membrane from an inch to two inches long. Dr. Shadwell of Walthamstow, saw her then and found moderate pyrexia, pain referred to the larynx, and the fauces perfectly free from membrane. "It was" he says "certainly not diphtheria, but what in a child I should have called a typical case of croup." On the fourth day of her illness she threw up a complete cast of the trachea, with both bronchi and their ramifications. She came up to the hospital that evening, and brought this cast as now exhibited, spread out and dried upon paper like a piece of seaweed.

On admission, the house physician found her suffering from great dyspnœa and moderate fever. There was mucus upon both tonsils, but he could see no false membrane. The urine was free from albumen.

When I saw her next day the fauces were perfectly clear, but there was muco-purulent secretion covering the back of the pharynx. She was in great distress from orthopnœa, but the pulse was not soft, and there was no prostration; her voice also was unaffected in character, though weak from difficulty in expiration.

Temperature this morning 102·2°, having fallen from 102·8° last night.

Next day she was delivered and lost but little blood. In the afternoon I found the throat quite clear. Temp. 99°, pulse 140, resp. 48. No dulness, but râles over both sides of the chest. Expectoration free and purulent; no membrane has been coughed up.

The following day (Dec. 31st) the dyspnœa was rather diminished, but she was unable to swallow. Though this inability disappeared in a few hours, she became steadily worse, and in spite of stimulant treatment died early in the morning of the new year.

At the *post-mortem* examination the fauces were apparently healthy, but on careful scrutiny we discovered a minute superficial ulcer behind the left tonsil. There was no trace of membrane, and the surface of the tonsils, palate, and pharynx, was normal. There was no ulceration or œdema of the glottis. From the edge of the epiglottis downwards, and throughout both lungs, the mucous membrane was red, mottled, and rough; here and there covered with tenacious secretion and spotted with numerous ecchymoses. Only two small shreds of lymph could, however, be found in the whole course of the trachea and bronchi. There was some frothy muco-purulent fluid in the tubes. Both lungs were affected with well-marked lobular broncho-pneumonia, and there was slight and very recent left pleurisy.

The other organs were perfectly normal. There was no ecchymosis, the spleen was soft but not enlarged, the kidneys were healthy, and the heart firmly contracted.

The doubt as to the nature of the case which I felt during life was not resolved by the autopsy.

In some respects it resembled cases of plastic bronchitis rather than diphtheria, but the decided affection of the mucous membrane, the implication of the larynx and trachea, the fever, absence of hæmoptysis, acute course and fatal result, distinguish it from the former disease.

I need scarcely say it was very different from cases of lobar, so-called "croupous" pneumonia, in which the fibrinous exudation is found going beyond the vesicles some distance up the tubes. (Four cases of this kind are reported by Dr. Bristowe in the sixth volume of our 'Transactions.') In such cases the casts never go beyond the smallest tubes, and they are always secondary to lobar vesicular pneumonia. In the present case the lobular broncho-

pneumonia was obviously secondary to the plastic inflammation of the larynx and trachea.

In several particulars the case differs from what most pathologists would recognise as diphtheria.

The general aspect and condition of the patient was decidedly different. The muscular prostration, the feeble pulse, the "typhoid" condition usually observed, were here absent, and were replaced by the prominent dyspnœa and "sthenic" symptoms, which are supposed to be characteristic of croup.

The fauces were little affected, there was no sloughing or false membrane in this region, and no swelling of the neck or cervical glands.

There was no infection, the house was well drained, and the water had been twice ascertained to be pure.

Dr. Shadwell, who was attending another inmate of the same house, tells me that there was no diphtheria, scarlatina, or fever in the neighbourhood, no sore throat in the house, and no spread of the disease among the children of the patient. I may add that the infant, who died three days after its birth of bronchial catarrh, showed no signs of diphtheria. Lastly, there was no albuminuria throughout the illness.

It appears to me that the clinical aspect of the case, the absence of faucial membrane and cervical œdema, the absence of infection leading either to or from this case, all distinguish it from cases of diphtheria; and this view is corroborated by the firm consistence and minute ramification of the cast, and by the conditions found at the autopsy.

Whether, therefore, we choose to extend the meaning of diphtheria to include all cases of membranous inflammation of the throat and trachea, or whether we admit an acute membranous laryngitis (distinct from diphtheria, on the one hand, and catarrhal laryngitis, on the other), the present case seems to supply an instance of what was sought by the Committee appointed last year by the Medical and Chirurgical Society to investigate the relations between membranous croup and diphtheria—a plastic inflammation of the air passages apart from the ordinary features of diphtheria, sporadic, idiopathic, sthenic, and killing by local, not by general, disturbance.

The occurrence of the disease in an adult and in a pregnant woman are additional points of interest.

The case most nearly resembling this which I have been able to find is one reported in the xxii vol. of our 'Transactions,' by the late Dr. Murchison, as "a case of diphtheria with extension of the membrane to the bronchial tubes." There, however, the fauces were affected, and albuminuria was present. *Jan. 20th*, 1880.

P.S.—From the curious condition in which the cast came into my hands, I feared that there was little chance of histological evidence throwing light on this case, and there was no other false membrane found *post mortem*.

But after the exhibition of the specimen I succeeded, by carefully soaking fragments of the dried-up cast until they were softened and swollen up and then staining, in obtaining specimens which showed unmistakably that it was composed of immense numbers of small, granular, globular, colourless cells, which showed all the characters of leucocytes; with them were mingled short interlacing fibres, not numerous enough to form a network. There were no blood-discs or epithelial cells. A vertical section showed the same characters throughout, except that the exudation cells appeared even more numerous, and the stroma less abundant and more homogeneous. The cells had all the same rounded shape, small size, relatively larger nuclei, and good power of staining with logwood; they were most numerous on the surface of the membrane, which was composed of nothing else. Scattered through the field of the microscope in the needle preparations, and surrounding the edges of the thin horizontal flakes torn off from the membrane, were a multitude of glistening, oval or rod-shaped bacteria. *April 21st*, 1880.

---

2. *Cases of necrosis of the cartilages of the larynx in smallpox and enteric fever.*

By Frederic S. Eve.

I. *Case of necrosis of a portion of the cricoid and of the arytænoid cartilages during convalescence from smallpox.*

I am indebted to Mr. Strugnall, Medical Officer of the Highgate Smallpox Hospital, for the clinical notes of this case. He

kindly presented the specimen to the museum of St. Bartholomew's Hospital.

Hugh S—, æt. 26, a gardener, was admitted to the Highgate Smallpox Hospital, with a severe attack of unmodified confluent smallpox.

He had always been a steady, healthy man. There was no history of syphilis.

His illness followed the usual course until shortly after the subsidence of the secondary fever, when laryngeal symptoms appeared. On the twenty-fourth day of the attack (May 21st), Mr. Strugnall made the following note :—

For the last three days the patient has suffered from laryngeal symptoms. His breathing has gradually been getting worse. This morning the face is rather dusky, and the supra-clavicular spaces are in-drawn on inspiration. Temp. 102·4°, pulse 128.

At about 8 p.m., as the breathing was clearly getting more laboured, tracheotomy was performed. There was some little difficulty in the operation, owing to engorgement of the veins. Chloroform was not used.

The patient was much relieved by the operation.

The following day (May 22nd), 11 a.m., pulse 152, stronger, temp. 103·3°, resp. 48. Restless and delirious during night, at times dusky. No hæmorrhage. He is quieter, but not quite rational, this morning.

9 p.m.—Pulse 140, temp. 103·8°, resp. 60. Still wandering; slight subsultus at times. He takes nourishment well.

About 11 p.m. he became markedly worse. Breathing much more laboured, with delirium and restlessness.

He died at 8 a.m. on the following morning, thirty-six hours after the operation.

The larynx presented the following appearances :—The arytænoepiglottidean folds were swollen, and their edges turned inwards. The epiglottis was also swollen. The mucous membrane of the larynx and trachea was injected.

Two small, oval, symmetrical, ulcerated apertures were seen immediately behind the posterior attachments of the vocal chords. They led into cavities, containing pus, and formed by the separated perichondrium, within which the necrosed arytænoid cartilages lay.

A considerable extent of the upper margin and posterior surface of the cricoid cartilage around the crico-arytænoid articulation was

also necrosed, and laid bare by the separation of the infiltrated and discoloured perichondrium. The crico-arytænoid articulation was destroyed. The specimen is preserved in the museum of St. Bartholomew's Hospital.[1]

II. *Two cases of necrosis of the arytænoid cartilages in typhoid fever.*

CASE 1.—Albert G—, æt. 36, was admitted into St. Bartholomew's Hospital, under the care of Dr. Southey, May 23rd, 1879, with typhoid fever.

He had been ill ten days before admission. During the early period of the fever he had frequent melæna and on one occasion slight hæmoptysis; otherwise the disease followed the usual course.

The temperature did not rise above 103·6°.

June 8th, the 26th day.—The temperature was normal, and continued so for a fortnight, but the emaciation still progressed.

21st, the 39th day.—The temp. rose again to 101·2° in the evening, and continued steadily rising until it reached 103° on the 27th inst. He was delirious at night. Very prostrate, with a dry brown tongue. Had a bed sore.

26th.—The motions were of a clayey-brown colour.

The exhaustion continued, and he died July 5th, the 53rd day of his illness.

No laryngeal symptoms were observed.

Post-mortem examination.—Lungs œdematous. Intestines:—in the upper part of the lower half of the ileum were numerous partially healed ulcers, and near the ileo-cæcal valve were several large and very deep ulcers; of these, one rested on the muscular coat, another on the peritoneum.

Immediately behind the posterior attachments of each vocal cord was an oval ulcerated aperture, leading into a cavity formed by the separated perichondrium, and containing the necrosed arytænoid cartilage, bathed in pus. Immediately beneath the aperture described on the left side, a prominent portion of the arytænoid cartilage projected through the thinned mucous membrane.

The larynx presented no other abnormal appearances.

The specimen is preserved in the museum[2] of St. Bartholomew's Hospital.

CASE 2.—I have to thank Dr. Church for his kindness in

[1] Series xxv, No. 51. [2] Ibid., No. 52.

allowing me to bring forward this case, and also for the use of his clinical notes.

Eliza I—, æt. 27, was admitted into Elizabeth Ward, July 28th, 1876.

History.—Five weeks ago she felt out of sorts, but was able to do her work until a week before admission, when she had to take to her bed, complaining of headache and sickness; has been sick every day during the last week; had some looseness of the bowels on the day before admission.

On admission there were numerous typhoid spots on the abdomen, but no iliac tenderness existed. Pulse 130, resp. 16, temperature 103·6° Fahr.; at 10 p.m., 104·2°.

She went on fairly well until August 2nd, when the temperature rose to 105°; pulse 148, resp. 44; at 4 p.m., the temperature had risen to 108°. She was then placed in a bath at 95°, which was cooled to 75°, and kept in it for twenty minutes; by that time the temperature in the mouth had fallen to 100·4°.

Between 4 o'clock, p.m. on August 2nd, and the same hour on August 4th, she had five baths, which were administered on account of repeated rises of temperature as high as 104° to 105°.

Although from this time there was a little cough, no pulmonary affection was discovered, and there was no complaint of sore throat.

She appeared to progress fairly well until August 11th, when huskiness of her voice was first noticed, but as no complaint of pain about the larynx was made, little was thought of it.

On the 12th, her voice was more distinct; she could take food without pain, and it was not until the day preceding her death, the 13th, that she complained of pain in the throat.

Dyspnœa then came on, and death took place from exhaustion on August 14th, seventeen days after her admission to the hospital, and twenty-four days after that on which she took to her bed.

Post-mortem examination.—The larynx presented precisely the same appearance as in the preceding case. The arytænoid cartilages were necrosed and lay in abscess cavities, which opened into the larynx by two symmetrical apertures posterior to the true vocal cords.

There was some œdema of the arytæno-epiglottidean folds, and the mucous membrane of the larynx was injected.

Intestines.—There were numerous well-marked ulcers in the cæcum and portions of ileum immediately adjoining it; further up

several of Peyer's patches were still shreddy from ulceration, and still higher, others appeared to have healed. The large intestine was normal. The specimen is preserved in the Museum.[1]

Remarks.—The occurrence of necrosis of the larynx in the course of typhoid fever is briefly mentioned by the majority of writers on the subject. With one exception, they regard the necrosis as the result of the extension of an ulceration down to the cartilage.

One of the latest, Liebermeister, in 'Ziemssen's Encyclopædia,'[2] states that laryngeal ulcers are commonly regarded at present as the result of a circumscribed diphtheritic inflammation of the mucous membrane, which occasionally leads to death by producing perichondritis laryngea.

Sestier[3] takes an opposite view, and believes that the necrosis is produced by inflammation around the cartilages. He has collected fourteen cases of laryngeal necrosis, twelve of which occurred during convalescence from typhoid fever, one in an attack of variola following pleuro-pneumonia, and one in glanders.

Of the twelve cases, all occurred during convalescence from the fever; all the patients were males, whose ages ranged from eighteen to twenty-seven.

The laryngeal symptoms appeared sometimes at the commencement, at other times at an advanced period of convalescence, even after the patient had been discharged from the hospital. Œdema glottidis frequently resulted.

On account of the late occurrence of necrosis, he attributes it to the tendency to abscess, gangrene, and necrosis, exhibited after typhoid fever, and due to the profound debility of the convalescents.

The view, that necrosis of the laryngeal cartilages occurring occasionally in typhoid fever and variola is generally due to inflammation originating in the perichondrium, or possibly, in some cases, in the submucous tissue of the larynx, and not usually to the extension of typhoid ulcers down to the cartilage, is, I think, clearly indicated by the cases collected by Sestier, supported by the three cases related, and various other considerations, as follows:

In one case of typhoid the laryngeal symptoms appeared at a late, in the other at an earlier, period of convalescence. In both

[1] Series xxv, No. 48.

[2] Vol. i, p. 166.

[3] 'L'Angine Laryngée Œdémateuse,' 1852, p. 86.

the fever was attended by special causes of exhaustion; in one, for some days a temperature which rose as high as 108° Fahr.; in the other repeated and severe attacks of intestinal hæmorrhage. The case of smallpox was also of a very severe description.

In the three specimens described the margins of the ulcerated apertures were undermined and slightly ragged, as if produced from within outward, and not by ulceration from the surface extending inwards.

In none of the twelve cases collected by Sestier was there ulceration at any other part of the larynx, and in this respect the three cases related also agree with his.

The ordinary typhoid ulcers of the larynx are stated to occur during an earlier period of the fever, and are regarded as one of the specific effects. The same, of course, may be said of the ordinary variolous ulcers of the larynx.

The fact that precisely similar necroses of the cartilages to those occurring in typhoid fever are also found during convalescence from variola, and in glanders, indicates that necrosis of the larynx is usually not a specific result, but one of the sequelæ of exhausting zymotic and contagious diseases.

Lastly, necrosis of the cartilages of the nose has been observed by M. Henri Roger[1] during convalescence from typhoid fever.

Trousseau[2] has drawn attention to necrosis of the cartilages of the larynx in typhoid fever. In the first case he mentions, the arytænoid cartilages were entirely destroyed, and the inferior constrictor muscles of the pharynx sphacelated. In the second, the patient had suffered before the onset of typhoid fever from hoarseness and other laryngeal symptoms; during convalescence from the fever his laryngeal trouble increased. An abscess formed in connection with the sterno- and crico-thyroid muscles, and on *post-mortem* examination half the cricoid cartilage on the left side was found to have disappeared.

Freudenburger[3] has lately recorded a case of perichondritis laryngea occurring during convalescence from typhoid, and he describes the laryngoscopic appearances. Tracheotomy was performed to save the patient's life.

[1] 'L'Union Médicale,' p. 471, 1860.

[2] 'Clinique Médicale,' vol. i, p. 200.

[3] 'London Med. Record,' Nov. 15th, 1879, p. 465.

Other cases on record indicate that typhoid ulcers of the larynx do occasionably penetrate deeply and expose the cartilage.

For instance, in a third case mentioned by Trousseau, the arytænoid cartilage was found exposed, though apparently not necrosed, at the base of a slight ulceration.

Dr. Hilton Fagge[1] relates a case of deeply penetrating ulcer of the larynx.

In another case, by Dr. Wilks,[2] the arytænoid cartilage was exposed beneath a slough.

Necrosis of the laryngeal cartilages complicating smallpox must be of the rarest occurrence, since it is not mentioned by Marson;[3] and Mr. Strugnall informs me that he cannot find a case in the clinical records of the Highgate Smallpox Hospital.

Curschmann, in 'Ziemssen's Encyclopædia,'[4] mentions it among the sequelæ of smallpox.

There is a precisely similar specimen[5] to that described in the museum of St. Bartholomew's Hospital. It was also taken from a patient who died with smallpox. *March*, 1880.

---

3. *Ulceration of the larynx due to congenital syphilis.*

By W. Allen Sturge, M.D.

Charles B—, æt. 3½, was brought to the Royal Free Hospital on August 12th, 1879, suffering from great dyspnœa, evidently due to some obstruction in the larynx or upper part of the trachea. The breathing was stridulous; inspiration and expiration equally difficult; the voice was a harsh whisper; the face flushed and cyanotic.

It was ascertained by subsequent inquiry that the father had contracted syphilis about two years before marriage, and had suffered severely from secondary symptoms, one of the manifestations having been a bad attack of laryngitis, which for three months

[1] 'Trans. of Path. Soc.,' vol. xxvii, p. 41.
[2] 'Trans. of Path. Soc.,' vol. xi, p. 14.
[3] 'Reynolds' System of Medicine.'
[4] Vol. ii, p, 38.
[5] Series xxv, No. 10.

prevented him from speaking louder than in a whisper. No history of syphilis in the mother could be ascertained. She had had four children, of whom two were still living. Of the others, one had died at the age of 18 months of inflammation and bronchitis; the other was born dead at the full term. She had never miscarried. The present child suffered badly from snuffles when a baby, and he had some sores about the body, for which he was prescribed a dark-coloured ointment, which was to be rubbed into the arm-pits at night. He apparently got quite well under this treatment, but when about 12 months old he had an attack in which he lost his voice for a short time. From this he recovered completely for a time, but six months later he again lost his voice, and had difficulty in breathing. He had never recovered from this condition.

The bridge of the child's nose was somewhat sunken, but there were no other signs of syphilis at the time of his admission to the Royal Free Hospital.

Inunction with Unguentum Hydrargyri was ordered, and it was especially directed that some of the ointment should be rubbed into the skin over the larynx and trachea.

Under the treatment the breathing became much easier. It was less noisy, and the mother said that he slept much more comfortably than before. Previously he frequently appeared at night to be choking, but this had become much less marked. She was bringing him up to the hospital on March 5th, 1880, when a violent gust of wind seemed to take away his breath, and though she carried him into a chemist's shop close by, he was dead before any assistance could be rendered.

Post-mortem.—The mucous membrane covering the left half of the epiglottis and the left arytæno-epiglottidean fold were much swollen, the swelling being sharply defined by the median line in front, and extending downwards to the rima glottidis. The true and false vocal chords on both sides were extensively ulcerated, the superior being more diseased on the left than the right side, the inferior more so on the right than the left side. The left inferior cord was much swollen as well as ulcerated.

Extensive ulcerations extended both upwards and downwards from the chords. The ulceration above the cords was apparently of older date than that below them; it was partly cicatrized, and had given rise to deep fissures in the mucous membrane, the fissures being symmetrical on the two sides. The ulceration below the

chords was more superficial, but at the same time more wide-spread than that above them. There were fewer evidences of cicatrization, but there were two moderately deep fissures opposite the cricoid cartilage, and just below this point there was a slight contraction of the upper end of the trachea.

Projecting from the ventricle, between the true and false chords on each side of the larynx, was a smooth, white, opaque membrane-like structure, which nearly filled up the ventricle. A section across one ventricle proved that these bodies were solid, and attached to the mucous membrane at the deepest part of the ventricle; they appeared to be outgrowths from the mucous membrane. There was no sign of inversion of the ventricles. The outgrowths, which were quite free from any connection with the vocal chords, passed from the posterior extremity of the ventricles to the anterior commissure of the larynx, across which they communicated with one another by a thin narrow band, which presented a small, regularly shaped projecting tongue of membrane at its central part. The outgrowths appeared to be the result of congenital malformation rather than of the disease which had caused the ulceration and cicatrisation of other parts of the mucous membrane. Their regular shape, bilateral symmetry, communication across the median line anteriorly by a firm, well-formed membrane, and the mode in which they were connected with the mucous membrane, all argued in favour of the former hypothesis.

April 10*th*, 1880.

---

4. *Two cases of congenital syphilis of the larynx.*

By Felix Semon, M.D.

I am in the very unusual position, much to my own regret, of laying before the Society two specimens of congenital syphilis of the larynx, removed within one fortnight from the bodies of two brothers, who, as they had shown during their short lives almost identical manifestations of the congenital affection, died within three weeks from each other from the same acute complication of the primary disease, viz. from acute laryngeal œdema.

The following is a short account of the clinical features and *post-mortem* appearances in their cases.

George T—, æt. 5¾, and Robert T—, æt. 3½, came under my care in the out-patient department in July, 1879. Their father, seven years and a half ago, suffered from a chancre and suppurating bubo, followed six months later by a secondary skin affection. He was treated by internal remedies, and no symptoms have since developed in his case. He married a year after the primary infection. His wife, who had been always healthy, had first a miscarriage at the third month, and subsequently suffered from condylomata, a coppery rash, and ulcers about the mouth. She recovered, however, completely under treatment in St. Thomas's Hospital. Eleven months after the abortion the elder of the two boys, who are the subjects of this communication, was born. A few days after his birth large condylomata were observed about the anus, and at the end of the first month he became the subject of syphilitic coryza and of shortness of breath, from which he always has suffered since. The mother then again aborted at the fifth month. A year and a half later the younger boy, whose larynx is also before the Society, was born. He showed very similar symptoms to the elder one, only in a somewhat milder form, but with the addition of a coppery rash. Since then a full-time stillborn child, and a child who only lived three days with symptoms of dyspnœa, and died with aggravation of these, have appeared, and finally, eight months ago a full-time child was born, who is at the present time healthy. This completes the family history.

The boys were brought to me suffering from hoarseness and marked stridulous breathing, which, however, apparently did not trouble them much. They were both fairly healthy looking and well developed for their respective ages. On examination there was in both cases evidence of syphilitic coryza, the septum narium especially being much eroded and showing several small ulcers covered with ichorous pus; excoriations were also visible (especially in the older boy) between the nostrils and the upper lip. In both cases the mucous membrane of the lips, hard and soft palates, and posterior wall of the pharynx, presented irregular ulcerations with clean cut edges, which bled easily on being touched, and there were numerous fissures on the tongues. The uvula of the older boy was thickened and congested.

Laryngoscopic examination was in both cases exceedingly diffi-

cult, owing to the state of the parts and to the restlessness of the little patients, and I may state, that I only once succeeded in getting a satisfactory view of the visible parts in either case. In the case of the elder boy, George, the epiglottis appeared as a mass made up of two sausage-like bodies, applied closely to each other, grey in colour, semitransparent, and tense, and here and there superficially ulcerated. As the arytæno-epiglottidean folds also showed a similar change, the view *into* the larynx was completely obstructed. Only this much was made out, that the upper aperture of the larynx was narrowed to an extreme degree. Thus this stenosis accounted satisfactorily for the stridor, but at the same time no satisfactory explanation could be arrived at for the strangely deep, rough, and hoarse voice of the child, on account of the impossibility of examining the lower parts of the larynx. The laryngoscopic appearances in the case of the second child were very much like those described in his brothers' case; the epiglottis was similarly curled up, though not so thick as in the first case; the arytæno-epiglottidean, and especially the inter-arytænoid folds, were much swollen; the view *into* the larynx completely obstructed.

In the first case a slight increase in the liver dulness and some redness about the anus were noticed as the only bodily symptoms; in both cases percussion was normal over the chest; the results of auscultation could not be made use of, the noisy laryngeal stridor being conveyed to the upper parts of the lungs and completely masking the breath sounds.

In the second case there was marked swelling of the cervical lymphatic glands, and several round ulcers coming and going on the forearms.

The treatment consisted in the use of mercury and iodide of potassium, with immediate improvement of almost all the symptoms in both cases; but the person who brought the children was very irregular in her attendance. I could not get to see the mother or father, nor were they told (as I afterwards made out) of my wish to take the boys into the hospital, where I could have used more regular and efficient treatment. Thus, changes for the better and for the worse followed each other constantly. I saw the children on the 10th of November, 1879, when not much change was to be noticed; on the 16th of December, when I saw them next, my notes say that the elder boy was much better, the stridor being much diminished; but it was impossible to make a good laryngo-

scopic investigation. On the 5th of January, when the elder boy alone was brought and seen for the *next* and *last* time, the stridor was worse, but not alarming; the iodide was increased to five grains three times a day, and the Liq. Hydrarg. to six minims. I have since been told by the parents, that on the 7th he was worse, on the 8th there was increased dyspnœa; on the 9th a doctor was called in, who said the child was suffering from bronchitis and was evidently sinking, and on the morning of the 10th the boy died with symptoms of dyspnœa.

With much difficulty I got leave to remove the larynx, but a thorough examination of the body was refused. The specimen is on the table before you, and the following is a short description of it:

The tongue is fissured, and there are numerous small ulcers at its base and on the glosso-epiglottidean ligaments. The epiglottis is curled up in the way described above.

The entire larynx shows a general *hyperplastic* change, and is at the same time superficially ulcerated, especially its anterior wall.

The hyperplastic change is especially marked in the epiglottis, the arytæno-epiglottidean folds, and in the inter-arytænoid fold. There is at the same time acute œdema of the epiglottis and arytæno-epiglottidean folds.

In consequence, therefore, of the chronic thickening and of the acute œdema, the opening into the larynx is so narrowed as scarcely to admit the tip of a lead pencil.

The vocal cords and ventricular bands especially are destroyed by ragged ulcerations.

The trachea shows small superficial fresh ulcers and numerous scars of old ones, but no stricture.

The diagnosis I offer in this case is: *Congenital hyperplastic syphilis of the larynx, with acute œdema of the epiglottis and arytæno-epiglottidean folds.*

It was only after the death of this boy that I could get the parents to realise the serious nature of the affection in the younger boy. He was brought to my house by his mother on Monday, January 24th, when his state seemed to be much the same as on December 16th, when I had last seen him. A regular inunction treatment, after Zeissl's plan, was instituted, and minute written instructions were given as to its management. He was to see me again on Monday, February 2nd. On Friday night, however, the

father came to fetch me, as the boy had shown on the previous evening almost the same symptoms of dyspnœa as his late brother, only both more severe and more rapidly increasing. When I arrived at the house I found the boy with considerable dyspnœa. There was loud stridor, the face was flushed, the lips slightly cyanotic, pulse and respiration much hurried, the chest-walls and the epigastrium much drawn inwards. The child was at once removed to the hospital, and crico-tracheotomy performed, but it sank immediately after the operation, in spite of long-continued efforts at artificial respiration.

As in the former case, I was only permitted to take out the larynx, which was done shortly after death. The specimen is an interesting variation of the first; whilst in the former the obstruction concerned nearly exclusively the *upper aperture* of the larynx, in this instance the *middle compartment* of the larynx is pre-eminently occluded. I have cut the crico-thyroid membrane horizontally on both sides, but not opened the middle compartment at all, in order to show the parts *in sitû*. It will be seen that the lumen of the larynx is completely occluded between the ventricular bands above and the lower edge of the thyroid cartilage below, in onsequence of intense acute œdematous infiltration of the ventricular bands, vocal chords, and internal thyro-arytænoid muscles, and still more of the inter-arytænoid folds. The arytæno-epiglottidean folds are less infiltrated, and the epiglottis itself has nearly entirely escaped. Besides, there is marked œdema of the posterior wall of the cricoid cartilage. In this case, as well as in the former, there are numerous shallow ulcerations of the mucous membrane in the interior of the larynx, but on the whole the *chronic* changes are much less, the *acute* ones much more developed than in the former.

Diagnosis.—Congenital ulcerative syphilitic laryngitis, with some hyperplasia and intense acute œdema of the inter-arytænoid fold, ventricular bands, vocal chords, and internal crico-arytænoid muscles.

Remarks.—The interest of these cases seems to lie in the following facts:

1. *Deep* lesions of the larynx in cases of congenital syphilis are very rare, though a simple laryngeal catarrh frequently accompanies congenital syphilis. Rauchfuss says, in his excellent treatise on 'Congenital Syphilis of the Larynx and Trachea,'[1] that, on the whole, observations on the effects of congenital syphilis in the

[1] Gerhardt, 'Handbuch der Kinderkrankheiten,' vo l. iii, zweite Auflage, p. 252.

larynx and trachea are yet too few to warrant us in drawing any definite conclusions. As his very complete references extend down to 1878, I think these cases are worthy of record.

2. The interest of these cases is certainly enhanced by the fact that, deeper laryngeal affections in congenital syphilis being evidently so rare, in this family two certainly, if not three, children suffered and perished from this rare form of manifestation of the disease.

3. The most important feature, however, seems to be the fact of the congenital syphilis manifesting itself (especially in the case of the older boy) in the form of *hyperplasia*. As a rule, deeper syphilitic lesions of the larynx occur either in the form of *extensive* ulceration, with subsequent cicatrization and stenosis, or in the form of *deep* ulceration with following perichondritis, caries and necrosis of the cartilages, or finally, in the form of gummatous deposits. The hyperplastic thickening, however, seen especially in the case of the older boy, is rare in adults, and not yet described to my knowledge in the case of children.

4. Acute œdema as a complication of syphilis of the larynx is by no means rare, but it is certainly remarkable that this affection should have occasioned in this instance the death of both the children within so short a time. Whether the general domestic and sanitary arrangements played any part in the production of this complication, I am unable to say.

5. Although I cannot establish the absence of an acute bronchitis, as pronounced in the first case, yet I think that a single look at this specimen shows that the child's death was due to this œdema. Possibly in this instance tracheotomy at the onset of the acute symptoms might have saved the child's life.

February 3rd, 1880.

---

5. *Laryngitis in congenital syphilis.*

By Thomas Barlow, M.D.

This specimen showed, when fresh, the following characters:—Some œdema of the arytæno-epiglottidean folds, slight erosion of the mucous membrane of the larynx above the false chords and

below the true chords, finally, some scanty, thin, closely adherent laminæ of false membrane in the ventricles and below the true chords.

Other lesions found were a greatly enlarged spleen, showing thickening of capsule, and under the microscope somewhat enlarged Malpighian bodies, which in the centre had undergone fibroid transformation; an enlarged liver with extensive interlobular infiltration of fibro-nuclear growth; an enlarged heart with some thickening of the endocardium and fibroid change in the walls, but no gumma and no valvular disease.

The specimen was taken from a female child, who was eleven months old when she died, and whom I had had under observation at various intervals from when she was four months old. The child was brought as a living specimen to the Society in January, 1877, on account of her spleen and heart, and a note of her case will be found in vol. xxviii, p. 353, of the 'Transactions.' I will refer now to her laryngeal symptoms. It was first noticed that her voice was altered when she was five months old. It was simply rather weak and hoarse, and this was most manifest when she cried. She had at times a rather hoarse cough, but she had never, when I saw her, any recession of chest walls or laryngeal dyspnœa. Her laryngeal condition varied a great deal. On one or two occasions I have a note that the child cried well, but she kept getting relapses, perhaps catarrhal, which made her repeatedly hoarse. Mercury appeared to do her more good than iodide of potassium, but she never fairly got over her cachexia.

She lived at Enfield, and had not been brought for several weeks, when one day her mother came to inform me that the child had died suddenly, after three or four days' illness, with difficulty of breathing.

I presume, from the history and the specimen, that the child's death was due to the supervention of membranous inflammation (whether diphtheritic or not I cannot tell) upon a chronic laryngitis. It ought to be mentioned that there were was no implication of the pharynx and no enlargement of glands.

Remarks.—I have brought this specimen (which has been in my possession more than two years) as a rider to Dr. Semon's cases shown a few weeks ago, and in which the changes were more extensive and better marked than in this. I do not think this disease is so rare as the scanty reference to it in the medical literature to

which Dr. Semon referred might lead one to suppose. This is the only specimen which I have obtained *post mortem*, but I think the following clinical sequence is not uncommon:—Amongst the early manifestations in extreme cases of inherited syphilis a weak cry is very frequent. As the child recovers, this symptom may quite disappear, but in a certain number of cases the voice remains altered in quality for several months. Sometimes, although the child is nearly well in other respects, he is almost voiceless. The dyspnœa may be slight in amount, or *nil*, but there is a liability to sudden attacks in which tracheotomy seems almost indicated, but where steam and mercurial inunction will effect wonders if promptly and effectively applied. The cases which I have seen have been too young for laryngoscopy, but I presume that there may be such a condition as existed in the present instance, viz.—a chronic smouldering laryngitis, or at least an unstable damaged mucous membrane, ready to inflame and swell on the slightest provocation, and perhaps easily receptive of diphtheritic poison; or otherwise stated, prone to take on membranous inflammation.

I may mention that in the last edition of Bumstead's book on 'Syphilis', edited by Dr. Taylor, there are references to hitherto unpublished cases of congenital syphilis of the larynx, and that an American physician, Dr. John Mackenzie, has informed me of his possessing notes of a large number of cases of congenital syphilis in which, during life, he had been able to establish the existence of extensive changes in the larynx. *April 6th*, 1880.

---

6. *Atelectasis of lungs with emphysematous cyst; congenital heart disease.*

By Thomas Barlow, M.D.

Lilian W—, a female child, æt. 3 months, was brought to the Children's Hospital, Great Ormond Street, in July, 1879.

Her parents were both weakly. She was the only child. The mother said she had cried well at her birth, and nothing special had been noticed about her then. She was brought because she did not make flesh, and had a cough.

When seen the breathing was not at all laboured; there was no wheezing and no blueness. The chest was rounded in front and symmetrical, with a little drawing in at the ensiform and below it.

Nothing remarkable was heard on auscultiing the lungs, but the heart sounds were found much more audible on the right than on the left side of the sternum, and some impulse was felt to the right, whilst there was none to the left, and the cardiac dulness was somewhat masked to the left.

The liver was evidently on the right side, and for this reason it was considered that the situation of the heart was not due to transposition of viscera, but to some contraction of lung. The child was small and feeble, and died in ten days after it was brought.

At the *post-mortem* examination it was found that the heart lay mostly to the right of the middle line, and that the right lung and the lower lobe of the left lung were in a state of atelectasis.

Occupying most of the space exposed by the usual incision through the costal cartilages on the two sides was the greater part of the left upper lobe, which was emphysematous to an extreme degree. The tongue-like process at the anterior base of the left upper lobe was, however, collapsed. Just above this process, and corresponding with the anterior axillary line, was a cyst, as big as a Spanish chestnut. It contained air, and had a smooth continuous lining throughout, without any trabeculæ. The peripheral part of the wall of the cyst, although exceedingly thin, was found to be composed of condensed lung alveoli. Thus, the cyst was quite unlike a large subpleural emphysematous bulla. To the naked eye it was, indeed, much like a retention cyst in a glandular organ.

No communication with bronchi could be detected.

From the extreme smoothness of the wall and the absence of any inflammatory material—although, I presume, formed after birth—this cyst must have taken its rise at a very early period in the infant's life.

The heart was bifid at the apex, the conus arteriosus unduly large, and the ductus arteriosus quite patent. The abdominal viscera were natural. *December* 16*th*, 1879.

---

7. *Two cases of complete excavation of one lung, with death in one case from exhaustion; in the other from rupture of an aneurysm of the pulmonary artery.*

By Samuel West, M.B.

Alfred S—, æt. 39, was admitted "urgent" into the Chest Hospital, Victoria Park, on the supposition that he had localised pyopneumothorax. On account of the dyspnœa paracentesis was performed, with the evacuation of about eight ounces of pus and much air, to his temporary relief.

The physical signs remained as they were, the side being contracted, slightly tympanitic to percussion; vocal vibrations and vocal resonance not increased; amphoric breathing over whole side, with the bell sound on percussion with coins.

The patient was tapped two or three times, and ultimately a valvular trocar was inserted, with the view of giving permanent relief; but the patient died of exhaustion a few days later.

Post mortem.—Body anæmic, though not much emaciated; slight œdema of both ankles and left hand.

Right lung.—Considerably emphysematous, encroaching on left mediastinum, at base much congested, and in part granular and airless. On section, due to patch of recent pneumonia.

One or two hard nodules scattered throughout the upper lobe, firm, yellow, and dry. At apex a long pear-shaped cavity with thick walls, and lined by what appears to be a pyogenic membrane. This cavity is clearly stationary. Several nodules, over which the pleura is retracted, scattered throughout the lobe. The tissue is firm, pigmented, and containing, here and there, small yellow nodules, which would have been called healed tubercles.

Left lung.—The pericardium drawn over to the left side; the pleura universally adherent and much thickened, forming the dense walls of what is really one large cavity, formed by the excavation of the whole lung. A few coarse trabeculæ only are left to mark the division between the lobes and the remains of the large vessels, &c. Most of the bronchi are completely obliterated, but some of the larger bronchi communicated with the cavity by small orifices.

The puncture made led, of course, directly into the cavity.

Liver, spleen, and kidneys congested.

The pericardium contains about two ounces of clear serous fluid; the whole posterior and left surface is considerably roughened by recent inflammatory exudation, which in places forms easily broken-down adhesions; the inflammation is less marked in front over the right ventricle and to right side. Scattered over both layers of pericardium are punctate hæmorrhages, most numerous where inflammation is most intense, and behind, the largest being posteriorly over the pulmonary artery.

The pericarditis is evidently due to the spreading of inflammation from the left pleura.

Case 2.—John H—, æt. 38, was admitted into the Chest Hospital, at Victoria Park, for cough and dyspnœa. He dated his illness from two years back, when he was attacked by cough, shortness of breath, and pains in the chest; never laid up entirely at any time. The cough had been worst during the winter, when he had had a little streaky hæmoptysis. Had lost flesh a little lately, but had never suffered from sleep sweats. His father and two brothers died from phthisis, and one brother was living, but was weak at the chest.

Physical examination showed slight contraction of the left side, which was impaired to percussion; the vocal vibrations were absent in front and at the side, but feebly felt behind. Amphoric resonance at the apex on coughing, and bell-sound here with coins.

After he had been in the hospital five weeks, and had improved considerably, he was suddenly seized with hæmoptysis, and expectorated about a pint of blood daily for six days, and on the seventh had a fresh and more profuse attack, in which he died suddenly.

Post mortem.—Thin, but not emaciated; rigor mortis well marked; left side contracted; pericardium displaced to left.

Right lung extends (opposite fourth rib) nearly two inches to left of middle line of sternum.

Lung considerably emphysematous and œdematous, but beyond one or two small nodules here and there, probably around the bronchi, no change noticeable.

Left pleural cavity completely obliterated, the two layers united, forming the thick wall of one large cavity produced by the complete excavation of the whole of one lung, a few coarse ridges only remaining over the course of the great vessels at the root of the lung.

Upon the largest of one of these ridges is a hemispherical egg-cup-like swelling, about the size of half a cherry (half an inch in diameter). On looking into it a longitudinal slit, about three eighths of an inch long, is seen. This is an opening leading directly into one of the main branches of the pulmonary artery. The other half of this aneurysm has been torn away by the force of the blood, and can only be traced by some irregular remains upon the distal portions of the artery. The division of the aneurism is as sharp as if it had been cut with a knife.

The walls of the cavity present the ordinary appearance of a chronic pulmonary cavity. No other changes of importance in the other viscera.

Cavities of large size in the lungs are not altogether rare, but they do not commonly extend beyond the confines of one lobe; it may be the upper, which is the more usual seat, I believe, or the lower. Such excavation as is seen in the two preparations exhibited is of the greatest rarity; so much so, that in many works on phthisis no mention is even made of them. There are no recorded cases of the kind in the 'Transactions' of this Society, nor is there any descriptions of such preparations in the 'Catalogue of the Museum of the Royal College of Surgeons.' The only account of a similar case, I have succeeded in finding, is in Rokitansky's 'Pathology' (vol. iii, p. 95). The preparation was taken from a woman, æt. 32. The excavation had involved the upper lobe and part of the lower lobe, death resulting from rupture of an aneurysm of the pulmonary artery, a piece of which was completely torn away, as in the second of these cases.

I have also at the present time under my care a patient in whom, I believe, from the physical signs, the same condition of parts exists.

The feature of these cases which is clinically of the greatest interest and importance is that these large excavations are so often latent, the patients being themselves frequently quite unaware that they are suffering from any marked disease of the chest, making no complaint beyond, it may be, of slight winter cough and expectoration, and presenting none of the ordinary constitutional signs of phthisis; nor is it possible frequently to get any history of illness from them or their friends. Further, the other lung is often found on *post-mortem* examination healthy, or presenting but trifling evidence of disease. All these are facts which would seem to place

such cases of large excavation of the lung in a class by themselves, and separate them sharply from the ordinary forms of phthisis.

May 4th, 1880.

---

8. *Blood-casts of the bronchi.*

By Samuel West, M.B.

The specimens I bring before the Society to-night are of considerable pathological interest and rarity. They are blood-casts, or casts of bronchial tubes in coagulated blood, not taken from the lungs *post-mortem*, but expectorated by a patient who is still living, more than twelve months after the hæmoptysis which produced them.

The patient was a man, æt. 43, a beer bottler, who came to the City of London Hospital for Diseases of the Chest, complaining of shortness of breath and pain in his left side. He stated that for the last four months he had been losing flesh, and had occasionally, after coughing, suffered with streaky hæmoptysis. Beyond this he had been healthy, with the exception of a winter cough for the last four or five years. He was one of six children, all of whom were healthy, but his father, he said, had died of a "broken blood-vessel."

Examination of his chest showed some slight consolidation at the left apex, with some softening. For two months he went on fairly well, but was then attacked by severe hæmoptysis, and on examination I found that while the apex signs remained the same the base of that side had become dull, with fine crepitation and feeble respiration. I thought that the hæmorrhage had come from the apex, and that the new dulness at the base was due to the accumulation of blood which had gravitated there. The hæmorrhage ceased, and in a short time the base had completely recovered itself. Two months later he was seized with a similar attack of hæmoptysis, and he brought me some "lumps," which he said he had expectorated with great difficulty, though with considerable relief to his dyspnœa. Two days later he brought me some more, and it is these "lumps" which I place now before the Society.

He was admitted into the hospital, and found to have again the

same dulness at the left base, while the apex signs remained much as before. He rapidly improved, and this dulness again cleared up.

On my last examination of him, about six months after his hæmoptysis, I found a slight increase of the apex mischief, but the base was completely healthy. This is of interest, as bearing upon the question of phthisis ex hæmoptoe.

Of the four casts shown three are nearly the same in size, about two inches long and a quarter of an inch in diameter at the thickest part of the stem. Two of these are much branched; the fourth cast is very much larger, being of the size and shape of a little finger, one and a half inches long and half-an-inch in diameter; this is not branched.

Both naked-eye and microscopical examination alike showed these casts to consist of nothing but blood-coagulum.

In writing on the subject of bronchial casts[1] Drs. Cheyne and Michaelis speak of two kinds: the one croupous or fibrinous, of inflammatory origin, such as are common in plastic bronchitis, and of which many specimens have been brought before the Society; the other, blood-casts, non-inflammatory, due to the coagulation of blood in the bronchial tubes. These are rare, and I have not been able to find any specimens of the kind recorded as exhibited in the Society's 'Transactions.' Indeed, Dr. Peacock, in his *résumé* of this question, in the fifth volume, denies their existence, and states that, in his opinion, there is but one kind, fibrinous, due always to inflammation, and that where casts look like blood-clot this is due to the staining of the fibrinous casts by imbibition. Dr. Cheyne, on the other kind, speaks confidently of the existence of true blood-casts just as my specimen shows, though he affirms that they are rare, and usually the precursor of fatal hæmoptysis.[2] In illustration, he quotes the case of a man who was attacked by severe dyspnœa after hæmoptysis and expectorated a blood-clot with great relief. The next day he expectorated a similar clot, but died very soon afterwards from uncontrollable hæmoptysis.

This case is of interest, not only on account of the nature of the cast expectorated, but from the fact that the patient is still living, more than twelve months from the date of his hæmoptysis.

February 17th, 1880.

[1] Cheyne, 'Pathology of the Membrane of the Larynx and Bronchi,' 1809.

[2] 'London Medical Record,' 1785.

9. *Epithelioma of the larynx, leading to secondary deposits in the neighbouring lymphatic glands, and to secondary chondritis and perichondritis of the left wing of the thyroid cartilage.* (*Card specimen.*)[1]

Exhibited by FELIX SEMON, M.D.

TONGUE and œsophagus quite healthy. Epiglottis healthy in the upper part, but below the cushion cancerous ulceration and thickening is seen. The larynx on its anterior surface presents a ragged ulcer as large as a sixpence; at its base is an opening leading, by a fistulous communication through the substance of the left half of the thyroid cartilage upwards into the left pharyngo-laryngeal sinus; on the other hand, there is no communication between the ulcer and the interior of the larynx proper. The interior of the larynx showed in the fresh specimen, from the cushion of the epiglottis downwards into the trachea, a dark greenish discoloration, and was filled with green stinking pus. The entire left lateral ala of the thyroid cartilage shows extensive cancerous change, the mucous membrane is universally ulcerated, and the entire thickness of the cartilage is increased in consequence of a secondary perichondritic process; the result is, that the lumen of the larynx is a good deal narrowed. The left vocal cord and ventricular band have been completely eaten away by the ulcerative process, while the left arytænoid cartilage is thickened and partially ulcerated. Just above the last-named cartilage there is a large, well-defined cancerous nodule, dipping over the edge of the endolaryngeal framework and involving the pharyngeal surface. The mucous membrane of the right half of the larynx is much swollen, but the ulceration has only extended to the anterior third of the right vocal cord and ventricular band. Microscopically a fragment of the growth shows a fibroid stroma, enclosing nests, which contain numerous large round and oval cells with one or two nuclei.

Remarks.—The specimen was removed from the body of a man, æt. 52. The disease had lasted only twelve months altogether. The first symptoms were pain in the interior of the larynx, spreading towards both ears, especially towards the left, and gradual but

[1] By a recent regulation of the Society, specimens may, in order to save time at the meetings, be exhibited if desired, without oral communication, but with a short written description on a card. Such specimens are placed on a table in the meeting-room for the inspection of members, and are, equally with others, subject to criticism and discussion. In order to distinguish them they are here printed in somewhat closer type, and the words (card specimen) appended.

increasing loss of voice. Five months later a tumour was noticed just in front of the neck, which, quickly increasing, extended above to the crico-thyroid ligament, and below reached nearly to the supra-sternal notch. *One* month later a *second* tumour appeared on the left side of the neck, in front of the trapezius muscle, which increased at first quickly to the size of a walnut, and then remained stationary. Both tumours were tender and painful. Two months later the first formed tumour broke and quickly resulted in an ulcer as large as half a crown, and discharging an ichorous pus. At the same time quickly increasing dyspnœa, pain and difficulty in swallowing, especially of *fluid* substances, and general cachexia followed.

The patient now applied to the hospital, when, besides the tumours mentioned and appearances above described, it was noticed *that the cervical lymphatic glands on both sides were much enlarged.* The laryngoscopic appearances were—(1) Epiglottis healthy looking; (2) entire posterior wall of larynx, especially on the left side, much swollen and ulcerated; (3) left arytænoid cartilage changed into an irregular tumour and superficially ulcerated; (4) left vocal cord and ventricular band hardly to be distinguished; (5) anterior commissure and anterior third of right vocal cord also much ulcerated and disfigured; (6) the whole of the interior of a dirty yellowish-grey colour and constantly filled with a white, glazy phlegm; (7) the lumen of the larynx much reduced.

Extirpation of the larynx was at first contemplated, on account of the increasing dyspnœa and of the impossibility of performing tracheotomy, owing to the position of the tumour in front of the trachea. The idea was however soon given up, on account of the secondary changes already present in the glands, and especially because from a certain time (about one month after the patient came under observation) the difficulty of breathing did not increase, but remained stationary. The patient died, exactly twelve months after the commencement of his disease, from exhaustion.

The case is put on record:

1. On account of the comparative rarity of endolaryngeal cancer in general.

2. On account of the unusually early secondary implication of the neighbouring lymphatic glands. Most likely this was due to the fact, that the growth on the left side spread soon beyond the cartilaginous framework, and thus the opportunity for infection of the glands was given to the pharyngeal lymphatics at an unusually early period.

3. In spite of the almost certain early recurrence indicated by the infection already present, extirpation of the larynx might have become necessary in this case to save the patient from imminent suffocation, had the dyspnœa advanced *pari passû* with the cachexia.

February 17th, 1880.

10. *Old syphilitic scars in the larynx, trachea, and bronchi; stricture of the bronchi, leading to chronic disease in the lungs.* (*Card specimen.*)

Exhibited by Wm. Ewart, M.B.

The patient, a married woman, æt. 38, had suffered from a cutaneous eruption in her childhood and presented scars of apparently rupial origin. She had been submitted, at the age of seventeen, to the operation of laryngotomy, for the relief of laryngitis. For many years previous to her death she had suffered from chronic bronchitis. She was admitted into St. George's Hospital, with cough and dyspnœa, and she gradually sank under the combined influence of renal and of pulmonary disease.

After death, additional evidence of syphilis was found in the existence of old cicatrices of the liver, of lardaceous disease of the spleen, and of atheroma of the vessels.

The specimen shows nearly total destruction of the epiglottis, considerable scarring of the larynx [where a permanent aërial fistula has remained], a longitudinal scar, beginning an inch below the larynx and extending into the left bronchus, and several smaller scars in both bronchi, occurring chiefly at their divisions. The orifice of the left bronchus was reduced to the size of a goose-quill. Below this chief constriction the calibre of the bronchus was very uneven; there was also some unevenness in the calibre of the right bronchus. The secondary changes in the lung were most marked on the left side. The left lung was reduced to half its normal size; the pulmonary tissue was coarse in aspect and tough. The divisions of the bronchi were greatly thickened and surrounded with a zone of condensed and pigmented lung tissue. In addition, the lower lobe was sodden and much softened, and could not be detached entire from its pleural connections.

February 3rd, 1880.

III. DISEASES, ETC., OF THE ORGANS OF CIRCULATION.

1. *Case of malformation of the heart, with transposition of the aorta and pulmonary artery.*

By David B. Lees, M.A., M.D.

The heart now exhibited to the Society was taken from a male infant, seven months old, who was under my care at the Hospital for Sick Children, Great Ormond Street, during the last four months of his life. The child had suffered from cyanosis and shortness of breath ever since its birth. When I first saw it I found it intensely cyanosed in the head and upper limbs, decidedly less so in the trunk and lower limbs. There was, however, not the least trace of clubbing; the fingers tapered quite naturally. The heart was evidently large, and it was beating rapidly (168 in the minute); the second sound at the base was accentuated, but there was no bruit whatever. The chest in general was hyper-resonant, even down to the bases of the lungs posteriorly.

This condition continued for two months. When he was five months old a bruit became developed. It was systolic, and was best heard at the left base of the heart and towards the left clavicle, also behind in the upper interscapular region. Before the child's death, however, it became much less audible, and at times seemed to have vanished.

At the autopsy it was found that two parallel vessels arose from the base of the heart. The vessel on the right side was connected with the right ventricle, and proved to be the aorta; it gave off the coronary arteries, and, passing upwards, gave origin normally to the innominate, left carotid, and left subclavian. It then became narrowed, and joined the ductus arteriosus to form the descending aorta. The vessel on the left side, taking origin from the left ventricle, was the pulmonary artery. It was considerably larger than the aorta. It divided normally into the two branches for the lungs,

and gave off a patent ductus arteriosus. Judging from the size of the pulmonary artery and from the contraction of the aorta, it would seem that the two vessels had contributed about equally to the supply of the descending aorta. The right auricle received the systemic veins, whilst the pulmonary veins were emptied into the left auricle. The foramen ovale was practically closed, only a very small oblique opening remaining. There was a considerable deficiency in the septum of the ventricles, and the pulmonary artery was so placed that its entrance was above this opening; it had no doubt received blood from both ventricles. The right ventricle was hypertrophied, its walls being as thick as those of the left. The various valves were normally formed and placed, only the mitral showed some slight but distinct thickenings. The effect on the circulation must have been that the head and upper limbs received only venous blood, whilst the trunk and lower limbs received blood partly arterialised. The pulmonary artery and veins must have contained almost wholly arterial blood. This peculiar circulation seems to account for the distribution of the cyanosis, and also for the dyspnœa, the respiratory centre in the medulla oblongata being furnished with none but venous blood. As to the etiology of the case, the mother stated that when about six weeks pregnant she was bathing at Hastings with three other women, when two of them suddenly sank, and were rescued with great difficulty. She was much frightened, and was ill the same day with repeated vomiting, followed by diarrhœa. Whether this be considered in any way causal of the child's condition or not, it seems, at all events, certain that a strong impression was made on the abdominal ganglia of the mother at the time of the formation of the septa of the heart, which embryologists assign as the sixth, seventh, and eighth weeks.

This case seems to throw light on the debated question of the causation of cyanosis. It was at one time the received opinion that cyanosis was due to the intermixture of venous and arterial blood, owing to abnormal communications between the two sides of the heart. Stillé, however, showed—1st, that cyanosis may exist without the intermixture of the currents of blood; 2ndly, that there is no just proportion between the intensity of the cyanosis and the amount of venous blood which enters the systemic vessels; 3rdly, that complete intermixture may take place without cyanosis being produced; and, 4thly, that the variations in the extent, depth, and duration of the discoloration are inexplicable by the doctrine of the

intermixture of the currents. He therefore falls back upon the theory that cyanosis is due to congestion of the venous system, and points out that in fifty-three cases out of sixty-two there was obstruction or contraction of the pulmonary artery.

Dr. Peacock, in his well-known work on malformations of the heart, after a careful discussion of the causation of cyanosis comes to the same conclusion. He points out, on the one hand, that cyanosis may occur without any communication between the two sides of the heart, instancing especially the case of a cyanotic girl in whom there was an abnormal partition in the right ventricle without any other malformation, and, on the other hand, that abnormal communications are often found, and those not merely narrow, but widely open, in cases where there has been no cyanosis. Especially remarkable are cases such as that of Valleix, where the septum of the ventricles was so rudimentary that a complete mixture of the two blood-currents must have occurred.

These observations appear to be decisive against the theory that cyanosis is pathognomonic of the existence of abnormal openings in the heart.

Are we, therefore, obliged to fall back, as Stillé and Peacock have done, on the theory of venous congestion? The heart now exhibited seems to be an answer to this question. In this case, though there was intense cyanosis, there can have been no venous congestion. The systemic blood was returned to the right auricle and passed through a normal auriculo-ventricular opening into a well-formed and rather hypertrophied right ventricle. From this it had two means of exit, an aorta as large as an ordinary pulmonary artery, and quite unobstructed, and in addition a wide opening in the septum, which admitted it to probably quite one third of a pulmonary artery as large as an ordinary aorta. The lungs also were fully expanded. There can, therefore, have been no venous congestion, and a proof of this is found in the fact that there was an entire absence of clubbing.

Hence in this case the venous congestion theory breaks down.

Is there no third theory which will account for all the cases?

I would suggest that cyanosis simply means deficient aëration of blood, and that the amount of cyanosis is a measure of the amount to which aëration of the blood has been hindered? This is by no means the abnormal communication theory in another form, for one may easily understand that even a considerable intermixture of

venous with arterial blood would reveal its presence if the whole mass of the blood were fairly aërated, or would only cause slight occasional lividity when other difficulties to the circulation arose, as has been the case in several recorded instances of widely patent openings, &c., rudimentary septa. On the other hand, in such cases as the one before us the circulation is perfectly free, but aëration must have been very badly performed. The blood supplied to the head and upper limbs had not passed through the lungs at all, and some of that which passed from the right ventricle into the pulmonary artery, and by the ductus arteriosus into the descending aorta, must have been in the same condition.

Meantime, the aërated blood from the lungs was poured back into the left auricle, and thence into the left ventricle, to pass mainly into the branches of the pulmonary artery once more, being thus chased continually through the pulmonary circulation without much chance of improving by its admixture the general mass of the blood.

This same theory, a deficiency in aëration, will I think explain all cases of cyanosis. It will obviously explain all the cases in which there has been contracted or obstructed pulmonary artery or obstruction in the right ventricle, without abnormal communications, that is to say, the cases which the venous congestion theory was invented to explain. It is not the venous congestion pure and simple, but the congestion of non-aërated blood, that will account for them.

An objection might be brought that on this theory cyanosis should exist in the cases of stenosis of the pulmonary valves in adults, but its occasional absence here is explained by the compensatory hypertrophy of the right ventricle.

This theory, I repeat, is not the intermixture theory in another form; indeed, in one point of view, it is quite opposed to it, for, in such a case as the present, to increase intermixture of blood would have been to improve the aëration of the whole mass, and hence to diminish the cyanosis. That the complete intermixture takes place in a single ventricle will matter comparatively little if each individual blood-corpuscle has its turn of oxidation.

Out of Dr. Peacock's twenty-five cases there are only four in which cyanosis was not present. One of these was a case of stenosed pulmonary valves in an adult, which may not have been congenital. Of the three others, one was a case of patent foramen ovale without other defect; the second had contraction of the aorta with patent

ductus arteriosus; whilst in the third both auricles opened into a single ventricle, which supplied the pulmonary artery (the aorta springing from an atrophied right ventricle).

In all these cases there can have been no obstacle to aëration, and, accordingly, there was no cyanosis.

In one case of Dr. Peacock's the presence or absence of cyanosis is not stated. All his other cases, twenty in number, were cyanotic, and in all of them there was some obstructive condition, either of the pulmonary artery or of the right ventricle; hence in all there must have been imperfect aëration.

These cases, therefore, completely support the theory above advanced.

Clubbing of the fingers and toes is another symptom on which this case throws light. There was an entire absence of clubbing, although the cyanosis was intense. Is it not reasonable to connect this fact with the absence of congestion of the venous system?

To test this I have again analysed Dr. Peacock's twenty-five cases. In fourteen of the twenty-five the question of clubbing is not referred to. Out of the remaining eleven, seven are said to have been decidedly clubbed, three slightly clubbed, and one probably not clubbed. In all the eleven there was obstruction on the right side of the heart; but whereas in all the seven clubbed cases the foramen ovale was closed, in all the four cases slightly or not at all clubbed the foramen ovale was open. This seems to indicate pretty clearly that the clubbing is due to congestion of the systemic veins in cases where the foramen ovale is closed, but that where that passage is open the congestion is so much relieved that clubbing does not result.

I will only add a reference, by way of confirmation, to Dr. Pye-Smith's case of "Transposition of the Aorta and Pulmonary Artery," recorded in a previous volume of the 'Transactions,' (vol. xxiii, p. 80), which much resembles my case, and in which also there was cyanosis, but no clubbing, and to one reported by Dr. Crocker last year, in which, again, there was cyanosis without clubbing, and in which there was found tricuspid atresia, but the foramen ovale was widely open.

I submit that it is thus fairly demonstrated that cyanosis is due to defective aëration, and that clubbing is due to systemic venous congestion.

January 20th, 1880.

DESCRIPTION OF PLATE I.

Plate I illustrates Dr. Stephen Mackenzie's Two Cases of Congenital Malformation of the Heart. (Page 63.)

FIG. 1.—Case 1:

a. Pulmonary artery.

b. Probe in supernumerary (right) ventricle, projecting from imperfect septum between right and middle ventricles, and passing into pulmonary artery.

c. Middle (ordinary right) ventricle given off.

d. Aorta.

e. Left ventricle. The probe passes from left to middle ventricle, through imperfect septum.

f. Superior vena cava emptying itself into left auricle.

FIG. 2.—Case 2:

a. Right ventricle, communicating with middle ventricle and giving off aorta.

b. Middle ventricle, giving off pulmonary artery.

c. Probe passing from left ventricle, through imperfect left septum, into middle ventricle; and then by imperfect right septum into right ventricle.

d. Superior aorta.

e. Pulmonary artery.

f. Ductus arteriosus, uniting with pulmonary artery to form descending aorta.

Fig. I.

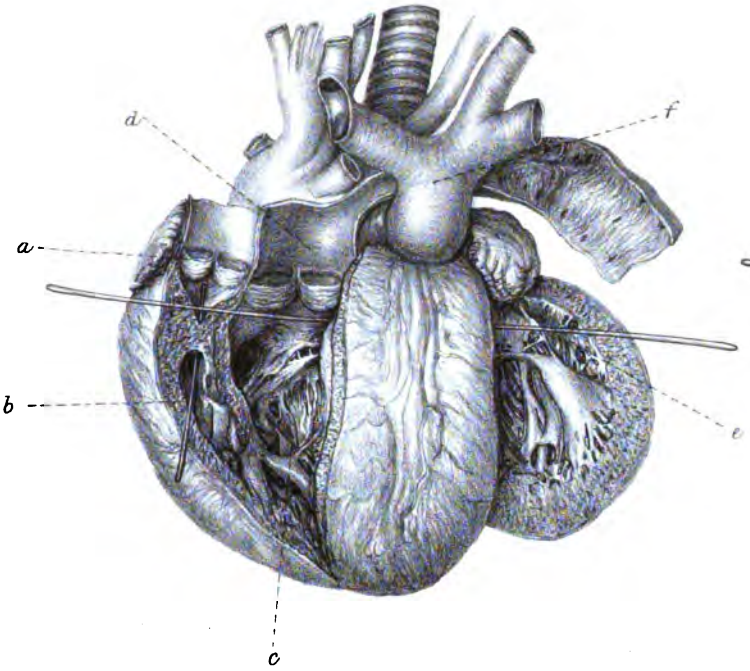

Fig. II.

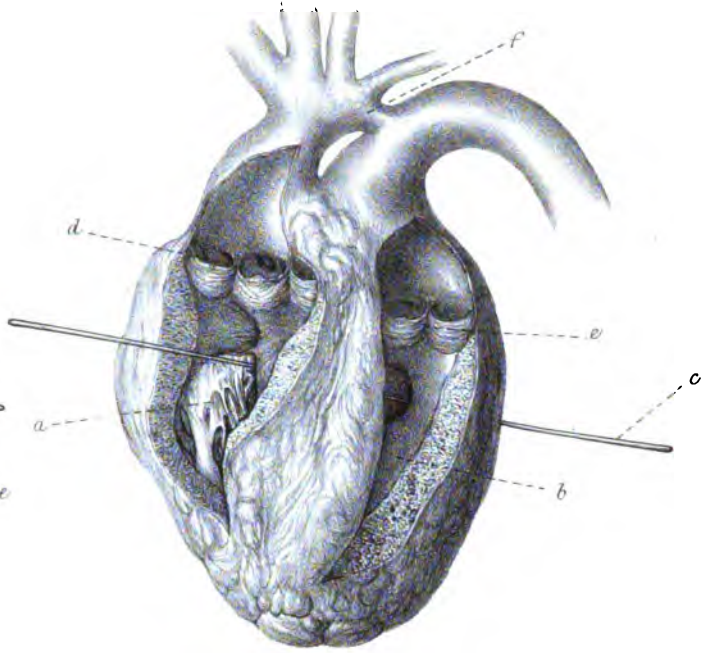

E. Burgess, del. et lith.

West Newman & Co. imp.

2. *Two cases of congenital malformation of the heart.*

By Stephen Mackenzie, M.D.

[With Plate I.]

Case 1. *Contraction of pulmonary artery, which had only two valves; supernumerary septum in right ventricle; imperfect septum ventriculorum; obliteration of right, and persistence of left superior, vena cava; foramen ovale closed.*

E. L. H—, female, æt. 2½ the second child of its parents. The mother suffered from the deformity produced by old hip-joint disease. The child was stated to have been blue from birth, and throughout her lifetime suffered from frequent convulsive seizures. During these fits and in attacks of coughing she became exceedingly cyanotic. The patient first came under the notice of the late Dr. Woodman, who, on my succeeding him as physician to the London Dispensary, pointed my attention to the case as one of congenital heart disease. The child remained under my observation for about a couple of months, and was at all times markedly cyanotic, but when she cried the face and nails became almost black. The end of the fingers were clubbed. The heart's apex-beat in nearly its normal position. There was always a systolic murmur heard all over the cardiac area. For about one week before its death the abdomen became large, and the legs and hands œdematous. The patient died in a convulsion on March 11th, 1875.

The necropsy was made the following day. On opening the thorax and slitting up the pericardium the greater part of the heart visible was the apparent right (middle) ventricle.

The interventricular septum and a small part of the left ventricle could also be seen, and an arterial and venous trunk arising from the base. On removal a more detailed examination showed that the heart possessed two auricles and apparently three ventricles, and that some of the systemic veins emptied themselves into the left auricle. To describe the individual parts more fully:

The right auricle has a well-formed appendix. The foramen ovale appeared closed, but a slit-like opening exists in the septum by which the right auricle communicates with the left; it appears accidental. The right auricle has three openings.

1. The opening of a vertical venous trunk, which passes behind the aorta and opens in front of the auricular appendix.

2. The opening of the inferior vena cava in its usual position.

3. The right auriculo-ventricular opening.

Left auricle.—Appendix well formed. There are five openings:

1, 2, 3. Openings of pulmonary veins.

4. A large thin-walled vessel, the superior vena cava, formed by the union of the right and left brachio-cephalic trunks, opening into the left auricle just behind the auricular appendix.

5. Left auriculo-ventricular orifice.

There is an appearance of three ventricles, the usual right (middle) having a portion partitioned off. These may, for convenience, be designated right, middle, and left ventricles.

Right ventricle, being small, not entering into the formation of the apex, and not communicating with the right auricle. The right ventricle has small papillary muscles of its own. It has two openings:

1. An opening into the middle (usual right) ventricle, by means of a very imperfect septum, partly muscular, partly tendinous.

2. The opening of a small arterial trunk—the pulmonary artery—guarded by two semilunar valves.

Middle ventricle (ordinary right) thick, fleshy, with well-marked papillary muscles, and a moderating band. It presents four openings.

1. Right auricular-ventriculo orifice, guarded by a tricuspid valve.

2. Large arterial trunk (aorta), guarded by the well-formed semilunar valves.

3. An opening, the size of the end of the little finger, in the septum separating this cavity from the left ventricle.

4. An opening, a quarter of an inch in diameter, in the very imperfect septum separating this cavity from the right ventricle.

Left ventricle, about the same size and thickness as middle ventricle; walls fleshy, musculi papillares well marked. It has two openings:

1. Left auriculo-ventricular orifice, guarded by a biscupid (mitral) valve.

2. Opening in imperfect septum, by which the cavity communicates with middle ventricle.

Vessels in connection with the heart:

1. Very large aorta, with three well-marked semilunar valves,

and two sinuses of Valsalva. It originates from the middle ventricle, and communication from the left ventricle can only take place through the defective left septum. It divides at the usual points into innominate and left carotid and subclavian arteries.

2. Very small pulmonary artery, coming off from right (supernumerary) ventricle, guarded by two small semilunar valves, and dividing above into right and left branches.

3. A single vertical thin-walled vein, formed by the junction of several branches opening into right auricle.

4. Inferior vena cava, pursuing its usual course and terminating in its usual position.

5. Large venous trunk, formed by the union of the right and left brachio-cephalic veins, constituting a superior vena cava, emptying itself into the *left* instead of into the right auricle.

The relations of the parts at the roots of the lungs were as follows:

Right root.—From above downwards: bronchus, artery, vein. From before backwards: artery, bronchus, vein.

Left root.—From above downwards, and from before backwards: artery, bronchus, vein.

No abnormalities existed in other parts of the body.

The course of the circulation must have been most irregular. The right auricle received the blood from the lower half of the body, the portal blood, and some blood from the upper half of the body. From the right auricle the blood would pass into the middle ventricle, where it would mingle with the mixed venous and arterialised blood coming from the left auricle, and be distributed through the aorta to the systemic arteries; a small portion of this blood would pass through the imperfect septum between the middle and right ventricle, and be distributed through the pulmonary artery to the lungs. The blood received by the left auricle would be mixed, consisting of the venous blood of the irregular superior vena cava and the arterialised blood of the pulmonary veins; it would pass into the left ventricle, and from thence through the imperfect ventricular septum into the middle ventricle, and be distributed by the aorta; a small portion of this blood might reach the right ventricle through the imperfect right septum. The right ventricle could only receive blood from the middle, and through this, indirectly from the left ventricle, the blood would pass from it into the pulmonary artery and return by the pulmonary veins to the left auricle. It is thus clear that all the circulating blood must have been of a very mixed character.

CASE 2.—*Supernumerary ventricle, or supernumerary septum in the right ventricle; imperfect septum ventriculorum; a superior aorta given off from supernumerary ventricle; descending aorta formed by pulmonary artery after receiving the ductus arteriosus from the superior aorta; patent foramen ovale and ductus arteriosus.*

E. L—, æt. 39, was the fourth child of a family of nine. The details of the family history presented no points of importance.

From her earliest recollection she had been blue. As a child she had played and run about as well as her companions, but sometimes she would get out of breath. She grew up to womanhood strong and healthy, suffering a little occasionally, however, from palpitation. The catamenia did not appear until she was twenty years of age, and she had no menstrual flux the last five years of her life. About 1868–69 she had typhoid fever, with which she was in bed three months. She was never quite well afterwards. In 1870–71 she was an in-patient at the London Hospital for dropsy, and after that was subject to swelling of the feet and legs on standing much. She had worked hard and often lived badly. In 1875 she had what appeared to be an epileptiform seizure, the only one she ever had. In March, 1875, she was admitted into the London Hospital under my care.

She was then thirty-nine years of age. Her body was stunted, and her weight only six stone. She was extremely cyanotic, and the ends of the fingers were markedly clubbed. Her chest was somewhat deformed, there being a projection of the upper and a depression of the lower part of the sternum. The chief cardiac impulse was felt between the xiphoid cartilage and the left margin of ribs. A very long and distinct presystolic thrill was felt between the left margin of sternum and left axillary line, and at its conclusion there was a circumscribed and forcible impulse in the fifth and sixth left interspaces immediately external to the nipple. Simultaneously with the presystolic thrill (as timed by carotid pulse) there was recession of the fifth, sixth, seventh, and eighth left intercostal spaces. In the eighth and ninth left interspaces, one inch to the left of the axillary line, there was a well-marked impulse alternating with retraction of the skin. About midsternum was a harsh, blowing, double murmur. There was also a superficial grating double sound, evidently pericardial. The patient was relieved for a time

by treatment, but gradually sank with the usual signs of cardiac failure, the cyanosis deepening as she became worse.

Necropsy, made by Mr. McCarthy and Dr. Stephen Mackenzie.—Pericardium extremely congested and everywhere adherent; mediastinal glands enlarged; veins of neck much gorged, and their walls thickened.

Heart, examined *in situ*, very large. The apex projected considerably to the left. A single arterial trunk was seen to come off from the heart, which divided above into innominate, left carotid, and left subclavian arteries. On cutting off the apex of the heart, the cavities of the seeming right and left ventricles were exposed, and were found to communicate by an opening in the septum, which would admit a finger. To the right of the seeming right ventricle was a small cavity communicating with it, and giving off the arterial trunk.

On removing the heart and examining it more carefully, the following were the conditions observed:

Right auricle large and thin walled; the inter-auricular septum very thin. Foramen ovale widely patent, admitting an adult finger with ease. Annulus ovalis perforated by minute orifices in three or four places. Eustachian valve well developed, but very thin. Coronary valve normal; appendix well formed. The right auriculo-ventricular orifice, guarded by well-formed and competent valves, opened into the middle (seeming) right ventricle.

Left auricle large and its walls thin, but slightly thicker than those of right auricle. It presented the openings of the pulmonary veins, the patent foramen ovale, and the left auriculo-ventricular orifice.

There were three ventricles, right, middle (apparent right), and left.

Right ventricle.—Not one third the size of the other two ventricles. It lay in front of the right segment of tricuspid valve. It did not enter into the formation of the apex. It had papillary muscles continuous with those of the middle ventricle. It presented two openings:

1. One by which it communicated with the middle ventricle, and through this with the left ventricle.

2. The opening of an arterial trunk (ascending aorta) guarded by semilunar valves.

Middle ventricle (ordinary right ventricle).—Walls of about

equal thickness and cavity of nearly equal size with those of the left ventricle. It presented four openings:

1. Right auriculo-ventricular orifice guarded by tricuspid valve.

2. The orifice of a large thin-walled vessel with semilunar valves (pulmonary artery).

3. Opening in imperfect left septum, by which it communicated with left ventricle.

4. Opening in very imperfect right septum, by which it communicated with right ventricle.

Left ventricle.—Formed, with the middle ventricle, the apex. It presented two openings:

1. Left auriculo-ventricular orifice guarded by bicuspid (mitral) valve.

2. Opening in defective septum, by which it communicated with the middle, and through this, probably, with the right ventricle.

Trunks given off from the heart:

1. *Pulmonary artery.*—Large trunk given off from middle (usual right) ventricle. Its walls exceedingly thin, and its entrance guarded by three very attenuated semilunar valves of large size. It first received a communicating branch from the aorta (ductus arteriosus), about the size of a goose-quill, then gave off right and left pulmonary branches (not represented in the drawing), and finally, was continued to form thoracic and abdominal aorta. The pulmonary artery formed a complete arch, passing from before backwards, and from right to left.

2. *Superior aorta.*—A trunk half the size of the preceding, given off from the right ventricle. It was guarded by three well-formed semilunar valves, and had the appearance and nearly the thickness of an aorta. After ascending some distance it gave off—1. An innominate artery, which divided at the usual points into right carotid and subclavian arteries. 2. The left carotid artery. 3. Vertebral artery. 4. Left subclavian artery. It ended in a vessel which communicated with the pulmonary artery (ductus arteriosus).

The vessels which brought the blood to the heart had a normal arrangement.

The remainder of the body presented no points bearing on the cardiac deformity.

Probable course of the blood.—The venous blood coming from the cavæ would be received by the right auricle, and from thence it would pass into the middle ventricle (ordinary right ventricle);

from thence it would pass mainly into the pulmonary artery and lungs, and to the lower half of the body by the descending aorta; part of it, however, mixed with the arterialised blood from the left ventricle, would pass into the right ventricle, and be distributed by the superior aorta to head and upper part of body. The arterialised blood coming from the lungs would collect in the left auricle, and pass from thence, into the left ventricle. It could only pass from thence, through the deficiency in the left septum, into the middle ventricle; from thence it would pass into the pulmonary artery, and through the imperfect right septum into the superior aorta. It is probable, however, from the position of the parts, that the current of blood from the left ventricle passed directly across the middle ventricle into the right ventricle, and in this way was distributed to the head and upper extremities. In this case two currents of blood would cross in the middle ventricle. Under any circumstances the arterial and venous blood must have been thoroughly commingled in the ventricular chambers, and no part of the body could have been supplied by pure arterial blood.

In Case 1 the condition of the pulmonary artery and ventricles resembles that of several recorded cases. There was atrophy with stenosis of the pulmonary artery and imperfection of the valves. The infundibulum of the right ventricle was shut off from the sinus by means of an imperfect, partly muscular, septum, an exaggeration of the division of the muscular columns, to which the folds of the tricuspid valve are attached. This cavity, very small, had no communication with the right auricle, except through the right (middle) ventricle. The ordinary interventricular septum was imperfect indicating that the disease occurred moderately early in intra-uterine life, before the separation of the ventricles was complete. The aorta, as usual in such cases, was situated to the right of its usual position, arising from the right (middle) ventricle. The foramen ovale was closed, as occurs in a certain small proportion of cases of this deformity when the communication between the right and left heart (rendered necessary by the contraction of the pulmonary artery) is free, by way of the imperfect ventricular septum. The middle (right) and left ventricles are of about equal thickness, showing that they shared the work of pumping on the blood. It is greatly to be regretted that the condition of the ductus arteriosus was not observed. From the small size of the

pulmonary artery it would appear certain that there was some supplemental blood supplied to the lungs.

The branches of the aorta, large at its commencement, were given off as usual. A second point of great interest in the case is the irregular termination of the superior vena cava. This, by persistence of the left duct of Cuvier, and non-development of the right superior cava, emptied itself into the left auricle. It is probable that the vertical vein which emptied itself into the right auricle was a vestige of the right duct of Cuvier.

In Case 2 the justification for regarding the divisions of the ventricular cavity as three distinct ones is much clearer. Here the extreme right ventricle, though very small and separated from the middle ventricle by a very incomplete septum, could not be regarded as the detached conus arteriosus of the right ventricle, as the vessel it gave off was not the pulmonary artery, but the superior aorta. As far as my search extends this form of abnormality is unrecorded.

May 18*th*, 1880.

---

3. *A case of suppurative myocarditis with scarlatinal nephritis.*

By James F. Goodhart, M.D.

A child, æt. 3½, was brought to the out-patient room of the Evelina Hospital on May 23rd, 1879, for fits, which had come on quite suddenly. These proved to be the precursors of a scarlatinal eruption, and I did not see it again till June 24th when it was brought because dropsy had supervened.

It was then desquamating; there was considerable œdema of the face, hands, and feet, extreme pallor; respiration was rapid; there was much coarse crepitation at the bases of both lungs, the heart's action being galloping and distant, but without any bruit or evident displacement of the apex. The urine contained abundant albumen and some lithates.

Being on the look-out for cases of sudden dilatation of the heart in scarlatinal nephritis, I thought that perhaps this might be such a case, and accordingly admitted it. The subsequent notes state that it vomited occasionally, and that it was ordered infusion of digi-

talis ʒss, ex aquâ ʒss, every six hours. It had three doses of the medicine, and appeared to become drowsy after the second. After the third it began to wander and throw its arms about; its breathing became gasping and its extremities cold, and in this state it died after some hours.

At the *post-mortem* the state of the heart at once attracted attention. The pericardium was distended with ℥iss of fluid, and the left ventricle was peculiarly globular, and the vessels of the surface turgid. Moreover, the wall had a peculiar mottled-yellow appearance, very unusual. A section of the ventricle showed that these appearances were due to a diffused suppuration in the muscular wall. The ventricular cavity was rather dilated, but the wall was very much thickened by a diffused infiltration of pus, which extended from the front round the left aspect to the hinder part, and was more extensive at the base of the ventricle round the attachment of the auricles than at the actual apex. There was no lymph on the surface of the valves or pericardium, and the right side was healthy.

The kidneys weighed four ounces, and they were in the fatty stage of tubal nephritis. There was no pus in any of the joints, and, except a little fluid in each pleura, no other disease was found.

November 18*th*, 1879.

---

4. *A case of fatty degeneration of the heart after hæmorrhage in typhoid fever.*

By James F. Goodhart, M.D.

A boy, æt. 6, was admitted into Guy's Hospital, under the care of Dr. Pavy, on October 8th, 1879. Seventeen days before he had first appeared to be ill with headache and disinclination for exertion. For three days before his admission he had had diarrhœa.

He was very ill with typhoid fever, and on the twenty-ninth day there was extensive hæmorrhage from the rectum. This recurred on the thirty-first day, together with epistaxis, and he died on the thirty-fifth day of his illness. The fluctuations in temperature were considerable in the course of his illness, on the nineteenth and

twenty-third day reaching 105° at night. It dropped to 100° on the sixteenth day; the general average was about 103°. The hæmorrhages left him very blanched and exhausted, but the actual termination of the case was sudden.

At the inspection the heart weighed two ounces. The muscular tissue of its walls was pale and the sub-endocardial muscle was spotted all over with yellowish points, giving it the characteristic appearances of the tabby striation of fatty degeneration. The left ventricle was considerably dilated.

Under the microscope the muscular bundles were very granular and full of small dark bodies like small fat globules.

The lungs were œdematous.

The interest of the case lies in the connection which may be supposed to exist between the anæmia induced by the hæmorrhage and the fatty degeneration of the heart. Some cases of degeneration of the muscular structure of the heart can be attributed to the febrile process itself. But such a marked tabby striation as existed here is, I am inclined to think, more likely to be an acute change dependent upon the hæmorrhage.

I have seen three other such cases, and others have described similar ones, although I do not think the condition of fatty degeneration as dependent upon anæmia has yet obtained any general recognition.

November 18*th*, 1879.

---

5. *Case of rupture of right ventricle of the heart.*

By T. B. Peacock, M.D., for Thomas Fisher, of Great Eccleston, Garstang, Lancashire.

[With Plate II.]

The subject of the accident was a man, æt. 25, who had never had any disease to require medical aid, and who was noted as an athlete and for his great strength. On the 13th of September, after a wrestling match, he took some drink and became partially intoxicated. He then began to fight with another man and received a blow with the clenched fist in the epigastrium. He immediately fell down

DESCRIPTION OF PLATE II.

This Plate illustrates Dr. Peacock's Case of Rupture of the Right Ventricle of the Heart. (Page 72.)

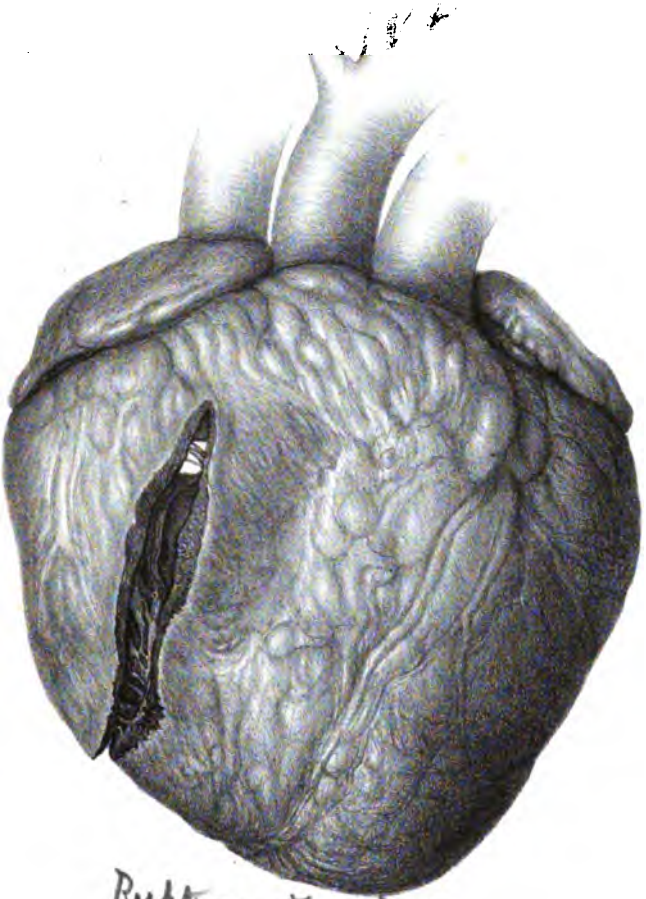

Rupture of right ventricle

E. Burgess, del. et lith.

West Newman & Co. imp.

insensible and showed no signs of consciousness afterwards; while on the ground he was kicked. He was carried home dead, forty minutes after receiving the blow.

There was a contused wound in the right temporal region and the right eyeball was ruptured. In this situation there was a fracture of the skull, but without any displacement of the bones, and the dura mater and membranes of the brain were not injured, and there was no clot internally. There was no external injury elsewhere.

On removing the sternum, the pericardium was noticed to be very prominent, and on opening it, it was found to be filled with clotted blood; a rupture, measuring three and a half inches in length, extended along the front of the right ventricle, from near the base to beyond the apex, which, though valvular, penetrated into the cavity. The ventricle was dilated, and its walls in the seat of the rupture and elsewhere were pale coloured, and had in places undergone the fatty degeneration, while in other parts the muscular structure was healthy. There was much fat on the surface of the heart, but the valves were healthy and the large vessels free from atheroma. There was a small quantity of fluid in one of the pleural cavities; the abdominal organs were healthy; the urine contained in the bladder was free from albumen.

December 16*th*, 1879.

---

6. *Incompetency of the aortic valves produced by a strain; subsequent endocarditis and formation of a polypoid body hanging into the left ventricle, and causing ulceration of the ventricular septum and erosion of the adjoining cusp of the valve.*

By Edward Headlam Greenhow, M.D.

The specimen exhibited to the Society was taken from the body of G. C—, æt. 39, a gardener by occupation, who was admitted into the Middlesex Hospital, under my care, on July 28th, 1879. He was a man of temperate habits, and his previous health had been good. He had never suffered from rheumatism in any form. Three months before admission to the hospital, whilst lifting a heavy weight, he had felt as though something had given way in his

inside, and had at the same time experienced a sudden pain right through his body. Whenever, subsequently, he attempted to lift any weight he again felt the same pain. For some time after the accident he appears to have suffered no other inconvenience besides this pain, and was able to continue at work. Some two months later he began to suffer from palpitation and shortness of breath on making any exertion, and, about a week before presenting himself at the hospital, he observed that his feet and legs were swollen, and that his urine was scanty and high coloured.

On admission he was free from fever; pulse 116, collapsing; urine sp. gr. 1026, acid, not albuminous. He complained of palpitation; his feet and legs were œdematous, and he suffered from constant orthopnœa. The heart's impulse was much diffused, and the apex beat in the fifth intercostal space three quarters of an inch outside the nipple line. A loud systolic and long diastolic murmur were heard at the base of the heart and down the course of the sternum. The systolic murmur was not audible at the point of the left scapula. The percussion resonance was slightly impaired over the posterior bases of the lungs, where also some œdematous crackling was heard.

After a few days the patient lost the orthopnœa, and for a time appeared much better, but in the course of a few weeks he again began to suffer from orthopnœa and from violent retchings; his urine became albuminous, the lungs more œdematous, and he died on September 15th.

Post-mortem examination.—On raising the sternum the heart was seen to be much enlarged, so that it pressed aside the left lung; the apex corresponded to the sixth rib in the anterior axillary line; it was rounded, and formed about equally by the two ventricles. The right auricle was capacious, and distended with black clot; the auricular appendix was greatly developed, and its muscular bands thick and prominent. The tricuspid orifice measured five inches in circumference; the valve was slightly opaque. The right ventricle was large, and its walls thicker and firmer than natural; the muscular columns were also greatly developed. The pulmonary valve was normal. The left auricle was capacious and its lining membrane opaque. The mitral orifice measured four and a quarter inches in circumference; the mitral valve was normal and not thickened, and the chordæ tendineæ were quite natural. The left ventricle was globular in shape and full of clot; its in-

terior was quite honeycombed by the great development and division of the columnæ carneæ.

The aortic valves were freely incompetent; the right and middle cusps were puckered, thick, and attached to one another. A polypoid vegetation, half an inch in length, semi-calcified, and with rounded margins, attached by its base to the right cusp, hung loosely into the ventricle; it measured a quarter of an inch in thickness, and its base, where attached to the cusp, measured three eighths of an inch. Upon the wall of the ventricular septum, opposite to the free end of this vegetation, was an ulcer, about the size of a threepenny-piece, over which the endocardium was wanting and the muscular fibres exposed; but there was no thickening, neither were there any vegetations around the ulcerated surface. The central cusp of the valve was of fleshy consistence and much deformed; it was quite free from vegetations, but near its left attachment its margin was interrupted by a V-shaped notch, sharply cut, as if the valve had been split. The notch reached nearly to the attached border of the cusp, and measured a quarter of an inch in depth. The left cusp was also fleshy and free from vegetations, but it presented a remarkable loss of substance, as if a considerable portion of the valve had been gnawed away, leaving the free border irregular and jagged. The aortic orifice measured two and three quarter inches in circumference. No atheroma was found. The wall of the left ventricle was soft and flabby. The lungs, spleen, liver, and kidneys, were all of them rather tough.

Three hæmorrhagic infarctions were found in the right and two in the left lung, but none were found either in the spleen or kidneys.

Remarks.—When the patient came under observation there was no doubt as to the existence of aortic obstruction and incompetence, and I inferred, from the history of the case, that these conditions had originated in an injury to the aortic valves produced by the strain to which they had been subjected. I am still of the same opinion; because, except the erosion of the still healthy valve-cusps, and the ulceration on the ventricular septum, produced by the friction of the polypoid vegetation, the only certain evidence of endocarditis was situated on the right and middle cusps. I am inclined to think that, at the time of the strain, some injury to the left, and perhaps also to the middle, cusp took place, which excited endocarditis, and led to the fusing together of these cusps

and the formation of the pendulous vegetation. At first, indeed, I was disposed to believe that the V-shaped notch in the middle cusp had been the original mischief, but the absence of vegetations or thickening in the vicinity of the notch, and their presence on the neighbouring right cusp appear opposed to that view. Moreover, in all the cases on record which I have read, in which valvular disease of the aortic valves has arisen from injury, the injured cusp has been detached very near its attachment to the wall of the artery, whereas the notch in the present case was situated near the middle of the cusp, and may very well have been caused, like the erosion of the left cusp, by the friction of the pendulous polypus. The view I have expressed accords well with the clinical history of the case, for the man felt no great inconvenience until many weeks after the injury. Probably at first there was little or no incompetency of the valves, which only became developed after the polypoid vegetation, adherent to the injured valve-cusp, had eroded the adjoining cusps, and rendered them incompetent to prevent the reflux of blood from the artery into the left ventricle.

November 4th, 1879.

---

7. *Fibroid patch of interventricular septum of heart; blood-clots in brachial, hepatic, and superior mesenteric arteries; gangrene of portion of jejunum.*

By Henry T. Butlin.

Unfortunately, the clinical portion of this case is not so complete as it should be, but the interesting features were not discovered till the death of the patient rendered it too late to supply the deficiencies. He was an inmate of St. Bartholomew's Hospital only for three or four days previous to his death; was admitted to the hospital on account of gangrene of the tips of the left index and middle fingers (thought to be due to exposure to cold), and on account of occasional pains across the abdomen. No urgent symptoms were noticed until Feb. 27th, 1879 (three

days after admission), when he was very sick, and complained of intense abdominal pain. On the 28th he brought up a large quantity of vomit (which contained no blood), exhibited signs of collapse, and quickly died.

In recording the *post-mortem* examination I shall content myself with describing only those parts in which disease was observed. Occupying the lower part of the interventricular septum of the heart and the posterior wall of the left ventricle was a whitish plaque of circular shape, 1½ inch across and about ⅓ inch in thickness, projecting into the left ventricle, but not apparent in the right, for it was scarcely more than superficial in its relation to the septum. This plaque was well defined, smooth at its border, but roughened over most of its surface, and coated with decolorised and ragged, friable clot. The endocardium for some distance round it was white, opaque, and thicker than elsewhere, but with this exception the heart in all its parts was normal. Examined with the microscope the little mass consisted of coarse fibrous tissue, with which occurred a few round or elongated cells, or more rarely groups of cells, like leucocytes. The left brachial artery was completely obstructed from its commencement to its bifurcation by blood-clot, which extended down the radial artery to the wrist, but along the ulnar artery only so far as the common interosseous. The oldest portion of the clot was evidently that which lay in the brachial artery at the point where the anastomotica magna is given off; there it was friable and decolorised, and resembled that in the left ventricle, but elsewhere it was brown or black in colour, and softening in the centre. In each of the digital arteries to the gangrenous fingers was a tiny, firm, colourless clot, about the size of a small grain of rice; the digital arteries supplying the other fingers were completely pervious. The abdomen was the seat of general and apparently quite recent peritonitis. Stercoraceous matter was found in the peritoneal cavity, and had evidently escaped there from the jejunum, a large portion of which was very soft, easily torn by the slightest force, much discoloured, and, at its upper part, perforated at two points. The superior mesenteric artery and its branches were plugged with blood-clot resembling that found in the brachial. The hepatic artery was in a similar condition.

This case appears to deserve a place in the 'Transactions' of the Society—first, on account of the affection of the interventricular septum; second, because of the condition of the intestine and the

mesenteric artery. The fibrous plaque within the heart may be regarded either as a new growth or as an inflammatory (or specific) formation. The latter appears the more probable theory, for simple fibrous tumours of the heart are rare, and this does not resemble in its characters such growths as described by Wagstaffe ('Trans.,' xxii, p. 121) and Kothneier ('Virch. Arch.,' xxiii, s. 434), but is more like those described in the 'Transactions,' vol. xxviii, p. 334, and vol. xxvi, p. 58, by Dr. Pye Smith and Dr. Greenfield. There is no evidence in the present instance of syphilis, but no history of venereal disease was sought for.

The gangrenous condition and perforation of the jejunum is chiefly of interest when considered in relation with certain other cases of perforation and gangrene. Mr. Baker's case, for example ('Trans.,' vol. xxvii, p. 165), of which I made the autopsy, but did not sufficiently examine the vessels of the intestine, may possibly be explained by the supposition of a similar but less extensive arterial obstruction to that which occurred in the present instance. And the case related by Mr. Howse (vol. xxix, p. 101), in which portions of the bowel were perforated, and the superior mesenteric artery was blocked with clot, appears to be of the same nature as that now related. But whereas the cause of the arterial obstruction may in the present instance be traced without difficulty to emboli from the clot in the left ventricle of the heart, Mr. Howse attributes it in his case to the condition of the intestine, a theory singularly opposed to those generally prevailing of the relation of arterial obstruction to gangrene, and, I imagine, only indulged on account of the difficulty of discovering a primary thrombus from which emboli could be conveyed. It may, perhaps, be suggested that the pneumonic condition of the lung mentioned by Mr. Howse was a not unlikely cause of thrombi of the pulmonary veins, and that from such a source as this emboli had been detached.

---

8. *Aortic, mitral, and tricuspid stenosis; firm organized clot in left auricle, leaving only a narrow channel for the blood.*

By J. Pearson Irvine, M.D.

A woman, æt. 37, was admitted in August, 1879, into Charing Cross Hospital, and in the absence of my friend, Dr. Green, was for some time under my care. She was a housemaid and had lived in a healthy part of London, but from childhood she had not enjoyed good health. She had always suffered from dyspnœa. Menstruation began about the usual period, but she had frequently required remedies to set herself right. Ten years before admission she attended as an out-patient at Charing Cross Hospital, and five years before admission I saw her in the out-patient room. She then had many of the symptoms and signs of cardiac mischief given below. Her family history was good. She had not had rheumatic fever.

On admission she was found to be suffering from extraordinary œdema of the lower extremities, from ascites, cardiac irregularity, slight jaundice, and great dyspnœa. The urine was scanty and contained bile. After a rest of a few days in hospital a careful examination of the heart was made. Jaundice still persisted at the time. The heart's apex was on the nipple line and in the fifth space; the general cardiac impulse was weak and wavy from the apex towards the sternum and upwards. On auscultation the ventricular contractions seemed to follow one another, and a double systolic murmur could be heard at the apex, and then came a diastolic bruit (also at the apex), which did not run up to the first sound. The first systolic bruit was heard best over the right ventricle and towards the base, the second faintly at the base, and best at the apex. The diastolic bruit was most distinct a little above the apex, and was accompanied by a thrill. The pulse was irregular and intermittent.

After the patient had been in hospital a few weeks the general symptoms and physical signs varied considerably. The systolic murmur became most prominent, and could be heard at apex, base, and along the great vessels. The patient improved considerably under general and varied treatment, and her dyspnœa, œdema, &c., were

greatly relieved, but she had renewed attacks of dyspnœa and died with all the symptoms of congestion of lungs, liver, and kidneys, as in many cases of mitral mischief, only in an exaggerated degree.

On *post-mortem* examination, was found considerable hydrothorax, which had contributed much to the dyspnœa. In the lower lobe of the right lung was a large infarct, two by three inches in measurement on the surface. Smaller infarcts were found in the left lung. But there were no signs of embolism in the spleen, which, as well as the liver and kidneys, showed the ordinary appearances of severe chronic congestion. There was considerable ascites, which was but a part of the general evidences of impediment to flow of blood through the heart and lungs—an impediment which examination of the heart at once explained. The left ventricle was moderately hypertrophied, and its walls were soft, flabby, and fatty. The aortic flaps were contracted and roughened, and so unyielding that they must have greatly opposed the blood current. The same terms are applicable to the mitral valves, which were so thickened and retracted that regurgitation and impediment must have occurred. The left auricle presented the most peculiar appearances; it was largely dilated, in fact, dilated into an aneurysmal condition, its appendix forming a true aneurysm in short, which had become filled up with a laminated clot, careful examination of which proved that it had taken many months for its formation. This clot had evidences of having been formed layer by layer, as in the case of aneurysms, was consolidated and partially organized, and simply left an extension of the pulmonary vessels through the auricle to the left ventricle. It is quite in accordance with the *post-mortem* appearances to say that the pulmonary vessels met in the left auricle and followed a narrow vascular channel into the ventricle through a constricted mitral orifice. The right side of the heart was also peculiar. The pulmonary artery and its valves were healthy, but the right ventricle was dilated and the tricuspid valves were, one and all, diseased. Each flap was thickened, shortened, and inelastic; and it was plain that obstruction had been great at this orifice also. Both the superior and inferior venæ cavæ were much dilated, and, as has been said, all organs behind them declared a vast impediment to flow of blood in the heart and lungs. The right auricle was much dilated, and in its appendix were found old blood clots, which had, no doubt, caused by embolism the infarctions met with, especially in the right lung. It is worth noticing

that though an immense clot was found in the left auricle no embolic patches were met with in the spleen, kidney, &c.; for this fact indicates that this clot was more or less organised, and resembled those met with in aneurysms.

The coexistence of aortic, mitral, and tricuspid stenosis is not a common occurrence, and the case is of interest on this account. The interest is increased by the fact of the formation of a clot (exactly resembling an old aneurysmal clot) in the left auricle, and simply leaving a channel for the passage of the blood. The left auricle was to all intents and purposes aneurysmally dilated, and its aneurysm had been protected exactly as in the case of arterial aneurysm by laminated clot, for so firm was the clot that to some it suggested the occurrence of new growth. The slowing of the blood current, and the obstruction at the mitral and aortic orifices, explains the causation of enlargement of the auricle, and the formation of the organised clot. It is clear that cases of this kind have a great bearing on the question of distal ligature in aneurysm; and I think Dr. Moxon, two or three years ago, brought before the notice of the Society, a case in many respects similar to mine.

Was the disease congenital or acquired? No question is more difficult to answer. We mostly admit that mitral disease is not uncommonly followed by tricuspid disease, for the mechanical condition of things declare the likelihood of such contingencies. In this case three orifices were obstructed, and it would be difficult to explain tricuspid obstruction and aortic obstruction on the theory of sequency of mitral mischief; and after a consideration of the history of this case, I am all but convinced that it is one of congenital disease. The patient's history points to this view; in fact, the clinical history and morbid anatomy explain each other; and it is quite unnecessary for me to take up further space in the discussion of these points. I may venture to say that the description of the morbid appearances taken with the bed-side history may help in the settlement of the question of the corelations of the valvular diseases of the heart. *April* 20*th*, 1880.

9. *Aneurysm of aorta opening into right auricle.*

By NORMAN MOORE, M.D.

THE aneurysm begins one eighth of an inch above the aortic valves, and extends backwards and outwards along the upper edge of the right auricle. At the uppermost part of the anterior wall of the auricle the aneurysm has penetrated the muscular tissue forming an orifice with a rounded edge a quarter of an inch in width.

This orifice had no doubt been in existence some time before death. The aneurysm contained no fibrin.

The patient was a man aged forty-four, with well marked physical signs of aneurysm, but no special physical signs or symptoms of the communication. *February*, 1880.

---

10. *Extra-pericardial aneurysm of the ascending aorta, with an unusually small orifice; leakage into the pericardium without any visible perforation.*

By WILLIAM EWART, M.B.

THE specimen was removed from the body of a painter, æt. 33, who died on October 13th, 1879. His health had been uninterruptedly good, with the exception of an attack of rheumatic fever in September, 1878; he did not appear to have been the subject of syphilis. In April, 1879, œdema supervened in the lower extremities and rapidly increased; a fortnight later the hands also swelled. Dyspnœa, cough, and palpitation commenced in July, and persisted thenceforth. Morning retching was first complained of in the middle of September, and, at the end of the same month, the face became puffy. This event was the precursor of the urgent dyspnœa which necessitated his removal to St. George's Hospital on October 4th, and caused his death a few days later. During his stay in the wards the following observations were made[1]:—Tempera-

[1] For these and for the clinical notes of the case I am indebted to Dr. Isambard Owen.

ture ranging between 96° and 98° Fahr., never reaching the normal standard; pulse and respiration accelerated, the former never below 115 per minute, the latter never below 32; the heart's apex was felt in the sixth costal interspace at a point 1″ external to the nipple line; a systolic murmur was audible, loudest at the base, and a faint diastolic murmur, best heard at the apex, was also recorded. The dyspnœa increased. On the night of October 12th cyanosis and urgent distress supervened. The patient was bled the next morning from the right external jugular vein to the extent of eight ounces, but without relief, and he died in an hour and a half.

When opened in the usual manner (twenty-seven hours after death), the chest presented for inspection only what appeared to be an enormously distended pericardium, reaching the level of the sternal notch, and proportionately broad. By this the lungs were pressed asunder, and they were further compressed by large pleural effusions. The outline of the mass was slightly curved in the shape of the figure 8; the constriction corresponded with the real superior boundary of the pericardium. The pericardial cavity was much enlarged and containing, in addition to a somewhat hypertrophied heart, a large quantity of dark fluid blood. The source of this hæmorrhage was not discovered in spite of the most careful search. The upper part of the mass was formed by a large irregularly spherical aneurysm (longest diameter = 4½″, shortest diameter = 3½ inches) here and there lined with a spongy layer of fibrinous clot, and containing a soft clot weighing 6 oz., and some bloody fluid. The walls of the sac were tough and of even thickness, except at the floor, closely resembling at first sight the aortic membrane of which they appeared to be a continuation, but differing from it in that they could be slit up into lamellæ and into an external fibrous covering, the pleura. A single aperture existed at the lower third of the posterior wall of the sac; it was circular and measured ⅙ inch in diameter; its edges were smooth and its outlet perfectly clean, as though it had been punched out in a healthy aorta. It opened into the ascending aorta an inch above the point of reflection of the pericardium. The aorta was the seat of soft atheroma; its origin was irregularly dilated and bulged out into shallow depressions, none of which, however, were notably thinned. In the remainder of its course the aorta was of normal and perfectly even calibre. The heart, which was found in a state of imperfect contraction, was nearly empty. Considerable pressure had existed in the mediastina;

the veins were compressed and the superior vena cava so flattened from stretching, as to be nearly impervious. The air-tubes did not seriously suffer, but there existed a slight flattening of the aorta. Three or four pints of fluid were found in the peritoneal cavity, and, lastly, the kidneys were small and very granular. The pericardium was examined with special care for laceration or perforation, and the dilated origin of the aorta for undue thinning of its coats; these conditions were not found. Decided thinning was discovered at the floor of the aneurysm itself anteriorly; two patches, each about half an inch in diameter, were sufficiently thin to allow light to be seen through them, and the internal coating of the sac in this situation was loose and friable.

Remarks.—That an aneurysm of the size stated rising up to the neck and lying immediately behind the sternum should have passed unsuspected during life is amply explained by the anatomical conditions present. Seeing how small was the orifice of communication with the aorta, we doubt whether the tumour could have possessed a pulsation of its own, and the pulsation transmitted to it from behind was probably too weak to influence the sternum; it is also probable that no perceptible bruit was produced. The globular shape of the aneurysm and the even thickness of its walls, which obviously are not a simple expansion of the coats of the aorta, point to the conclusion that the tumour was of slow growth, and probably existed at a period when the patient considered himself in health. The symptoms described may be traced to the progressive loss of cardiac power, to the pressure upon the aorta and the large venous trunks, and to the final hæmorrhage into the pericardium.

Viewed pathologically the specimen has twofold interest. So small a mouth is a very uncommon feature in aortic aneurysm, especially when coupled with so large a sac. In the second place, although familiar with the occasional occurrence of very small so-called "pin-hole" perforations in intra-pericardial aneurysms, the author has failed to discover any account of extensive intra-pericardial hæmorrhage without visible solution of continuity of the serous membrane. Among the cases collected by Dr. Peacock in vol. xix of the Society's 'Transactions' no such instance occurs; and in the twenty-five cases given in abstract by Mr. Wagstaffe in vol. xxviii, whenever mentioned at all, the perforation is described as a palpable lesion. In the present instance the solution of continuity must have been so small as to escape detection with the naked eye

and with an ordinary lens; more probably the hæmorrhage was due to a partial loosening of the fibres allowing the blood to filter into the pericardium. Two other alternatives suggested themselves—(1) that some of the large venous or cardiac venous trunks had given way; no such lesion, however, could be discovered; (2) that a surface hæmorrhage had taken place from the visceral pericardium; this supposition was not supported by any evidence of blood change elsewhere. In reality the pericardial and the aneurysmal cavities were only separated by a thin and imperfectly organised fibrinous layer and by a serous membrane, which had probably been stretched to the utmost. The leakage occurred under high pressure both direct and transmitted; for the growth of the aneurysm increased the intra-thoracic tension, whilst the situation and the small size of its orifice precluded any rapid accommodation to the variations in the size of the tumour. Similar considerations will help to explain the size attained by the aneurysm in spite of the narrowness of its feeding aperture, and the absence of any tendency to spontaneous cure in spite of the relative smallness of the aortic lesion.

December 2nd, 1879.

Aneurysm of the abdominal aorta and external iliac artery opening into the vena cava.

By P. H. Pye-Smith, M.D.

The patient from whom this specimen was taken was a healthy man, twenty-eight years old, a paperhanger by trade, who was perfectly well until eight weeks before he came under my care in Guy's Hospital, January 2nd, 1880. He then looked like a man in an advanced stage of cardiac disease—breathless, pallid, and dropsical; but on auscultation the sounds of the heart were found to be normal. His illness began with a cough, followed by dyspnœa and abdominal pains. Next he began to vomit, and his legs swelled.

On admission there was marked orthopnœa, frequent cough with scanty mucous expectoration, occasional vomiting, and constant pain (not of a severe character), referred to the epigastrium and loins. His anasarca had increased, chiefly below the waist, with moderate ascites. A remarkably loud and harsh systolic bruit was

heard between the shoulders and down the back. There was a very slight arterial murmur over the ascending aorta and arteries of the neck; it was somewhat louder in the epigastrium, and in both femorals it was as marked as in the back and loins. The heart appeared to be healthy, except that the impulse was somewhat displaced outwards and downwards. The pulse was full, strong, and compressible, rapid and rather splashing in character. Pulsation could be felt in the dorsal artery of both feet. There was slight albuminuria. No abdominal tumour could be felt, nor was there any region of localised pulsation.

These symptoms seemed to point to narrowing of the descending aorta, either by pressure of a tumour from outside or by disease of its own tunics. I inclined to think that there was a tumour of the posterior mediastinum pressing upon the thoracic aorta. But when Dr. Wilks (in whose absence I had taken charge of the ward) resumed the care of his patients, he regarded the case as more likely one of deep-seated aneurysm of the aorta, pressing upon the inferior cava. By this time the dropsy of the legs had greatly increased, especially of the right. They were repeatedly drained by acupuncture, and twice by Dr. Southey's method of inserting a canula. Great relief was thus obtained, but after the second tapping gangrenous inflammation ensued, and the greater part of the right leg mortified. Symptoms of acute pneumonia of one lung rapidly followed, and the patient died on the 20th of April, eight days after gangrene had appeared.

At the *post-mortem* examination the heart and kidneys were found free from disease. There was red hepatization of the base of the right lung, and, probably still more recent acute peritonitis. The superficial veins of the abdomen were greatly distended, and there was excessive œdema of both legs, with fleshy, œdematous swelling of the lymph-glands. The capsules of the liver and spleen were thickened, and there was slight, apparently commencing, cirrhosis of the former viscus. The aorta was perfectly normal as far as the bifurcation, where its inner coat became suddenly opaque and scar-like in appearance, without atheroma, and it dilated into a globular aneurysmal sac, which involved the origin of the right common iliac artery. The aneurysm was embedded in a mass of œdematous lumbar lymph-glands, and had grown forward so as not to press upon the vertebra behind, nor apparently upon the vena cava. It measured nearly one and a half inches (35 mm.) in its vertical

diameter, by somewhat less (30 mm.) across. The opening into the aorta was smooth and almost circular, with a diameter of just an inch (25 mm.). Its walls were firm, thick, inelastic, and smooth. It communicated with the inferior vena cava by an oval orifice, 10 mm. long and 6 mm. broad, with perfectly smooth margins and no adherent clot. The cartilaginous thickening of the walls of the aneurysm extended a very short distance into both iliac arteries, and scarcely at all along the aorta.

The obstruction to return of blood through the vena cava was not, I conceive, caused by pressure from the sac of the aneurysm, but by the downward current of arterial blood being thrown suddenly into the slower ascending venous stream. From the same considerations of the small size and forward direction of the aneurysm it is probable that it produced little or no discomfort until it opened freely into the vein, and that the beginning of the patient's illness, five months before his death, marked the gradual formation of the orifice between the two great vessels.

It is worthy of note that the manner of opening was like the slow perforation of a mucous cavity by an aneurysm, and not like its sudden rupture into a serous cavity.

The clinical interest of the case was great, but I bring it before this Society as a pathological curiosity which it is well to put on record. The specimen is preserved in the museum of Guy's Hospital.

Aneurysms of the aorta below the cœliac axis are not common, and, though many cases are on record of an aneurysm of the arch opening into the pulmonary artery or one of the great veins, I have not found one of an aneurysm opening into the inferior cava in our own 'Transactions,' or elsewhere.[1]

With reference to the question of the origin of this aneurysm, I may add that, although the patient had a chancre and suppurating bubo seven years before his illness, there was no evidence of secondary symptoms, and no signs of constitutional syphilis were found, either during life or at the *post-mortem* examination. We have therefore, no means of accounting for the very circumscribed arteritis which led to the fatal aneurysm. *May 18th*, 1880.

[1] Since writing the above, I have found in the admirable Index Catalogue of the Library of the Surgeon-General's Office (U.S.A.), so liberally distributed by the American Government, two cases of rupture of an aneurysm into the vena cava inferior. One was recorded by the late Prof. John Reid in 1840 ('Edin. Med. Journ.,' liv, p. 115), the other by Mr. R. Robinson in 1834 ('Lond. Med. Gaz.,' xiv, p. 462).

12. *A case of so-called aneurysm by anastomosis of the ear.*

By Frederic S. Eve.

(With Plate III and Plate XVIII, fig. 3.)

Eva B—, æt. 21, was admitted to St. Bartholomew's Hospital, March 13th, 1879, under the care of Mr. T. Smith, to whose kindness I am indebted for permission to bring forward the case.

History.—The patient stated that there was a lump (probably a nævus) on the upper part of her ear at birth. It grew very slowly, but was always pulsatile.

Six years before her admission to the hospital, a prominent lump on the upper part of the pinna was ligatured on account of its increasing size.

Two years later two or three pins were passed beneath the tumour on the posterior surface of the pinna and left in a fortnight.

During the last year the vascular growth had extended very rapidly.

Bleeding had occasionally taken place from its surface since infancy, but had been more frequent and severe during the last year or two. A fortnight before admission she lost a large quantity of blood.

Description of ear.—The condition of the ear is well shown in the drawing taken before removal (see Plate III).

The pinna was of a purplish or dull-red colour, enlarged in all its dimensions, especially in thickness at the margin, and it stood out unnaturally from the head. The whole of the auricle posterior to the auditory meatus was involved in the vascular growth. The concha was filled up by a largely lobulated projection, and the helix and posterior surface of the pinna were finely lobulated; the lobulations were *not* produced by large tortuous vessels, except at the margin of the growth.

The ear was of doughy or spongy consistence, and in parts elastic. There was distinct pulsation, not very forcible or distensile, which raised it at each systole. A distinct humming bruit was heard on applying a stethoscope to the pinna; although hot, it was neither tender nor painful.

DESCRIPTION OF PLATE III.

Illustrating Mr. Eve's case of (so-called) Aneurysm by Anastomosis of the Ear.

This Plate represents the Pinna of the Right Ear affected with (so-called) Aneurysm by Anastomosis. (Page 88.)

West, Newman & Co chr lith.

The posterior auricular and temporal arteries were much enlarged and pulsated forcibly, but the morbid change did not extend beneath the surrounding integument. The right common carotid artery pulsated more forcibly than the left; when it was compressed the ear became paler, smaller, and hung down soft and flaccid.

The patient was fairly nourished, but pale. The pulse at the wrist was small and feeble.

Operation.—The ear was removed by an incision around its attachment, including a wide area of integument.

The supplying vessels were held by assistants, and very little blood was lost.

The patient was able to get up on the eleventh day after the operation.

I injected the auricle with carmine and gelatine by applying ligatures along the cut surface after inserting canulæ into the largest arteries.[1]

The supplying vessels were numerous and of large size, one of the branches of the posterior auricular being nearly as large as the radial; their walls were extremely thin. The vascular growth involved both the skin and subcutaneous tissue.

Microscopic sections showed numerous arterioles of various sizes, giving off capillaries which anastomosed and formed a close and more or less uniform network throughout the tissue (see Plate XVIII, fig. 3). The capillary network extended into the corium. The walls of the arterioles were extremely thin in proportion to the size of the vessels, and composed of endothelium, supported by a layer of condensed connective tissue. The walls of the capillaries were composed of endothelial cells, the nuclei of which were unusually obvious, and in some instances of embryonic cells. In many places a new formation of capillaries in the following manner was observed: continuous with the endothelial cells of the capillary wall, delicate filaments of protoplasm, containing at intervals spindle-shaped nuclei, were seen extending between neighbouring capillaries. Fine processes of protoplasm were also observed projecting from the capillary walls. This mode of development of blood-vessels agrees with the observations of Stricker and Arnold.

The connective tissue of the growth was loose, and contained numerous round and some spindle-shaped cells.

[1] The specimen is preserved in the St. Bartholomew's Hospital Museum, Series xxxv, No. 154.

The epithelium of the skin of the pinna was increased in thickness, and the inter-papillary processes of the Malphigian layer were generally much enlarged, in many places extending deeply downwards as branched columns of epithelium. The sebaceous glands were also much enlarged.

This hypertrophy of the skin was probably due to increased blood supply.

Remarks.—The naked-eye and microscopic appearances indicate that all the factors forming the circulation were increased in size and number, but the morbid process apparently depended on the enlargement and multiplication of the minute arterioles, and especially the capillaries; the enlargement of the supplying vessels being probably due to the morbid growth of the smaller ones.[1] Cases of aneurysm by anastomosis of the auricle are placed on record by Sir J. Paget,[2] Mr. Prescott Hewitt,[3] B. Travers, junr.;[4] and four cases are referred to by Dr. L. Gosselin.[5]

The case related agrees with the majority of these in the preexistence of a congenital tumour, probably nævoid, and in the period of life at which the disease became formidable.

I have made sections of the ear described by Sir J. Paget, and find that the morbid process depended principally on a dilatation of the arterioles, which are seen as large sinus-like vessels; the capillary anastomosis in the sections I have cut is neither widespread nor abundant. A portion of the tumour had, however, in this case been ligatured.

Dr. Gosselin[6] states that, in the cases of vascular tumours observed by him, which were preceded by a nævus, this ultimately disappeared; and the growth he thought was formed by enlarged arterioles in the subcutaneous tissue, the vessels of the corium being unaffected.

The specimen, however, under consideration consisted essentially of a close capillary anastomosis, extending into the corium, which not improbably was a direct growth from the nævus.

April 20th, 1880.

[1] *Vide* Brodie, 'Med.-Chir. Trans.,' vol. xv, p. 177.

[2] 'Lectures on Surgical Pathology,' p. 581. Specimen preserved in the Museum of St. Bartholomew's Hospital.

[3] 'Lancet,' 1857, vol. ii, p. 496.

[4] 'Lancet,' 1858, vol. i, p. 399.

[5] 'Arch. Gén. de Méd.,' 1867, p. 641.

[6] Op. cit.

13. *Malformation of the heart; stenosis of the pulmonary artery; aorta communicating with both ventricles.* (*Card specimen.*)

Exhibited by T. B. PEACOCK, M.D., and T. BARLOW, M.D.

THE subject of this case was a boy, under the care of Dr. Barlow, at the Great Ormond Street Hospital for Children. He was healthy at the time of birth, but was observed soon after to be very dark coloured when chilled. This darkness increased till he became quite cyanotic. The parents and three other children were healthy, but the mother had had two attacks of rheumatic fever, the first of which occurred about twelve years before the birth of the child. When the child was a year and ten months old it was taken to Dr. Peacock at the desire of Dr. Barlow. It was then decidedly cyanotic, the extremities being very livid and the lips quite black. A systolic whiff was heard on the left side of the upper part of the sternum. The child died, when about three years old, of scarlet fever.

The heart is of large size for the age of the subject. The sinus of the right ventricle is large and its walls thick, the infundibular portion of the ventricle is very small, and the orifice of the pulmonary artery is decidedly constricted. There have been apparently only two semilunar valves at the orifice of the pulmonary artery. The left ventricle is natural, but there is a large deficiency at the upper part of the septum of the ventricles, above which the aorta arises, so that it communicates almost equally with the two ventricles. The ascending portion of the aorta is large. The ductus arteriosus is impervious and the foramen ovale is closed, except that the fold is imperfect at the upper part, so as to leave a small opening through which the cavities of the auricles may have communicated. *Nov. 18th*, 1879.

14. *Malformation of the heart; absence of the pulmonary artery.* (*Card specimen.*)

Exhibited by T. B. PEACOCK, M.D., and W. CASH REED, M.B.

THE case occurred in the practice of Dr. F. C. Turner, at the North-Eastern Hospital for Children.

When first seen by Dr. Reed, on May 11th, 1879, the child was nine months old. It was then deeply cyanosed, had shortness of breath, and the fingers were clubbed. He was stated to have been blue from birth. Occasionally, at the end of inspiration, and in the

interval before expiration, a distinct blowing murmur was heard, and this continued to be sometimes audible during the remainder of the child's life. On the 4th of September he was much worse than he had been. His eyelids were œdematous, his lips parched and cracked, and the tongue coated and dry, and there was some ulceration of the fauces. He died on the 10th of September, when somewhat less than thirteen months old.

The heart is large for the age of the child, the right ventricle being especially large and its walls thick. The septum of the ventricles is largely deficient at the upper part, and the aorta arises above the deficiency, so as to communicate about equally with the two ventricles. In the preparation there is no remains of the pulmonary artery, and the aorta is cut off short, but in a portion of the vessel, apparently the arch, removed separately, there is a large trunk, which divides into two branches, and apparently represents the ductus arteriosus, and was probably the means by which the blood was transmitted to the lungs. The coronary arteries arise, as usual, from the sinuses of Valsalva, and the vessels given off at the arch are natural. The foramen ovale is closed.

November 18*th*, 1879.

15. *Congenital malformation of the heart in a girl æt.* 13; *transposition of the pulmonary artery and superior cava; incomplete septum ventriculorum; patent foramen ovale; constriction of pulmonary artery and mitral orifice. Aorta arises from the left ventricle, but receives blood mainly from the right. Ductus arteriosus is closed.* (*Card specimen.*)

Exhibited by H. Radcliffe Crocker, M.D.

The *heart.*—The transverse diameter nearly equals the longitudinal. The *foramen ovale* is patent, allowing free communication between the auricles. The *tricuspid orifice* is normal, but the edges of the valve are slightly thickened. The cavity of the right ventricle is large, about the size of an average hen's egg. The wall varies from $\frac{1}{4}$ in. to $\frac{1}{3}$ in. thick. At the top, in the position of the undefended space the *septum ventriculorum* was largely deficient, and a large canal, one inch long, formed by the posterior walls of the left auricle and ventricle, leads from the right ventricle to the orifice of the aorta. The *superior cava* opens into the left auricle. The *mitral orifice* is slightly constricted, measuring $\frac{7}{10}$ in. in diameter, $2\frac{3}{10}$ in. in circumference. The valve is thickened, but competent; the ventricular wall is $\frac{1}{3}$ in. thick; the cavity small, about the size of half a walnut. The *aorta* measures $2\frac{6}{10}$ in. in circumference, and comes off at the left posterior part of the left ventricle, and directly in front of it arises a *constricted pulmonary artery* $1\frac{7}{10}$ in. in circumference. In the *left ventricle* the pulmonary opening

is separated from the aortic by a fleshy septum ½ in. thick, and the orifice is constricted so as to just admit a No. 8 catheter. Looked at from above, the valves can be seen to be united into a cone, and there is a deep *cul-de-sac* all round it. The *ductus arteriosus* is closed, but admits a probe for a short distance from the pulmonary artery.

Lungs.—Right consolidated throughout, but less in the posterior part of the middle lobe. The upper lobe was completely excavated by an anfractuous cavity, the lower œdematous, easily lacerable, and studded with tubercles. *Left* similarly affected, but the process was less advanced; there was a cavity the size of a walnut at the apex; caseous spots the size of a pea on the posterior surface of the lower lobe. The rest of the lung was studded with tubercle, but was not so airless as the right.

History.—Maud A—, an orphan, æt. 13, was admitted into the East London Hospital for Children, under Dr. Donkin, on October 23rd, 1879, and died on October 24th. She had been ill since birth, had had several attacks of profuse hæmoptysis, and had frequently seemed on the point of death. She was, however, able to walk into the ward looking pale and emaciated; breath rather short, and slight lividity. Although lying quietly in bed, the dyspnœa and lividity increased rapidly after admission, and she died within twenty-four hours. The *physical signs* in the lungs were those of consolidation and cavities at both apices.

Heart.—The impulse was visible and palpable over the whole cardiac area; the lowest left limit of the impulse was in the fifth space just below the nipple. The cardiac dulness extended to two inches to the right of the sternum, and this part of the cardiac area was mapped out visibly by marked inspiratory recession of the intercostal spaces, ceasing abruptly at the limit of cardiac dulness. Owing to the râles and the excited action of the heart precise auscultation was impossible, but accentuation of the second sound at the base, and a presystolic murmur heard inside the nipple line were noted. *November 18th*, 1879.

16. *Complete occlusion of aortic orifice by a fibrinous and calcareous mass; perforation of one of the aortic valves.* (*Card specimen*).

Exhibited by H. Radcliffe Crocker, M.D.

Post-mortem.—Heart globular in shape. The left ventricle was considerably hypertrophied. The tricuspid and mitral valves were healthy. The aortic orifice was completely occluded by a fibrinous and calcareous mass about the size of a hazel nut, which adhered to the valves; one of the valves had a perforation in it of a quarter of an inch in diameter, by which alone the blood reached the aorta. There was a line of atheroma above the valves. A considerable quantity of fluid was present in the serous cavities.

Lungs.—Lower lobe of left and half lower lobe of right collapsed.

Liver tough and enlarged.

Kidneys.—One had an infarct three quarters of an inch in diameter at the base.

Spleen normal.

History.—Admitted to East London Hospital for Children under Dr. Eustace Smith. Died on September 11th. Family history good. Seven other children well.

Previous history.—Born healthy. When fourteen months old had measles and diarrhœa, with frequent pain in abdomen, in epigastric region. Has not suffered from cough, dyspnœa, or œdema.

On admission.—Face pale, but no lividity or œdema. Superficial veins full. Fingers clubbed. No cough, but frequently cries out "Oh, my stomach," pressing her hand to epigastrium. Pulse regular, 96; resp. regular; temp. 100° F.

Physical signs.—Heart's apex beats behind the fifth space three quarters of an inch outside nipple line; cardiac dulness extends up to second rib at lower border. All over the cardiac region a very high-pitched systolic murmur is heard, loudest at the base at mid-sternum opposite third left costal articulation. The murmur diminishes in intensity and pitch towards the apex. There was also a diastolic murmur in the same situation. There was visible pulsation of the carotids in neck.

Lungs.—Some dulness at the left base with bronchophony.

On August 23rd (three days after admission) she had a fit. Another on the 24th and 25th.

On 29th the diastolic murmur had become inaudible.

November 18*th*, 1879.

17. *Fibro-cretaceous ring surrounding the heart in the situation of the auriculo-ventricular sulcus.* (*Card specimen.*)

Exhibited by WILLIAM EWART, M.B.

THE specimen was removed from the body of a man, æt. 64, who died in St. George's Hospital from hepatic cirrhosis and chronic pneumonia. He had suffered from rheumatic fever fifteen years previously.

The pericardial surfaces were found to be strongly adherent over the middle zone of the heart, and in the thickness of the adhesions a considerable amount of calcareous deposit was discovered. A broad, rigid belt was thus formed around the heart; the circle was complete with the exception of an interval of about half an inch which was free from calcification, in the situation of the descending branch of the left coronary artery. The width of the ring varied between $\frac{3}{4}''$ and $1\frac{1}{2}''$; its thickness was slight at the margin, but considerable in the middle. The external or pericardial surface was

tolerably smooth and clothed with fibrous tissue; the internal or cardiac surface of the deposit was very uneven and tuberculated. The heart-fibre was protected from this rough contact by a quantity of soft fat, the greater part of which has been removed by dissection. The heart was somewhat atrophied.

December 16*th*, 1879.

18. *Intra-cardiac aneurysm at the root of the aorta, opening into the right auricle.* (*Card specimen.*)

Exhibited by WILLIAM EWART, M.B.

THE patient, æt. 36, had served in India; a first attack of rheumatism in 1878 left a liability to occasional cardiac pain and to palpitation and dyspnœa of exertion. These symptoms became constant at the beginning of 1877. At time of first admission into St. George's, in Nov., 1877, the præcordial dulness was greatly enlarged, and a rough systolic murmur was audible over a large area; the relief obtained from rest and medication was temporary. When readmitted in May, 1878, his symptoms were—epigastric fulness, epigastric and interscapular pains, pulsation over the whole præcordium, a double murmur at the base of the heart, the systolic murmur being audible as low as the abdominal aorta. The interscapular pain became intense, and death occurred late in June, 1878, from increasing dyspnœa and exhaustion.

Immediately below the point of junction of the two posterior aortic flaps was found a circular opening nearly three quarters of an inch in diameter, leading into the sac of an aneurysm. The aneurysm expanded at once into a rounded, slightly elongated cavity, extending as far as the right auricle, which was pushed bodily backwards; bulging upwards under the tip of the right auricular appendix, which was separated at its base from the origin of the large vessels; and ending in a somewhat flattened projection into the right auricle, half way between the orifice of the inferior vena cava and the auricular appendix. A small circular hole, measuring less than one quarter inch in diameter, was found in the centre of the intra-auricular bulging, setting up a communication between the cavity of the aneurysm and that of the right auricle.

The posterior wall of the aorta at its origin will be seen to form a somewhat moveable partition between the aneurysmal cavity and that of the aorta. The two posterior valve-flaps were probably subject to the same movements, and, in addition, to a partial rise and drop according as the orifice of the aneurysm was opened or closed; these two flaps were much larger than normal. The aorta was very atheromatous and somewhat dilated at its root. The heart weighed twenty-eight ounces; its cavities were all considerably dilated, especially the left ventricle, without notable hypertrophy of wall. The auriculo-ventricular orifices were of large size.

As might have been surmised, the perforation of the aneurysm into the right auricle did not lead to any important clinical symptom. *December 2nd*, 1879.

19. *Aneurysm of mitral valve (two examples). (Card specimens.)*

Exhibited by NORMAN MOORE, M.D.

CASE 1.—A small rounded swelling on auricular surface of mitral valve, the orifice on the ventricular surface. Advanced disease of aortic valves, from a young woman who had had acute rheumatism. (St. Barth. Hosp. Museum, No. 12·154.)

CASE 2.—A swelling very near the edge of the mitral valve somewhat obscured by a large growth near it; but there is a small hollow sac partly filled with fibrin, and with opening on the side to which it protrudes; the ventricular. (St. Barth. Hosp. Museum, No. 12·156.) *March 2nd*, 1880.

20. *Intra-pericardial aneurysm of the aorta, opening into the left auricle. (Card specimen).*

Exhibited by WILLIAM EWART, M.B.

BENJ. LEWIS, æt. 44, a carman, was admitted into St. George's Hospital on Feb. 3rd, 1879, suffering from severe dyspnœa and præcordial pain, and from the symptoms of bronchitis. He had suffered from acute nephritis in 1868, and his heart at that period had been pronounced healthy. Since then, however, he had been subject to a dry cough, to occasional palpitations and to lumbar pains when lifting heavy weights. He had been able, nevertheless, to carry on his work until the beginning of his last illness in December, 1878. This was at first thought to be a slight bronchitic seizure; but early in January severe symptoms appeared. He became rapidly worse and died on Feb. 12th. During his stay in the hospital a systolic murmur was audible over the whole chest, culminating at the base.

At the *post-mortem* examination, firm adhesions were found in both pleuræ. The lungs were large from general emphysema, congested and slightly œdematous. The bronchi were greatly thickened and congested. The pericardium contained about 6 oz. of fluid. The heart, weighing about 18 oz., was slightly dilated and hypertrophied on the left side. The mitral and aortic valves were somewhat thickened at their free edge. The first part of the aorta was evenly dilated towards the right, displacing the right auricle backwards and outwards, but the left aortic wall was projected into an aneurysmal cavity irregularly spherical, and capable of admitting an ordinary Tangerine orange. The inner surface of the cavity

was rendered extremely uneven owing to secondary depressions. The growth of the aneurysm was chiefly in a direction to the left and upwards, forcing the left auricle backwards and outwards, and tilting upwards the bifurcation of the trachea. A small perforation had taken place from the bottom of one of the secondary aneurysms through the right wall of the left auricle. The endocardium of the left auricle was much thickened, in a degree comparable to the thickening of the mucous membrane of the bronchi. The spleen and kidneys showed the usual results of chronic congestion. The liver was superficially lobulated owing to irregular scars, but beyond this no evidence of syphilitic taint was obtainable.

The pressure from the aneurysm had been chiefly expended upon the left auricle and upon the air tubes; the symptoms as a result were chiefly pulmonary, and did not become urgent until six weeks prior to death. The giving way of the aneurysm into the left auricle was not marked by any important clinical event.

December 2nd, 1879.

21. *Aneurysm and rupture of aortic valve.* (*Card specimen.*)

Exhibited by H. G. Orlebar, M.D.

Taken from a patient, æt. 30, who died in Victoria Park Hospital. He was a clerk. Family history was good, with the exception of mother, who suffered from severe rheumatism.

History of case.—Never had rheumatism. No symptoms until four months before admission, when a severe cold was followed by palpitation, dyspnœa, short hacking cough, and precordial pain. On admission all these symptoms were present. Pulse was of the water-hammer character. Urine contained no albumen. There was no swelling of extremities. Cardiac dulness to right border of sternum. Epigastric pulsation. Apex beat diffused. At mid-sternum and base loud double murmur. Marked pulsation of carotids. Progress made under treatment. About eight weeks after admission cardiac symptoms recurred; double pericardiac friction heard. Thorax and extremities became œdematous, and patient died suddenly of syncope.

Post-mortem examination of heart.—Aorta slightly dilated. Left ventricle concentrically hypertrophied. Left aortic valve thin; sinus of Valsalva much distended. The right upper half of the valve was perforated by a round opening, which led into a sac, the walls of which being also perforated by several slit-like apertures. The left half was also perforated by a round opening. The attachment of this valve to right anterior one was much thickened.

Posterior valve thickened gradually towards the right anterior one; the frænum being absent at its upper half, allowed the junction

of these valves to fall over into or towards the ventricle. The right anterior valve was also perforated by an opening semilunar in shape. *November 18th*, 1879.

22. *Aneurysm of aortic arch rupturing into trachea.* (*Card specimen.*)

Exhibited by H. G. Orlebar, M.D.

The specimen was taken from a patient, a labourer, æt. 66, who was under treatment at Victoria Park Hospital, under Dr. Peacock. Patient was perfectly well up to six months before admission, then began to suffer from pains under sternum and dyspnœa.

On admission.—Tall, fine-looking man; marked fulness of veins of neck, face, and upper extremities; slight cough, occasional dyspnœa and difficulty in deglutition; stammering in speech; pain and fulness complained of behind manubrium sterni. Pulse 84, normal in force and rhythm; temp. normal; urine, sp. gr. 1030, no albumen.

P.S.—Slightly impaired resonance over and slightly to the left of manubrium. Apex of heart beating in fifth interspace, in the nipple line; no murmur; slight prolongation of first sound at base. No difference in radial pulses. Some deep-seated pulsation behind right clavicle. No pulsation in episternal notch.

Patient died suddenly of suffocative hæmoptysis one morning soon after waking up.

Post-mortem report.—Valves of heart normal, with exception of calcification of aortic. Just above aortic valves aorta commenced to dilate; at about two inches from them it expanded into a large sac (size of a cricket ball), the walls of which were lined, here and there, with partially decolorised laminated clot. At about one inch to left of left subclavian artery the saccular character suddenly terminated, the thoracic aorta forming a tubular aneurysm. The inner coats of aorta markedly atheromatous. The innominate arose from right anterior corner of sac, and left subclavian with left carotid from left anterior corner. Several smaller pouches, found at back of sac, one about the size of a walnut, projected back between the junction of the right and left innominate veins, the coats of the vein being thickened by its pressure; the end of this small diverticulum was adherent to right pleura, just above the root of right lung. Another smaller pouch pressed against the trachea, and from this smaller pouch the rupture had taken place (between the sixth and seventh ring, slightly to the left of the anterior surface), which had caused the suffocative hæmoptysis.

The heart was normal, neither dilated nor hypertrophied. Lungs emphysematous. Kidneys slightly granular. *May 4th*, 1880.

23. *Complete occlusion of the right division of the pulmonary artery, the result of disease; atheroma of the pulmonary artery.* (*Card specimen.*)

Exhibited by WM. EWART, M.B.

MATILDA BROOKS, æt. 38, was admitted into St. George's Hospital on January 13th, 1879. Two years previously she had suffered, for a period of about three months, from pain in the right side and palpitation, and for about a year previous to the appearance of these symptoms pain had been experienced about the right clavicle and at the side of the head, and she had complained of cough, dyspnœa, and palpitation ever since. She was stout and the subject of anasarca when admitted; the pulse was 106, the respirations 28; a loud systolic murmur was audible over the heart's area and at the angle of the left scapula. The dyspnœa increased, but no fresh symptom was recorded during her stay in the hospital. On March 25th cyanosis supervened, and the patient gradually sank until the 29th when she died.

Autopsy.—The right pleural cavity was filled with orange-yellow fluid, and the lung was adherent by a few bands to the chest-wall; its tissue was very œdematous and much toughened in texture. The heart (14 oz.) showed hypertrophy and dilatation of its right ventricle; the left ventricle had soft and rather thin walls. There existed some dilatation of the valvular orifices, and slight thickening of the tricuspid flaps, but in other respects the valves were normal. The pulmonary artery at its origin was somewhat dilated and much roughened by atheroma; its walls were noticeably thickened. A depression resembling a contracting scar marked the situation normally occupied by the orifice of the right division; but a mass of fibrous tissue had replaced the origin of this vessel. For a distance of one inch the channel was completely sealed by a tough fibrous plug, and buried in hardened tissue. Beyond this point the calibre and the distribution of the vessel were absolutely normal, but the fibrous plug protruded into the healthy channel for a short distance. A specimen taken from the dense mass which filled up the angle between the pulmonary artery, its right division, and the base of the heart, was seen under the microscope to consist of thick fibres and of groups of small fibroid cells. For an analogous instance, see 'Path. Soc. Trans.,' vol. xiii, p. 60. *December* 16*th*, 1879.

24. *Persistent left superior vena cava.* (*Card specimen.*)

Exhibited by W. J. WALSHAM.

THIS specimen was taken from the body of an adult male which was brought to St. Bartholomew's Hospital for dissection. The heart is about the normal size. The right vena cava is smaller

than natural but pursues its accustomed course to the right auricle. The internal jugular and subclavian veins on the left side unite, not to form the left innominate vein as usual, but to form a large vein —the so-called persistent vena cava—which opens directly into the right auricle. A small transverse branch stretches across, and in front of the great vessels at the root of the neck in nearly the usual situation of the left innominate vein, and unites the two venæ cavæ. The left vena cava passes downwards and in front of the arch of the aorta and the root of the left lung, and piercing the fibrous layer of the pericardium crosses in front of the pulmonary vessels, and reaches the side of the left auricle immediately in front of the appendix. Then turning backwards under the left lowermost pulmonary vein, it runs obliquely in close contact with the left auricle along the left auriculo-ventricular groove, and opens by a wide orifice into the right auricle a little behind and to the left of the opening of the inferior vena cava, *i. e.* in the usual situation of the opening of the coronary sinus. A slight ridge, formed by a reduplication of the lining membrane, exists at the entrance of the vein into the auricle, but there is no distinct valve. Above the transverse branch the left cava received the vertebral, internal mammary, and deep cervical veins, all of which were guarded by semi-lunar valves. The transverse branch received the inferior thyroid veins. Just above the reflection of the pericardium the left cava received a large branch which collected the blood from the five upper intercostal spaces, and communicated below with the third azygos vein.

Within the pericardium it received the great coronary and posterior cardiac veins.

The specimen is of interest, not because it throws any new light on the development of the great anterior veins, but because it is perhaps one of the most perfect examples of the malformation that has hitherto been recorded. *May* 18*th*, 1880.

IV. DISEASES, ETC., OF THE ORGANS OF DIGESTION.

1. *Gumma of tongue in hereditary syphilis (living specimen).*

By THOMAS BARLOW, M.D.

ELIZA G., æt. 6½, is brought to the Society for examination on account of a deep linear ulcer situated to the left of the middle line of the tongue in its middle third. The ulcer is now cicatrizing. Parallel to it and between it and the raphe is an ill-defined mass of deep induration about three-quarters of an inch long by a quarter of an inch broad.

Other noteworthy points about the child are deep linear scars around the mouth extending through the skin and mucous membrane, ulceration of the left half of the soft palate with some loss of substance, and extensive congestion of the epiglottis and false cords.

She has also some old linear scars extending backwards from the anus. The eyes now are normal and there are no signs of visceral or bone disease.

The history obtained is briefly that the child was born with "snuffles," and when fourteen days old had a rash which affected the feet, face, trunk and nates.

She began to suffer from her eyes when four and a half years old, and I have ascertained that at that period she attended Mr. Higgens, at Guy's, for three months with interstitial keratitis.

The "back of her throat" was first noticed wrong when she was six years old, and two months afterwards, *i.e.* four months ago, it was found that her tongue was sore. She lost her voice a few days ago.

With respect to other pregnancies, it is stated that the child before this was born dead at seven months, that this child was succeeded by a miscarriage, and that a subsequent child developed a

general rash soon after birth, which specially affected the hands, feet, and face, and left cracks of the lips.

Remark.—Deep ulceration of the soft palate is occasionally met with in hereditary syphilis, but I have never before seen in that disease deep ulceration of the tongue accompanied with what I presume is a gumma of the tongue.

The reason for giving so many collateral details as to the history is to establish that the case is one of inherited and not of acquired syphilis. *May* 18*th*, 1880.

---

2. *Epithelioma of the pharynx involving the larynx, trachea, and œsophagus.*

By T. Gilbart Smith, M.D.

The patient from whose body this specimen was taken was a married woman, æt. 55. She first came under my care in March, 1879, when she stated that for some eight or nine years she had been, on and off, troubled with pain about the throat, and that latterly this had much increased, especially toward the left side. She also complained of pain, which she described as rheumatic, about the back of the neck and shoulders. Her voice was hoarse, there was much cough with some expectoration, and slight pain on swallowing solids.

The fauces and larynx were congested, and on examination with the finger nothing was felt, but tenderness was present at the left side, where the tonsil was small and atrophied. No other abnormal physical signs were found, and her personal and family history revealed nothing specific.

For a time she apparently improved under treatment, but suddenly, in May, the above symptoms again returned with increased force; she began to lose flesh, and from this period she gradually grew weaker and more wasted.

For three days, in July, the secretion was for the first time tinged with blood, after which the throat felt more swollen.

She spent the summer months in the country, returning to London in October, when I again saw her, and found, for the first

time, an enlarged cervical gland lying beneath the left sterno-mastoid muscle. The hoarseness was great—aphonia almost complete. She suffered from increased difficulty in swallowing solid food, and the secretion, which she said "ran from her mouth," gave her much trouble night and day.

The tenderness on the left side of the pharynx was increased, and at the floor of the mouth, on that side, some induration could be felt.

On Oct. 11th she complained of several severe attacks of dyspnœa, and brought up blood "freely" with the secretion, which seemed to relieve her much. With considerable difficulty, owing to this secretion, which welled up and covered the mirror, an examination with the laryngoscope was made, and a growth was revealed, which appeared to push forward above the vocal cords, and conceal the greater part of the left cord. The origin of this could not be ascertained.

The breathing being stridulous and the attacks of dyspnœa urgent, tracheotomy was recommended as a necessity to obviate death from asphyxia, and as an essential factor in any subsequent operative treatment that might be deemed advisable. She was accordingly admitted into the Royal Hospital for Diseases of the Chest on October 18th, when by the aid of the laryngoscope a swollen œdematous-looking mass was observed on the left side, smaller than before, extending half way across the opening of the glottis, and completely hiding the left vocal cord; in addition there was an irregular-shaped, flattened, movable tumour, somewhat resembling a second epiglottis, lying beneath the epiglottis and the tumour to the left; it presented an irregular and ulcerated surface, and apparently blocked the larynx, while now and then it rose up and revealed the right vocal cord beneath.

On October 14th Mr. Walsham performed tracheotomy without chloroform; it was borne well and gave great ease.

Mr. Pugin Thornton, at my request, kindly made the following note:

"On October 20th.—Cancerous mass arising from the left ary-epiglottic fold and arytenoid cartilage passing over to the right side, so that, with the larynx at rest, the right vocal cord is partially covered. On vocalisation the tumour, which presents at its right extremity the appearance of a horn, is raised, and the two vocal cords are seen. The right and left corners of the tumour are ulcer-

ated, also there is a speck of ulceration on the left of the epiglottis There is ulceration external to the left ary-epiglottic fold."

At Mr. Walsham's request Mr. Langton kindly saw the patient with him, and after due deliberation they considered that it was not a case suitable for operative interference.

Gradually she grew weaker, and a short attack of dry pleurisy of the right side still further enfeebled her. The larynx became swollen externally and thickened and tender to the touch about the thyroid bone, while on several occasions the food returned through the tracheotomy tube, showing the progress of the ulceration. The dysphagia, pain, secretion, and aphonia increased until her death, on December the 12th, which occurred at her home a few days after leaving the hospital, at her own wish.

At the autopsy, which was made by Dr. Hamilton Bland, permission only was given to examine the parts affected, and these are now exhibited.

At the termination of the pharynx and commencement of the œsophagus a large ulcerated cavity was found occupying the left side, and extending anteriorly to the right arytenoid cartilage, above and beyond the median line; posteriorly it encroached considerably upon the posterior pharyngeal wall. Above it was bounded by the ary-epiglottic fold, which was much ulcerated, and below its inverted edges were beneath the level of the cricoid. Its floor was deep, and contained the carious remains of the left wing of the thyroid bone and the cricoid cartilage, a third of the latter having disappeared, as also part of the left arytenoid cartilage.

The ulceration had eaten its way into the larynx, communicating with it through a small opening leading into the left sacculus, and also at the level of the cricoid cartilage it had worked a passage into the trachea. These openings were small, and surrounded by thickened everted edges. The parts covering the right arytenoid cartilage and the right half of the posterior laryngeal wall were involved in what was, without doubt, that part of the original growth which had not been overtaken with the process of self-destruction that was elsewhere at work.

This portion impinged upon the calibre of the pharynx forcing the food to pass to its right, and lower down at the commencement of the œsophagus there was considerable narrowing, indeed the stenosis was almost complete.

There was some thinning of the wall of the common carotid

artery, as it lay close to the outer side of the ulceration; no nerve changes were noted, nor was the enlarged gland in the neck examined.

My friend, Dr. Gabbett, has been good enough to make a microscopical examination, and he reports as follows:

"Sections vertical to the floor of the ulcer showed complete degeneration of the superficial part, which consisted wholly of *débris*, among which no distinct cell-forms could be recognised. Deeper, there was a layer of some thickness, made up of closely-packed small cells, in the midst of which a few scattered muscular fibres were seen to pass; and here and there were numerous collections of squamous epithelium, some of which formed characteristic 'nests' or 'globes.' Deeper still, in the part examined, there was a distinct floor of fibrous tissue. An enlarged lymphatic gland from the neighbourhood of the right common carotid was examined, and found to contain no epithelial elements. The mucous membrane of the tongue was healthy."

This specimen is exhibited, not as showing a rare form of disease, but as a good example of epitheliomatous ulceration in the lower pharynx, and as possessing some points of interest relative to the history of the illness, the position of the lesion, and its bearing upon the question of the removal of similar growths.

As recorded above, there had existed for many years some source of irritation in the throat giving rise to difficulty in swallowing with neuralgic pains about the neck. It is difficult to believe that this was from the first of a cancerous nature. It is far more probable that what had originally been some simple superficial inflammatory process, ulceration or perichondritis, finally became the seat of malignant growth. If so this change would appear to be of comparatively recent date, inasmuch as the most careful search, repeated on several occasions, revealed no evidence of any abnormal growth until a few months prior to her decease. The sudden onset of such tumours, their rapid increase in volume, and their quickly following self-destroying properties, are well illustrated by this case.

The marked symptoms of pressure, viz. the dysphagia and dyspnœa, which at one time were extreme, seem to be inconsistent with the present appearance of the parts; indeed, ulceration has done its work so well that but little remains of the original tumour.

Here is seen another instance of the preference shown by

epithelioma as well as other morbid growths to spread in the pharynx rather than invade the larynx or trachea.

Notwithstanding that large portions of the cartilages had been destroyed; that disease had eaten its way into the larynx and trachea, and had obliterated the left ary-epiglottic fold, yet the air-passages remained comparatively untouched. The explanation of this is to found in the fact that the arrangement of areolar tissue, blood-vessels and lymphatics, with which the pharynx is supplied, presents a soil highly favorable to the spread of cell-infiltration. In the larynx, on the contrary, the mucous membrane with its abundant elastic fibres, its separate lymphatic system and scanty vessels, render it but ill suited for the rapid advance of abnormal cell growth. And here it is noteworthy that the communicating sinuses above mentioned occur at points occupied by considerable masses of glands, adapted, therefore, to the invasion of the growth, viz. the sacculus laryngis, and the posterior wall of the larynx at the level of the cricoid cartilage.

That part of the tumour which had been observed encroaching on the glottis and concealing the cords has disappeared, and the larynx is only narrowed by the side pressure from without of the neighbouring lesion. To the right of the epiglottis the pharynx is dilated to allow of an enlarged channel on this side for food, but lower down, at the commencement of the œsophagus, this passage becomes narrowed and almost completely blocked by the growth as it presses from the left side, thus fully accounting for the difficulty in swallowing, which continued to the last.

February 17th, 1880.

---

3. *Ulcerations of stomach and duodenum.*

By Norman Moore, M.D.

1. *Simple ulcer of the stomach.*

The ulcer is on the posterior surface and lesser curvature of the stomach. It measures one inch and a half by two-thirds of an inch. The edge is thickened and overhanging, and the floor

irregular. Part of the floor is actually formed by the pancreas and on this part when fresh, two slightly raised blood-stained points were visible. On section these were found to be clots adherent in eroded points of the pancreatic artery. Except near these erosions, and in one other small spot, the surface of the ulcer is smooth, and healing seems to have taken place. The consequent contraction had constricted the stomach at the level of the ulcer so that an opening only just admitting the little finger was formed, the cavity of the stomach being thus divided into a small pyloric and a large cardiac part, each part of which when the body was opened was filled by a firm blood clot. The base of the ulcer was examined and showed no evidence of malignant disease.

Death was due to the hæmorrhage.

The patient was a woman, æt. 54, who was in St. Bartholomew's Hospital, under the care of Dr. Andrew. A year ago she had some pain in the abdomen after eating but recovered from it. For about four months before her death she had had uneasiness in the abdomen and gradually increasing pain after eating. She lost flesh slightly for a time and rapidly during the last few weeks of her life.

She frequently vomited her food, and three weeks before her death about half a pint of blood. At noon while sitting up in bed she suddenly gasped and fell back in a faint. She recovered sufficiently to speak but soon became weaker and died fourteen hours after her fainting.

2. *Simple ulcer of the stomach.*

The ulcer is on the anterior wall of the stomach, about one inch and a half from the pylorus: it extends across the lesser curvature, is almost circular, and measures nearly two inches across. The stomach is adherent to the pancreas, which, however, nowhere forms the base of the ulcer. The edges are thick and slightly overhanging. There is a smaller, shallow, and apparently healed ulcer of the same general character nearer the pylorus on the lesser curvature. The ulcer had caused a slight narrowing of the cavity of the stomach. The larger ulcer has two irregular openings with clean cut edges at the lower part of the base.

These were recent perforations, and death was due to consequent acute peritonitis.

The patient was a man, æt. 57, who was a patient in St. Bartholomew's Hospital, under the care of Dr. Southey. He had chronic pleurisy, and had suffered from vomiting for fifteen months before admission. He was greatly emaciated. He died suddenly after an attack of severe pain.

Shortly before these cases there was a third example of gastric ulcer at St. Bartholomew's which deserves mention with them.

The patient was a man, æt. 35, under the care of Dr. Andrew, for chronic peritonitis.

Post-mortem.—I found on the posterior wall of the stomach, close to the cardiac orifice, a healed ulcer one inch by one inch and a half.

This ulcer was firmly adherent to all the tissues behind the stomach. Its edges were thickened, and there was some fibrous tissue between its floor and the pancreas and spleen, but it was, no doubt, the origin of the chronic peritonitis which ultimately killed the patient by exhaustion after the ulcer itself had healed.

There was an obscure history of gastric pain for some years.

This case seems worth noting, for Dr. Ludwig Müller, in his admirable book 'Das Corrosive Geschwür im Magen' (1860), does not mention chronic peritonitis as a fatal termination of ulcer of the stomach, and although Brinton suggests it vaguely he does not mention a case. The methods of termination in the other two cases, hæmorrhage and perforation, are, of course, common.

3. *Simple ulcer of duodenum.*

The ulcer is a small oval one with overhanging edges on the anterior wall of the duodenum, and one inch below the pylorus.

In its base is a perforation of nearly the whole size of the ulcer, and with clean cut edges.

The cause of death was acute peritonitis.

The patient was a gardener in Sussex, and was under the care of Mr. F. A. Hall, of Lewes, who was so kind as to give me the specimen.

The gardener was about twenty years of age, and for several weeks had pain about two hours after taking food. After a meal of pickled salmon an attack of violent pain came on; he went to bed, became worse and worse, and died in about fourteen hours.

4. *Gall-stone ulcerating into duodenum.*

The specimen shows several gall-stones embedded in a thickened gall-bladder. Above one of them may be seen an ulcerated passage by which a small stone had found its way out of the gall-bladder and through the duodenal wall into the duodenum.

The patient was a nurse in St. Bartholomew's Hospital, who had been dyspeptic for some time, but without jaundice or other marked symptom.

Sudden vomiting came on, it could not be controlled, and she died in twenty-four hours.

Statistics of ulcer of the stomach.

Since October, 1867, there have been at St. Bartholomew's, in addition to those above described, 12 fatal cases of ulcer of the stomach. Of these 10 were in men, and 2 in women.

The causes of death were:

Perforation	5
Exhaustion	2
Fistulous opening into liver and lung	1
Hæmorrhage	2
Died of Phthisis	2

Of ulcer of the duodenum there has been but one fatal case in these thirteen years.

The particulars are given in the table on the next page.

Table of Fatal Cases of Ulcer of the Stomach, 1867—1879.

Sex.	Age.	Position of Ulcer.	Description of Ulcer.	Complications.	Cause of Death.
M.	36	Near pylorus	Crown size, clean cut edges	...	Perforation.
M.	19	Greater curve near pylorus	Shilling size, rounded edges	...	Hæmorrhage.
M.	47	Near pylorus	Crown size, edge clean cut	...	Exhaustion.
M.	47	Pylorus	Of crown size, with soft everted edges	...	Died of phthisis.
M.	41	Pylorus	Large, edges thick	Phthisis	Died of phthisis.
M.	52	Pylorus	Edges raised and everted	(No cancer)	Exhaustion.
M.	46	Lesser curve, pylorus (2)	Shilling size, edges of both thickened	...	Perforation.
F.	47	Bk. of stomach	Shilling size	...	Sinus in liver to lung (gangrene).
M.	57	Cardiac end	Size of groat, edges sharp	...	Hæmorrhage.
M.	19	Near pylorus	Shilling size, sharp edges	...	Perforation.
M.	40	Near pylorus	Groat size, conical edges thick and rounded	...	Perforation.
F.	46	Posterior wall	Shilling size	...	Perforation.
		Ulcer of duodenum—one case only.			
F.	57		Very large.		Death from perforation (much putrified).

It will be observed that this table is opposed to the greater frequency of ulcer of the stomach in women. The advanced age of most of the patients also deserves remark, all the ages in the table but two being beyond the period of most frequent occurrence, as shown by the 199 cases tabulated by Brinton.

February 21st, 1880.

4. *Volvulus of the ileum.*

By W. Harrison Cripps.

The specimen in this case was taken from the body of an infant child, who was brought to the hospital on the third day after birth with obstinate vomiting, and having had no passage of fæcal matter by the anus. The abdomen was much distended.

On examination the little finger could be only introduced a short distance within the anus, which appeared to end in a cul-de-sac. It being considered to be a case of congenital deformity, Littré's operation in the right groin was performed, the portion of the intestine that presented itself being opened and stitched to the wound. The patient died on the third day from peritonitis.

The interest of the case lies in the condition found upon the *post-mortem* examination.

The rectum, the whole length of the colon, and a couple of feet of the ileum were perfectly normal, though firmly contracted into a muscular cord, no thicker than a pipe-stem. Above the spot mentioned the small intestines were greatly distended. The distended portion of the intestine ended abruptly by a loop of the bowel making a complete twist upon itself, the loop being folded over in such a way as to cause complete obstruction to the calibre of the bowel. The displacement was remedied at once by untwisting the loop. Pressure on the distended intestine above immediately caused the contents to pass into and distend the previously impervious portion of the bowel. The undilated portion of the bowel below the seat of obstruction was much smaller than it should have been at the full period of fœtal life, a condition probably accounted for by the absence of all meconium from its interior, which would have stimulated its growth. The practical interest in the specimen lies in the difficulty that may arise in the diagnosis between such a condition and an imperforate anus, and the fact of its being probable that manipulation through the abdominal walls might have untwisted the loop during life, since the reduction was so easily accomplished in the *post-mortem* room. *May 4th*, 1880.

5. *Imperforate rectum.*

By W. Harrison Cripps.

The infant from whom the specimen was taken was brought to the hospital on the third day after birth with vomiting, abdominal distension, and no passage of fæces from the bowel. Examination disclosed a well-formed external anus, which, however, terminated in a cul-de-sac three quarters of an inch from the orifice. An operation was advised, but declined by the parents. One month later the infant was again brought to the hospital, little alteration having occurred since the first occasion. The abdomen was rather more distended. The child had taken nourishment well during the whole time, with occasional fæcal vomiting, but nothing whatever had passed by the rectum. The parents consented to an exploratory operation. The finger, thrust against the cul-de-sac at the termination of the anus, felt a soft elastic swelling. A sharp-pointed director was passed through the cul-de-sac upwards towards the swelling, and failed to do more than to give exit to a few drops of serum.

The infant was unrelieved by the operation, and died a few days later with symptoms of acute peritonitis.

The *post-mortem* examination disclosed a large quantity of pus in the peritoneal cavity.

The rectum was found to terminate in a large bulbous extremity, the cul-de-sac of which was half an inch from the blind termination of the anus. The peritoneal pouch completely covered the anterior portion of the dilated rectal extremity. The puncture made by the director through the cul-de-sac of the anus had passed, not into the dilated rectum, but through the apex of the peritoneal pouch, and hence upwards parallel with the bowel. It is worthy of notice that had a puncture or dissection been made through the posterior portion of the anal cul-de-sac, and then upwards and backward towards the sacrum, the dilated rectum might have been reached without opening the peritoneal cavity.

That the infant should have lived thirty days without a perceptible falling off in condition, with the mouth as the only means of fæcal evacuation, is a matter of considerable physiological interest.

May 4th, 1880.

6. *Cancer of the sigmoid flexure; gangrene of the bowel (transverse and descending colon); peritonitis.*

By JAMES F. GOODHART, M.D.

A WOMAN, æt. 54, was admitted under Dr. Wilks, November 28th, 1879. She was married, and had had a family. She had always had good health, but was subject at times to constipation, and at such times had to stay in bed with abdominal pains, but from these she would soon get well. She described her fatal illness thus: that she got up one morning in her usual health, and soon after breakfast was seized with severe abdominal pain. A medical man administered a warm-water enema as there had been no action of the bowels for two days, but no relief to the pain followed, and she was admitted the day after in a collapsed moribund state from peritonitis.

At the inspection there was general peritonitis, the lymph causing some of the coils to adhere firmly. There was also some old adhesion of the omentum in the right inguinal region. There was no twist of the bowel, but what struck me at once was that the transverse and descending colon were of a deep ecchymosed black colour, and flaccid in appearance. No part of the intestine was more than moderately distended. Opening up the bowel all was healthy, till the commencement of the transverse colon, where there appeared first a superficial gangrene of the mucous membrane in a small circular patch one third of an inch in diameter; below this came some larger elongated sloughs like it, all superficial and sharply defined, and then quite suddenly the intestine changed into a black œdematous gangrenous condition throughout, and so continued, without any healthy tissue whatever, till the sigmoid flexure was reached. Here there came a circular ulcer extending round the bowel, with a thick raised everted edge, associated with considerable narrowing of the part and external puckering. The gangrene did not extend quite to the ulcer, but to about an inch above it, where it ceased almost as abruptly as it began. The vessels of the omentum and mesentery were followed out, but no plugs could be found, nor was there any evidence of twisting of the bowel, so I was forced to the conclusion that the disease was due to the stricture and distension. But inasmuch as there was no evidence of any remarkable distension, the explanation is not quite satisfactory,

and the history, if it be worthy of credence, does not corroborate this, and the case may possibly have been an acute colitis from some irritant food retained by the stricture. Had there been no stricture the food would, on this hypothesis, have passed on as a diarrhœa, whereas under circumstances which existed it remained to set up an enteritis. The intestines were moderately full of liquid yellow fæces of ordinary appearance. No blood.

The other viscera were all healthy.

I record this case that it may go with two others already in our 'Transactions,' one by Mr. Morrant Baker, vol. xxvii, and the other by Mr. Doran, vol. xxx, in which, after intestinal obstruction, there had come ulceration. Such a thing is indeed not uncommon, and we are all probably familiar with the fact that occasionally, in obstructive disease of the sigmoid flexure, large perforating ulcers are found in the cæcum. But the pathology of such cases is by no means clear. I believe that one of two explanations must be given to such an occurrence. Either the over-distension leads to stretching and narrowing of the blood channels, and so to gangrene, or else the material retained acts as an irritant and leads to ulcerative inflammation. *February 17th*, 1880.

---

7. *Congenital occlusion of the duodenum above the common bile-duct.*

By James F. Goodhart, M.D., for George Eastes, M.B.

Amy W—, a full-time child, was born at 8 p.m. on December 9th, 1879. Her mother had advanced phthisis with enlargement of the thyroid body, and died with laryngeal spasm a month after its birth.

The infant was well nourished, and of ordinary dimensions. Within an hour of its birth it vomited as much as a tablespoonful of clear white mucus, and from this time till its death, on December 18th, it vomited constantly both the milk and water given as food, and sometimes mucus only when nothing had been administered.

On the fourth day of life the vomit began to be tinged with black material resembling "coffee-ground vomit," which gradually increased

in quantity until during the last day of life. The vomit consisted entirely of this material. Gradually increasing emaciation, with, at last, a few epileptiform attacks and exhaustion, terminated life 126 hours after birth. On three or four occasions a little meconium-like material was passed per anum. The abdomen, at first natural in appearance, partook of the progressive general wasting. It was considered from the first that the baby had a congenital occlusion of the pylorus or adjacent portion of the bowel.

The inspection was made by Mr. George Eastes, assisted by Mr. Frederick Eastes.

The body was much emaciated, and the lungs, heart, liver, and kidneys were healthy. The abdomen was generally contracted, but at its upper part contained what looked at first like a distended stomach, that is, a hollow viscus, occupying the usual site of the stomach and resembling it in shape; it was 4 or 5 inches long, and 2½ to 3 inches in diameter at its centre, its widest part. It was somewhat narrowed by an hour-glass-like contraction a little to the right of its centre. When opened it was found to be filled with meconium, whilst the viscus itself consisted of stomach and all or nearly all the duodenum, both partly distended. The circular band, resembling an annular constriction, proved to be the pylorus. The intestine beyond the duodenum was quite empty and of a uniform size throughout, being about as thick as an ordinary goose-quill. A blunt needle being inserted into its upper cut end, and passed onwards towards the stomach, was prevented from entering the distended duodenum by a thin membrane, which closed the passage and appeared to be duodenal mucous membrane, and on the inner part of the wall of the duodenum at this site, viewed from the interior, was a slight circular depression, a sixth of an inch in diameter, but no communication whatever could be discovered between the distended duodenum and the contracted empty intestine below it. The opening between the two was quite closed. There were no signs of peritonitis. The hypogastric arteries and umbilical vein and foramen ovale were all patulous. The umbilical cord was still pendant.

Mr. George Eastes adds: It seems to me an inexplicable problem that for three whole days after birth the vomit consisted of clear uncoloured mucus or food, and that at the end of that time only it was tinged by meconium, which is usually found in the intestine before birth.

The occlusion would also seem to have occurred very early, as no signs of meconium was found at any part of the contracted intestine. This opinion may, if the friends are reliable, require modification, as they state that some meconium did pass per anum. I may also add that the parts have been dissected very carefully since, and that no trace can be found of any channel between the dilated duodenum above and the contracted intestine below. The contracted part ended in a fibrous cord, which became lost in the dilated coats above. Further, the circular depression which has been described above as marking the original site of continuation of the intestine appears to me very clearly to be a flattened-out papilla at the orifice of the common bile-duct, though I cannot now make even a small bristle pass along the duct.

The case is one of considerable rarity. None such are described in the 'Transactions,' and Theremin, in an article on congenital occlusion of the small intestine, in the 'Deutsche Zeitschrift für Chirurgie,' Bd. 8, 1877, has recorded only a few, although he has dealt with statistics of large dimensions. *February 17th*, 1880.

---

8. *A case of acute atrophy of the liver.*

By Samuel West, M.D.

The patient was a boy, æt. 6, admitted into St. Bartholomew's Hospital, with the following history:

The child had been in good health till seven days before admission, but was seized then suddenly with sickness and pain in the abdomen, and at the same time the eyes and cheeks became somewhat puffy. There had been no illness in the house and there was no cause for the attack known. Subsequently, it transpired that this patient had been playing in the streets with another child, and that both are supposed to have eaten something which had been dropped out of a herbalist's shop. This was uncertain, but the other child, it appears, was also seized with illness, and, as it was stated afterwards, had died with somewhat similar symptoms.

Since the commencement of the attack, the pain and sickness

had continued, though with less severity. There had been but little sleep during the week, and for the last two days slight delirium at night.

October 9th.—The child lay in bed upon one side or the other, the left by preference, with the knee drawn up on abdomen, the head thrown back, and the hand pressed under the temple, the position suggestive of meningitis. His sleep was restless, disturbed by moaning, and occasionally by attacks of shrieking. The *complexion* pale, and the face and legs slightly œdematous. The *pulse* was irregular, and so rapid that it could not be counted, many of the beats not reaching the wrist. *Heart-sounds* hurried and excited, with considerable reduplication at the base, but no murmur. *Respiration* rapid and irregular. *Abdomen* somewhat tense and resistant; complaint made of pain especially over the hepatic region, which was increased by palpation. Slight *ascites*, slight cough and a little bronchitis, but no other signs in lungs. Urine 1028, with a slight trace of albumen, and a copious deposit of yellowish brick-dust urates. The *liver* was much increased, extending in the right line from the upper border of the fifth rib to half an inch above the umbilicus. Slight œdema of the eyelids and cheeks, and of the legs and loins. Temp. 100° at midday; 101° at 10 p.m.

10th.—No change. Temp. in morning, 98·2°; in evening, 102·4°. Restlessness greater. No albumen in urine.

11th.—Temp. 98·6° in morning; 102.2° in evening. Liver smaller. Vomited once a small quantity of dark fluid, which deposited a black sediment, probably due to altered blood, and passed also a small black motion.

12th.—Hardly slept at all during night; no delirium. Temp. 99·6°; evening, 100·6°. Four small motions. Liver still decreasing. Resp. 70; pulse 160. Troublesome cough.

13th.—Much paler; liver much reduced. Temp. 100·4°; evening 99·6°. Vomited some porter-coloured fluid; four small motions. Urine examined; a high percentage of urea 3·6. No leucin or tyrosin.

14th.—Vomited some more porter-coloured grumous fluid. Four small motions. Temp. 99·8°. Liver rapidly decreasing, hardly now below ribs. Temp. in evening, 97·4°, yet evidently moribund.

15th.—Died quietly at 1 p.m.

The course of the case was marked by increasing prostration, with rapid decrease in the size of the liver, so that on the

14th, that is, in five days, it hardly came below the ribs. The pulse remained too rapid to count. The respirations about 70. The breathing and cough most troublesome. Great restlessness and want of sleep, and slight delirium at times. For the last four days the child vomited some porter-coloured fluid and was troubled with slight diarrhœa; the motions also contained once some blood. The temperature varied from normal in the mornings to 102·5° in the evening. The trace of albumen disappeared from the urine, which contained a high percentage of urea (3·6), but leucin or tyrosin were absent. Jaundice was absent completely throughout.

The case was diagnosed as one of acute atrophy of the liver of unknown cause.

On *post-mortem* examination the body was not jaundiced, but highly œdematous.

Lungs were both nearly solid, airless, and non-crepitant; on section granular, firm, and of a colour varying from grey to deep red. There were no clots in the vessels.

The right side of the heart contained numerous white softening thrombi, chiefly in the auricle and under the columnæ carnæ. No endocarditis.

Spleen smaller than natural.

Stomach filled with brown grumous fluid. Mucous membrane of stomach and intestines not abnormal to naked eye.

Kidneys pale, cortex dull opaque white, and structure indistinct. Medulla congested; cells found on microscopical examination to be very fatty.

Liver firm and resistant. On section the lobules were opaque and pale in colour at the circumference, and deep red in the centre. The organ weighed only 500 grammes (about sixteen ounces).

The microscopical appearances were as follows:

Under a low power the lobules appear marked off into two zones, an outer, which is opaque and stains readily; an inner, which is semitransparent and almost unstained. The latter zone forms nearly five sixths of the whole lobe. With a higher power the cause of this difference is explained by the gradual conversion from without inwards of the liver-cells into fat-cells, and to the subsequent absorption of the fat and disintegration of the cells.

Externally the liver-cells are granular and opaque; they are there seen to contain a few fat globules, which become more numerous,

and finally coalesce, until the original hepatic cell becomes converted into a fat cell, with a beautiful distinct peripheral nucleus, and a narrow band of protoplasm round the fat-drop. This fat drop then gradually disappears, probably by absorption, as no fat-drops are seen in the interstitial tissue or anywhere in the lobule out of the cells, and the cell shrinks to a granular opaque body, which persists in part as a dark irregular granule.

Nowhere is there any increase in connective-tissue cells or fibres beyond that, towards the centre, the disappearance of cells brings out into relief the normal connective-tissue framework of the lobule.

For the purpose of comparison a section was shown from a case of phosphorus poisoning, in which the microscopical appearances were identical, but the clinical history of the case was one of malignant jaundice. The diagnosis of acute atrophy of the liver was thus confirmed by the *post-mortem* examination, though the case was clearly not one of ordinary acute yellow atrophy, differing as it did from this disease in the entire absence of jaundice and of the characteristic ordinary changes, and in the occurrence of high temperature. But it is probable that under the clinical term of acute yellow atrophy of the liver we associate together a number of essentially different diseases. And it may be that the yellowness of jaundice is an accidental, and not an essential part of the affection. *May 4th*, 1880.

---

9. *Cirrhosis of the liver in a child.*

By Frederick Taylor, M.D.

[With Plate IV].

Frederick W. G—, æt. 5, was admitted into Guy's Hospital June 9th, 1876. Family history good.

The patient has generally been healthy, but has had measles, scarlatina, and hooping-cough. He began to have jaundice four months ago, and this was followed by vomiting and relaxation of the bowels; the motions were very pale, but the urine was yellow. For

five weeks he attended as an out-patient and improved, but the symptoms reappeared after two months, and he was admitted under Dr. Pye-Smith. He was well nourished, with warm dry skin, of a brownish-yellow colour; the eyes were large and bright, with yellow tinge of the conjunctivæ. The heart and lungs appeared normal. The abdomen measured 24 inches in circumference at the lower border of the ribs. The liver extended 3¼ inches below the ribs on the right side, and 1½ on the left. The edge was thin and flexible, and presented two notches, corresponding apparently to the gall-bladder and umbilical vein. There was a slight elevation on the convex surface, somewhat to the right of the middle line; no fluctuation; no ascites. The spleen is very much enlarged; it does not come forward so much as usual, but the colon is resonant behind it. He was ordered Pulv. Hydrarg. c. Cret. gr. ij, Sacch. Alb. iij, noct. sum.

A slight eczematous eruption on the skin was treated with Unguentum Zinci. No essential alteration took place, and he went out on July 1st.

For the next two months he remained, at times, very yellow, and as he got gradually weaker he was readmitted on September 5th, under my care. On this occasion the skin had a dusky brownish-yellow colour, and the conjunctivæ were tinged yellow; tongue moist and covered with brownish fur; bowels regular, the motions being light but not white. The abdomen was much enlarged, and the liver was felt 3½ inches below the margin of the ribs. The splenic dulness reached from the seventh rib to about the lower margin of the eleventh. There was no ascites. The urine had a sp. gr. of 1026, contained bile pigment, but was free from albumen. On the lower lip was a small abrasion, from which blood spurted occasionally. Temp. 100·2°; pulse 96.

During the next few days he lost a good deal of blood from this spot. His facial eczema was treated by zinc and mercury ointments. On September 15th he was ordered syrup of iodide of iron; and on this day it was thought that a nodule could be felt on the surface of the liver.

September 28th.—Very drowsy. Liver estimated at 4 inches below the costal margin. Abdomen larger.

October 2nd.—The abdomen measures 28½ inches, taken 2½ inches above the umbilicus. There is now some fluid in the abdomen, and slight œdema of the skin near the pubes, of the scrotum, and

DESCRIPTION OF PLATE IV.

This plate illustrates Dr. F. Taylor's Case of Cirrhosis of the Liver in a Child. (Page 119.) From drawings by himself.

FIG. 1 represents the interlobular new growth and a portion of the adjacent lobule, magnified 34 diameters. The interlobular tissue is densely nucleated, and presents numerous bile canaliculi.

FIG. 2.—New connective tissue, with a group of hepatic cells. Magnified 280 diameters.

FIG. 3.—Interlobular tissue, magnified 190 diameters. It is taken from the neighbourhood of that represented in Fig. 1, and shows the fibrillation of the tissue, the bile canaliculi, with their double row of oval nuclei, capillary blood-vessels, and nuclei.

References.—*a.* Hepatic cells. *b.* Nucleated tissue. *c.* Biliary canaliculi. Capillary blood-vessels. *e.* Section of vein.

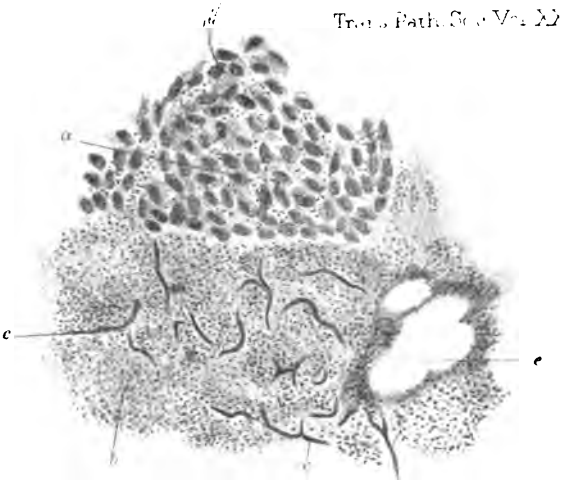

Fig. I

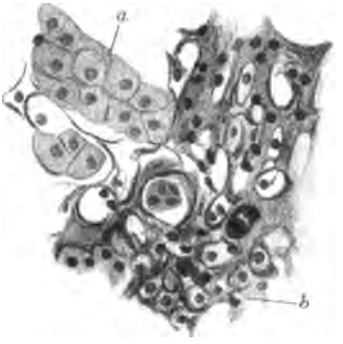

Fig. II

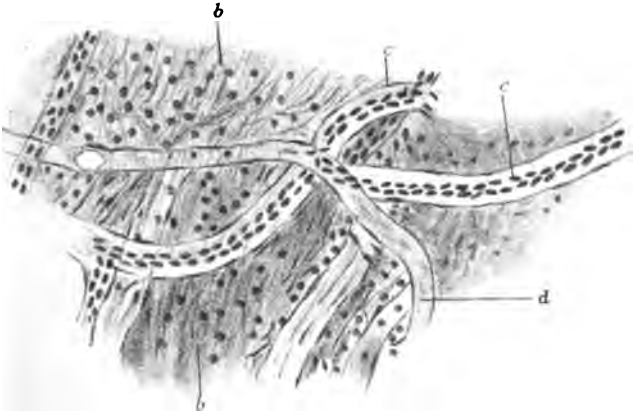

Fig. III

of the dorsum of the left foot. The liver is hard, smooth, with a sharply defined edge. Temp. 101°; pulse 130; resp. 32.

5th.—He was ordered the following:—Pot. Iodid. gr. ij, Pot. Acetat. gr. x, Syr. Aurant. ʒj, Aq. ad ℥j, t. d. s.

6th.—The liver extended four inches below the sternum in the middle line, and two and a quarter inches below the ribs in the right mammary line. Three days later the abdomen was only twenty-six and a half inches round, and a week later (13th) the liver reached only three inches down in the middle line, but the surface was distinctly nodular, and the spleen could be felt two inches below the left ribs.

15th.—There was no evidence of fluid in the abdomen, and his jaundice was clearing up. He went out much relieved on the 22nd.

From the 4th to the 12th of the month his urine varied in quantity from eight to eighteen ounces daily. The blood examined on the 17th showed no excess of white blood-corpuscles. Besides the slight eczema of the face, he had a lichenous eruption on the legs; and there were on the face small patches of ramified and dilated venules.

Shortly after leaving Guy's Hospital he was admitted into the Hospital for Sick Children, Great Ormond Street, under Dr. Cheadle's care, and I am indebted to Dr. Cheadle and Dr. Barlow for the notes of his case during the next two years.

On admission, October 31st, he is described as pale, cachectic, with a dry skin, large abdomen, and prominent veins; the edge of the liver was three fingers' breadths below the ribs in the right nipple line, and a hand's breadth in the middle line; the spleen was enlarged, hard, and extended forward to the middle line.

On November 16th the edge of the liver was half an inch higher than before; the spleen was enlarged to the same extent.

On January 3rd, 1877, the glands of the groin and neck were found to be enlarged, and there was a slight icteric tinge of the conjunctiva; the surface of the liver was not quite smooth.

On the 15th the jaundice was less; he had bled from the nose two or three times. The abdomen measured then 23½ inches round the umbilicus, and 25 inches at its greatest circumference. Towards the end of the month he had ulcerative stomatitis and sloughing tonsil. These healed under chlorate of potash and iron, and he left the hospital February 16th.

During his stay the temperature had been mostly normal; occasionally for short periods 100° or 101° in the evening. He came under notice again in October, 1877, when he had decided jaundice. The motions were pale, solid, with slight yellow tinge, and offensive; the urine was dark orange, with a slight trace of albumen and biliary reaction. The liver was relatively smaller, and markedly irregular on the surface. He was treated with iodide of potassium and perchloride of mercury, and improved.

In April, 1878, he was suffering from some cough and dyspnœa, with pain in the side. The urine was free from bile. There was no purpura, nor œdema, nor ascites. The abdomen measured 25¾ inches at the umbilicus, 28¼ at its largest circumference, and the liver reached only 1¾ inches below the ensiform cartilage. He had had diarrhœa, and passed blood and yellow matter with the motions. The skin was dark reddish brown.

In August, again, there was slight jaundice, and the abdomen diminished a little in size.

A year later, September 9th, 1879, he was again admitted, under my care, into Guy's Hospital.

It is to be regretted that the ward report has been mislaid, but the following abstract taken for the purposes of the *post-mortem* demonstration supplies the essential facts:—He was suffering from extensive ascites, and measured 35 inches round the abdomen, 2½ inches above the umbilicus. The urine had a specific gravity of 1027, was high-coloured, but contained neither blood nor albumen. The blood showed no excess of leucocytes.

On September 18th he was tapped, and 7 pints 2 ounces of greenish-yellow, opaque, ascitic fluid were withdrawn. The temperature was 103° at the time of the operation, and he afterwards became drowsy, delirious, and strange in his manner, the pupils being contracted. From this condition he partly recovered, and was sensible for a day or two, but spoke in a slow hesitating manner, with intelligence more or less dulled. He took food fairly well.

On September 25th he had a severe attack of hæmatemesis, but no melæna. The liver, which had been felt after the paracentesis, could not now be detected. The patient continued screaming at intervals and died in a state of collapse on the 26th, at 5 in the morning.

The *post-mortem* was made by Mr. G. F. Crooke, 10½ hours after death.

Expression placid, dusky complexion, capillary injection of face, well-marked icteric tinge of skin and conjunctivæ.

Body considerably emaciated; abdomen somewhat distended and large; absence of subcutaneous fat. The wound made in paracentesis is leaking; no œdema of limbs, but ascitic fluid escaping freely on opening abdomen. Hydrocele on right side, with thickened tunica vaginalis.

The brain weighed 44 oz., and was normal; the spinal cord also was normal.

Both lungs were more or less congested and œdematous, especially their lower lobes; the condition most marked in the right lung and the lower lobe of the left. The parenchyma was tough and leathery, but no special (fibroid) induration was present. There was patchy congestion of the bronchial mucous membrane; the pleural cavities contained no fluid. The mucous membrane below the epiglottis and on its under surface was swollen, pale, and uneven; the vocal cords were somewhat thickened.

The heart weighed 4 oz.; the left side was firmly contracted; it was otherwise healthy.

The capillaries and small blood-vessels of the parietal peritoneum were distended, and showed prominently.

The stomach was much distended with dark blood, partly fluid, partly clotted, which, when evacuated, left an apparently blood-stained mucous membrane; by washing with a stream of water and gently scraping, the colour was removed, leaving a pale mucous surface, on which neither erosion nor ulceration could be detected in any part. The gastric veins were here and there distended.

The small intestine contained much blood, especially at the duodenum, in the upper part of the jejunum, and lower down again about the middle of the ileum. The apparent staining behaved in the same manner as that observed in the stomach. The mucous membrane was of a pale pink, but considerably swollen.

The whole of the large intestine and rectum was much pigmented, of a greenish-slate colour, the solitary follicles showing out as dark slate-coloured spots. Peyer's patches showed nothing abnormal.

The spleen was large, weighing 23 oz., congested; suprarenal capsules healthy.

The kidneys were rather large, congested, but otherwise healthy, and weighed 8 oz.

Testes healthy.

The *liver* weighed 25 oz.; it measures now, after immersion in spirit for some time, 6½ inches from side to side, 3½ inches antero-posteriorly, and 2½ inches in thickness. It is an exceedingly good example of advanced cirrhosis, being obviously much contracted, and having the typical hobnailed appearance. The prominences on the surface are mostly from ¼ to ⅓ inch in diameter, but some, near the anterior margin, both above and below, are large nodules from ½ inch to 1 inch in diameter. The capsule is irregularly thickened, mostly filling up the depressions between the nodules, over the summit of which it is transparent; it is thicker over the left lobe.

The section of the organ has the characteristic distribution of liver-tissue and fibrous overgrowth; the yellow lobules, or groups of lobules, varying in size from $\frac{1}{6}$ to ¼ inch, are separated by thick bands of white fibrous tissue, and this becomes so abundant towards the front of the right lobe that one section shows an area of about ¾ inch square, in which no liver tissue can be detected with the naked eye. The fibrous tissue is less abundant, and forms only a thin network in the left lobe, and in the lobulus Spigelii. The portal vein is patent, and the bile-ducts and other vessels appear normal.

Microscopic sections (kindly made for me by Mr. G. F. Crooke) show that the inter-lobular new growth consists of a fibrillated connective tissue thickly crowded with small nuclei, and containing a large number of newly-formed biliary canaliculi and capillary blood-vessels. The canaliculi mostly measure about $\frac{1}{2000}$ inch in transverse diameter, and contain a double row of oval nuclei, of $\frac{1}{10000}$ inch in size. Here and there are smaller canaliculi with only a single row of nuclei. The capillary blood-vessels are generally somewhat less in diameter than the bile channels; but there are in addition many large veins in the new tissue, such as that represented in Plate IV, fig. 1. Invasion of the lobules by the connective tissue has only taken place to a comparatively slight extent.

Remarks.—The case is of interest as one of cirrhosis of the liver in a child, who was under observation for more than three years, namely, from the age of five until the age of eight, when he died. As to the influence of alcohol in its production, the evidence is not complete. From the friends, neither Dr. Barlow nor myself was able to get a confession that the child had been addicted to spirit drinking; but on one occasion in the hospital, in Great Ormond

Street, he stated that he knew the taste of brandy and gin, and liked them, and that he had often had them at night. There was no evidence during life or *post mortem* that syphilis was the cause. The nature of the change in the liver offers a second point of interest. Apart from the previous history, I think the liver would have been considered as decidedly small; but its contraction was distinctly proved by clinical observation. When he first came under treatment, the edge reached nearly four inches below the ribs, whereas two years later it only came down one and three quarter inches. In the early days he had slight jaundice without ascites, if we except a period of a few days, when he was said to have a little fluid in the abdomen, that quickly disappeared, and mild jaundice recurred from time to time during his illness. Finally, ascites appeared as the contraction of the organ became more complete. The microscopic examination shows that the lobules are scarcely invaded, but that there is a very abundant development of biliary canaliculi in the new connective tissue, without any evidence of a primary affection of the large bile-ducts.

It, is then, clearly a case of granular atrophic cirrhosis, and the new formation of minute bile-ducts will be noted with interest in connection with the cases of cirrhosis, published in the last volume of these 'Transactions,' by Dr. Saundby, whose argument the present case, I think, supports. *May* 18*th*, 1880.

---

10. *Primary carcinoma of the liver.*

By P. H. Pye-Smith, M.D.

William T—, a healthy country boy, æt. about 12, came under my care in November, 1878, with an enlargement of the liver. He said that, after a fall on his side three months before, he noticed a swelling, that it had very gradually increased, and sometimes gave him pain.[1] I found the liver smooth, firm, elastic, and the edge

[1] Dr. Hearnden of Sutton, has since informed me that he saw the boy on several occasions before he came to the hospital, for "pain in the region of the liver, accompanied with fever and coffee-coloured urine. There was then no jaundice, and very little enlargement of the liver."

easily felt some three or four inches below the ribs. There was no ascites or jaundice, and nothing in the condition of the patient or in the previous history of himself or of his parents to throw light on the nature of the case. I believed it to be a hydatid cyst, somewhat deeply seated, and had the most prominent and elastic part of the tumour punctured. About an ounce of bloody fluid escaped, which showed no sign of echinococcus and no pus. But the swelling decreased, and the boy soon afterwards went home, saying that he felt quite well.

He continued in good health for several months, the abdomen remaining large. In September, 1879, he began again to feel some pain in the right side, and again noticed a swelling there. He also vomited occasionally, but with this exception remained well until he was readmitted into Guy's Hospital in October. The liver was then little if at all larger than on his admission a year before. There was no jaundice and no ascites, the lymph-glands were not enlarged, and there was no evidence of organic disease in any other organ. The temperature was normal, and the blood, which was more than once examined, showed no increase of leucocytes. The boy was well nourished, and, with the exception of a narrow maxilla and distorted teeth, was well formed. Especially the signs of congenital syphilis were completely absent. His normal temperature and undisturbed nutrition, as well as the slow progress of the disease, seemed to exclude the supposition of a deep-seated abscess; no epistaxis, or fever, or enlargement of lymphatic organs favoured that of a cytogenic hypertrophy of the liver, like the case which I brought before the Society in 1874;[1] there was no cause of lardaceous disease, nor any evidence of its presence in other organs, and the symptoms were unlike those of hypertrophic cirrhosis. Lastly, the existence of the enlargement of the liver for more than a year without development of serious symptoms, the rarity of primary cancer of the liver, with the absence of disease in any other organ, and the age of the patient—in short, the whole clinical aspect of the case seemed to me, I confess, to be decisive against its being one of carcinoma.

My former diagnosis of hydatid was now disproved, not only by my previous experience, but by the negative result of a second tapping, which the boy had undergone (without ill effects) shortly before I saw him.

The liver slightly increased in size, and he complained occasionally

[1] 'Path. Trans.,' xxvi, p. 899.

of pain and giddiness or sickness; but was about the hospital grounds, and went home before Christmas much in the same condition as when I first saw him fifteen months before.

He was admitted a third and last time towards the end of January, 1880, under the care of Dr. Wilks, by whose courtesy I now publish the case. I found him, a few days after he came in, thinner, and the liver considerably larger, but he said that he suffered little or no pain, and was free from sickness. A few days later I noticed a tinge of jaundice, and his feet were somewhat œdematous at evening. The surface of the liver was more uneven than before, and the superficial veins were enlarged, but the physical signs were otherwise unchanged.

On the evening of February 13th he vomited and felt unwell; the temperature was then found for the first time higher than normal, 100·2° F. Next morning it was 104·6°; pulse, 144; respirations 42, with decided jaundice and slight albuminuria; no physical signs of peritonitis or pneumonia. On the 15th the temperature was 103° morning and evening: on the 16th it had risen to 105·2°, though he was fully conscious and did not complain of pain. There were still no local symptoms to account for the fever. He died during the night of the 16th.

At the inspection of the body it was found thin, with general jaundice and œdema of the legs and scrotum. The abdomen contained some straw-coloured fluid; there was no recent peritonitis. The liver weighed 200 oz. The right lobe will be seen to be greatly enlarged, and full of more or less circumscribed masses of soft yellow material, which has grown into the hepatic and (to a less extent) the portal veins, and appears here or there as characteristic malignant nodules on the surface. These new growths vary from microscopic dimensions to huge infiltrating masses. One large tumour has completely blocked the portal trunk, and compressed the common bile-duct. Hæmorrhage has occurred in a few, and all are in more or less advanced fatty degeneration. Indeed, one of the most remarkable points in the anatomy of the disease is that no parent growth appears; all seem to be coæval, even the smaller and less numerous tumours in the left lobe. The glands in the portal fissure were not enlarged, and there was no primary growth in the pancreas, duodenum, or bile-ducts. The gall-bladder was full of pale mucus, its coats were thickened, and its mucous membrane injected.

The spleen was large (13 oz.), firm, and pale, the Malpighian follicles showing plainly. The stomach and intestines, the kidneys and other abdominal viscera and the testes were normal, and the lymph-glands were not enlarged. The brain weighed 51 oz. The lungs were pushed up by the enormous liver, but were not collapsed; they were crepitant throughout, and only slightly œdematous. Careful search in the rectum, the cardiac end of the œsophagus, the vertebræ, and other parts, failed to discover a primary tumour, and the only other trace of the disease was in the base of the right lung, where was a small, firm nodule, looking like a shrunken infarctus.

Microscopical examination of fresh sections, made by freezing, showed infiltration of the liver-cells with oil-drops, fibrous capsules surrounding some of the cancerous nodules, and absence of ordinary alveolar carcinoma and of sarcoma. After hardening and staining, the section showed that the fibrous capsules consisted of hepatic cells and vessels, pushed aside and compressed. The nodules consisted of closely-packed, polyhedral, epithelium-like, nucleated cells, with scarcely a trace of stroma between them; they chiefly differed from the surrounding liver-cells in the absence of the characteristic columnar arrangement. Several masses were seen growing into hepatic veins. There were also some places which showed small round cells, with nuclei and scanty protoplasm, scattered among the cells of the acini or forming minute aggregations.

The tumour in the lung gave still more characteristic and satisfactory signs of the nature of the disease. Beside several spots of hæmorrhage into air-vesicles, and some interstitial pneumonia, there were numerous microscopic nodules, scattered through this pulmonary tissue. Each of these consisted of a fibrous capsule enclosing closely-packed epithelial cells, like those of the hepatic tumours in size and aspect, but less degenerated, and, therefore, more distinct.

The disease obviously belongs to the group of malignant growths, but it is not medullary sarcoma nor alveolar carcinoma, in the strict sense of the term, nor epithelial cancer, nor the form of tumour which has been described as cylindrical-celled epithelioma, columnar glandular cancer, and tubular adenoma.

It is an epithelial overgrowth, which is manifestly formed on the model of the tissue in which it occurs, repeating the hepatic structure, but without its normal glandular arrangement, just as scirrhus

of the breast repeats the structure of that organ.[1] The solitary secondary growth in the lung, by its exact resemblance to those in the liver, showed its direct descent from living corpuscles, which must have been detached from one of the parent tumours in the hepatic veins, and conveyed directly to the pulmonary capillaries as an embolus.

The invading course of the disease in the liver and the heterologous character of the nodules in the lung sufficiently attest its malignant nature, and the epithelium-like cells, without intercellular stroma, bring it into the group of carcinomata.

If we define "adenoma" as a tumour reproducing the type of a secreting gland we may divide it histologically into the lobular or racemose adenoma (or adenocele) of the breast, the tubular adenoma of the rectum, and the growths of columnar or cylindrical duct-like epithelium, which are not uncommon as growths from the hepatic or the pancreatic duct. Lastly, and distinct from these, will come the small group, to which the present specimen belongs, of glandular growths in the liver, which do not conform to the columnar or cylindrical epithelium of its bile-ducts, but to the polyhedral epithelium of its lobules.

Pathologically, we must recognise the most important distinction between local, single, homologous, benign adenoma and diffused, multiple, heterologous, malignant adenoma. Dr. Mahomed described and figured a case of the latter in an excellent paper in our volume of 'Proceedings' for 1876, together with another of the more common cylindrical-celled tumour.

Dr. Whipham's case, in the twenty-second volume our 'Transactions' (p. 164), was, no doubt, as he argues, one of primary cylindrical- (or columnar-) celled epithelioma. So was Dr. Greenfield's case, in our twenty-fifth volume (p. 366); but here, as in my own case, there was a secondary nodule in the lung, of the same structure as the malignant growth in the liver.

Beside the first case in Dr. Mahomed's paper, just referred to, and a doubtful one in the thirty-third volume of 'Virchow's Archiv' (1855), published by Friedreich, several cases agreeing histologically with the present one have been recorded by Vulpian and Lancereaux. The characters of this form of adenoma hepatis are figured by Rindfleisch (fig. 135) in his chapter on "Cancroide or Adenoma

[1] I may refer on this subject to the sixth chapter of Dr. Creighton's 'Physiology and Pathology of the Breast.'

Hepatis," though he does not distinguish it from the more common "tubular" or "columnar-celled" form of Cornil and Ranvier, which he figures in figs. 136, 137. Other cases of adenoma hepatis have been published by Griesinger ('Archiv d. Heilk.,' v. 385), Eberth ('Virchow's Archiv,' xliii, 1), Willigk (ibid., li, 208); but these were either cylindrical-celled in structure or innocent in progress.

Histologically, then, the present case is one of a rare form of new growth, multiple infecting glandular cancer, or malignant adenoma, of the liver.

The pathological interest of the case lies in its remarkably slow and latent course, in the pyrexia, which was observed during the short period of active symptoms before death, in the age of the patient, and in the light which such malignant though homologous growths throw upon the natural history of cancers generally.

March 2nd, 1880.

---

11. *Primary diffuse malignant growth in the liver, in which the characters of sarcoma and carcinoma were apparently combined; rapid evolution of the disease, which was of great extent, but limited to the liver.*[1]

By Sidney Coupland, M.D.

This specimen of a greatly enlarged liver, the major part of which appears to be infiltrated with new growth, was obtained from the body of a woman, thirty-three years of age, who died in the Middlesex Hospital on October 3rd, 1879. The interest of the case lies clinically in the apparently rapid development of the disease, with but few symptoms beyond pain and enlargement of the organ, and pathologically in the fact that to all appearance the growth

[1] This specimen was exhibited under the title "Primary Sarcoma (?) of Liver." Unwilling that upon so important a question there should be any risk of error in the record, I have ventured to substitute for that the above heading, especially as the Morbid Growths Committee did not consider the growth to be sarcomatous.

was primary in the liver, and limited to that organ, no other growths being found in any other part of the body. It is also of great interest from the histological characters it presents, and the questions it raises as to the development of tumours in the liver.

I am indebted to Dr. Greenhow for permission to bring the case forward.

Mary D—, æt. 33, a married woman with one child, æt. 9, three others having died in infancy, was admitted into the Middlesex Hospital on September 16th, 1879, under the care of Dr. Greenhow, suffering from pain over the right lower ribs, increased on taking a deep breath. She was a fairly nourished, not anæmic woman, and had no cough. She was menstruating, and the abdomen was not examined until she had been in the hospital a few days, but percussion revealed dulness over the right front of the chest from the fourth rib downwards, and posteriorly for about three fingers' breadths at the base of the lung. The respiratory murmur was weak over the dull area, and vocal fremitus was absent; but the vocal resonance was unaltered. The heart's apex impinged in the fifth interspace, 1½ inch within the vertical nipple line; the first sound was muffled and murmurish. Pulse 96; temp. 101·4°. Tongue thinly coated, but moist. She did not exhibit much sign of suffering, and the case was at first regarded as one of slight pleural effusion. Her history was as follows:

She had always enjoyed good health, but had occasional cough in the winter, and after her second confinement, some seven years ago, had "milk fever," and was "blind for a week." Had scarlet fever about ten years ago, but never rheumatic fever, nor hæmoptysis.

Five weeks before admission she says that she "caught cold in the right shoulder" whilst travelling in a railway carriage, and in the evening of the same day she felt pain in the shoulder and down the right side of the back. The pain increased; it extended to the hypochondrium and flank; was not relieved by local applications, and has continued ever since.

She is the second child of a family of six. Her father, sixty-four years of age, is living, but for the past six years has been laid up with general dropsy. Her mother, sixty-five years of age, is also alive. One brother died of rheumatic fever, twenty-nine years of age.

The progress of the case for the first few days after admission was not such as to indicate that she was suffering from any grave disease. The temperature only once or twice reached 100°; generally it was normal, but she continued to suffer from pain in the side, and from flatulent distension. It was not until the 25th that she was in a condition to allow of the abdomen being examined. It was noted to be large, and marbled with large veins. The hepatic dulness reached from the fourth rib above to the iliac crest, and leftwards to the axilla, the lower limit in the left nipple line being midway between the costal arch and umbilical level. The surface of the organ was smooth, its lower margin rounded and well-defined. It was not tender. Posteriorly there was dulness over the lower third of right back, where enlarged cutaneous veins were visible. The patient believed the abdomen was increasing in size, causing her more discomfort. From this date her course was a downward one.

On the 28th.—Temp. 99°; pulse 128; resp. 32. It is noted: "Has had a restless night, and has been very restless this morning. There is great pain in the abdomen. Tongue dry and brown. She sweats profusely. Breathing entirely thoracic. The left border of the swelling was found to be irregular, and aspiration by Mr. Hulke on this day, made in the softest part of the tumour, yielded a drop of blood mingled with large multinucleated cells.

Some cutaneous extravasation occurred at site of puncture and spread in the abdominal wall. The left lower limb became œdematous. Slight icterus developed on the 1st October. There was never any albuminuria. The tongue remained dry and brown. The temperature varied from 99·2° to 97·4°, and pulse from 108 to 128, and after a restless night she died at 2 p.m. on October 3rd.

The *post-mortem* examination was made on October 4th. Body well nourished, slightly jaundiced, the skin in right flank being discoloured a greenish black. Brain and its membranes natural. Eyes not examined.

Abdomen.—On opening the cavity a small quantity of dark, straw-coloured fluid escaped. The liver was seen to be of great size, displacing the intestines downwards, its lower margin reaching to the crest of the ilium. Above it had displaced the diaphragm and lung, so that on the right side its margin was opposite to the third rib. The notch between the lobes was seated about midway between the ensiform cartilage and the umbilicus, whilst the left

lobe, proportionately enlarged, extended to the spleen, its outer margin being bent forwards where it came in contact with this organ. Some vascular cellular adhesions, readily broken through, occurred between the surface of the right lobe, and the abdominal parietes and diaphragm.

The liver was then removed. It was, indeed, enormously but uniformly enlarged, weighing 18 lbs. 12 oz. (300 oz.). It had the following dimensions:

Right lobe—	Antero-posterior . . .	16 inches.
	Transverse . . .	9 „
	Vertical (thickness) . .	6 „
Left lobe —	Antero-posterior . . .	11 „
	Transverse . . .	6½ „
	Vertical	4 „

The capsule was very vascular, being marked in all directions, especially on the outer and upper surfaces of the right lobe, with injected vessels; it was smooth, not thickened. The upper surface of the right lobe had a yellowish-pink ground, variegated and mottled by oval and rounded patches of a sepia and black tint, these patches varying in size from a sixpenny-piece downwards. Towards the anterior margin the surface became more thickly studded with spots of black pigmentation, varied by whitish areas, the yellow colour of the hepatic tissue being here wholly wanting. On the inferior surface the lobe was irregular and uneven, and for fully its anterior one half was of a greyish-black colour. The left lobe had a similarly variegated appearance, only here there was more of the natural orange-yellow tint of liver substance than on the right lobe. However, here again the portion most anterior was somewhat thickly studded with black and grey spots.

On section the right lobe, especially its anterior two thirds, had a firm but resilient consistence, much like that of india rubber. Its anterior one-fourth was wholly replaced by new tissue, the cut surface of which had a strikingly marbled and variegated aspect, greyish and black areas being interspersed with pale and whitish lines. The cut surface was uneven (its elasticity allowing it to swell up after section), lobulated, and permeated by vessels, so that it simulated general enlargement and alteration of the natural acinous structure. This passed almost insensibly into a similar mass, which occupied the main thickness of the lobe, reaching to the the inferior surface, but marked off by a thin line from the nearly

normal liver-tissue in front of it, the latter forming a layer of about three inches thick. It was roughly estimated that fully two thirds or more of the lobe had undergone this change. The hepatic tissue remaining was paler and more friable than natural, and was, moreover, largely variegated (in the anterior as well as on the surface) by greyish and black nodules and striæ. The left lobe on section proved to be less markedly invaded by the new growth, occurring here more in the form of greyish-white and black nodules, more or less closely aggregated, than as a continuous mass, similar to that replacing the greater part of the right lobe. The liver-tissue here was also friable and fatty.

The gall-bladder was partially filled with yellow bile.

The lymphatic glands in the hilus of the liver were not obviously enlarged.

The stomach and intestines were natural. No growths nor ulceration in connection with them in any part.

The pancreas was also free from new growth. Spleen was pale and soft.

Kidneys smooth; cortices swollen and pale; no cancer nodules.

Ovaries shrivelled. Uterus rather bulky; walls tough.

There were some subserous ecchymoses beneath visceral pericardium in auriculo-ventricular groove. A fleshy semi-decolorised clot filled the right ventricle. Heart-wall firm; valves healthy.

The lower lobe of the right lung was greatly compressed at its lower parts, which were quite airless; the upper lobe engorged, exuding a frothy blood-stained fluid on section. Beyond slight marginal collapse of its inferior border, and general engorgement, the left lung was natural.

Microscopical examination of the diseased liver, so far as I have been enabled to carry it, has made it very difficult for me to determine the precise nature of the infiltrating growth. It presented to my view two distinct types of structure—carcinomatous and sarcomatous; the former consisting of small alveoli full of epitheloid cells, manifestly developed from the glandular epithelium; the latter composed of definite whorls of spindle-shaped cells, which were wholly different in arrangement from those in the "carcinomatous" portions. Some of these spindle cells were pigmented, and in addition free pigment granules lay scattered between the cells. No direct transition could be traced between the hepatic cells and the spindle cells, such as was obviously seen in the carcinomatous

areas. I cannot help concluding that the case is an instance of "acute cancer," in the general sense of the term, in which the morbid process has affected both the stromal or connective, and the epithelial elements of the gland.

Apart from this singularity in structure, it is remarkable in the limitation of the growth within the limits of the capsule of the liver; no lymphatic glands in the vicinity were affected; no distal growths occurred in any part of the body. When to this are added the extremely rapid evolution of the new growth, and its remarkable diffusely infiltrating character within the organ, we have other features not usually met with even in hepatic cancer. Most remarkable of all—and on this head I should wish that the specimen be referred to the Morbid Growths Committee to confute or confirm the statement—would be the fact of a sarcoma being primary in the liver. The occurrence of pigment within and without cells suggested melanosis, but of this there was absolutely no evidence in any part of the body, although it is only right to say that the eyes were not examined after death. On the other hand, in not one of the cases of primary malignant disease of the liver brought before this Society, or the Société Anatomique at Paris, or occurring at the Middlesex Hospital, during the past six years, has the growth partaken of sarcomatous characters. Frerichs, however, records one case of a disease the existence of which there is no more reason for doubting than there is of sarcoma of the breast. *November* 18*th*, 1879.

Report of the Morbid Growths Committee on Dr. Coupland's specimen of Primary Sarcoma of the Liver.

Two features are discernible in sections of this liver; first, increase and alteration of its epithelium; second, increase and modification of its connective tissue. These conditions are so intimately blended in most parts that it is impossible to be certain how much of the disease is due to each. But a careful study of those portions of the tumour which lie in contact with normal or almost normal liver structure, comprises the observation made by Dr. Coupland on the multiplication of the liver-cells, and further teaches that multiplication by endogenous formation is taking place. In parts more remote from the normal structures a perfect alveolar formation exists, the alveoli of which are filled with cells apparently derived from the liver-epithelium. The alveolar forma-

tion is not everywhere equally perfect, but is often replaced by a more confused structure, in which it is difficult to appreciate any order or method of arrangement. From the proliferation of the epithelium, the traces of endogenous multiplication, and the alveolar structure, we think there can be no doubt that a portion, probably a large portion, of the disease is carcinoma.

On the other hand, even in portions of the liver in which the acini are tolerably perfect, the connective tissue between them is increased in quantity. And, where the cancerous changes are developed, there is often a considerable increase of connective-tissue elements, sometimes with the formation of fibrous tissue, sometimes with the production of spindle-cells, which occasionally are so abundant that the whorls of spindle-cells described by Dr. Coupland are apparent. Of these connective-tissue changes two explanations are possible: one, that the affection is sarcomatous, and that therefore two tumour diseases, both of primary origin, coexist in the same organ; the other, that the affection of the connective tissue resembles in its nature that which occurs in cirrhosis of the liver. To the latter explanation we incline, partly because we know of no similar instance of such contemporaneous development of sarcoma and carcinoma, but chiefly because the formation of even a considerable quantity of connective tissue is not uncommonly associated with the development of carcinoma.

JAMES F. GOODHART.
HENRY T. BUTLIN.

---

12. *Primary cancer (epithelioma) of the gall-bladder.*

By SIDNEY COUPLAND, M.D.

THE patient from whom this rare specimen was obtained was a married woman, 56 years of age, admitted into the Middlesex Hospital, under Dr. Cayley's care, on August 19th, 1879. She had suffered for six months from anorexia, occasional vomiting, and epigastric pain. For two months she had observed a swelling in the right side of the abdomen just below the ribs, and had gradually become very weak.

She was anæmic but not jaundiced, and was much emaciated. She complained of sharp pain in the right hypochondriac region,

where a rounded but firm tumour existed, apparently connected with the liver. There was exquisite tenderness over the swelling. The liver dulness measured 6½ inches vertically.

Pain was a very prominent symptom, requiring frequent injections of morphia; and on Sept. 5th peritoneal friction could be detected over the swelling. The tumour increased somewhat in size, and altered in form, but remained throughout very firm. The patient occasionally vomited, but was *never jaundiced.* During the last week or so vomiting became persistent, delirium set in, and she died from exhaustion on November 21st.

The following are the notes of the *post-mortem* examination:

Body extremely emaciated; in no degree jaundiced. On opening the abdomen a firm tumour presented in the right hypochondrium, projecting below and almost overlapping the margin of the ribs. A few bands of adhesion passed between it and the parietal peritoneum near the middle line, where, over an area the size of a crown-piece, the peritoneum was infiltrated with firm cancerous growth, which involved the subperitoneal tissues, and to a slight extent invaded the rectus muscle. Around the margin of the mass on the peritoneum were scattered several small firm whitish nodules.

The liver, with which the tumour was connected, was also firmly adherent to the duodenum, and, in removing the organs, it was cut away from its attachment to the gut. In doing this a cavity was laid open, from which some small calculi escaped. There was no trace of a gall-bladder, but in its site, and occupying almost the lower fourth of the right hepatic lobe, was a large ovoidal mass the size of a cocoa-nut. The growth measured 4¾ inches antero-posteriorly. It had a yellowish-white appearance, and was very firm. On section, its central portion had a more opaque appearance and was more creamy in consistency than the periphery, which was sharply marginated above and externally from the liver substance. About an inch and a half from the upper surface of the growth, and two and a half from its anterior margin, there was a smooth lined cyst, the size of a walnut, full of mucoid fluid entangling numerous orange-coloured calculi, averaging a split pea in size. This evidently represented the cavity of the gall-bladder, the entire walls of which had been replaced by the tumour mass. A deep groove separated the upper border of the tumour from the hepatic tissue, corresponding to the line of the ribs, but on the right side no very sharp line of demarcation existed between the growth and

the liver substance, the margin of the growth being irregularly crenated. There were no outlying nodules in the liver separated from the main mass of the tumour. The capsule of the rest of the right lobe and of the left lobe was natural; and the liver-tissue itself had a normal appearance.

The stomach was much dilated. Its lining membrane was manifestly thickened and coated with a layer of tenacious mucus. Immediately beyond the pylorus the duodenum was much contracted, and its walls thickened; a small triangular-shaped ulcer occurred in the mucous membrane, the wall of the duodenum at this point being infiltrated with the same material as the tumour, with which, indeed, it was continuous.

The spleen was slightly indurated; the kidneys pale and granular.

Lungs, adherent at apices, were highly emphysematous, and contained no nodules of new growth.

The heart was pale and flabby; mitral valve rather opaque, and aorta slightly atheromatous.

The nature of the growth was peculiar, its microscopical characters resembling those of the squamous variety of epithelioma rather than of the columnar type.

It seems evident that this was a case of primary epithelial cancer of the gall-bladder, which had attained remarkable proportions, but yet had remained perfectly localised, only contiguous parts (*e.g.* peritoneum and duodenum) being affected. The occurrence of gall-stones in the cavity of the gall-bladder is of interest, and suggestive from an etiological point of view, whilst the absence of jaundice was perhaps the next remarkable feature of the case, showing that the disease had not implicated the common bile-duct. *December 2nd*, 1879.

---

18. *Case of cancer (probably primary) of the gall-bladder.*

By Norman Moore, M.D.

The specimen shows a portion of the pyloric orifice of the stomach, with the beginning of the duodenum, and adherent to them the gall-bladder.

The gall-bladder is infiltrated in every part and surrounded by

a mass of medullary cancer. It contains four large facetted gall-stones, and there were several smaller stones.

The growth in and around the gall-bladder was continuous with a mass of infiltrated lumbar glands. The duodenum was compressed and its walls infiltrated by the cancer. The cystic duct was obliterated, the common bile-duct open.

The stomach was so dilated as to cover all the abdominal viscera to within an inch of the pubic symphysis. The peritoneum and pleura contained a few small nodules, and there were one or two near the gall-bladder on the liver, but none within the liver, and the pancreas was not at all infiltrated. The pylorus was unaffected.

The patient was a woman, æt. 59, and was under Dr. Andrew's care in St. Bartholomew's Hospital. She had noticed an increasing abdominal swelling for five years, but it had only given her trouble for one month before admission, *i. e.* two months before her death. A hard tumour near the liver was felt during life, but Dr. Andrew informed me that three weeks before her death there was no evidence of the great dilatation of the stomach found after death.

The gall-stones may be regarded as the localising cause of the new growth.

Primary cancer of the gall-bladder is somewhat rare, and this is, I think, a distinct case. The rapid dilatation of the stomach is an interesting clinical feature. *December 2nd*, 1879.

---

14. *Description of a large gall-stone passed per anum; with remarks on the structure and mode of formation of biliary calculi.*

By William M. Ord, M.D.

In a short letter printed in the 'British Medical Journal' of July 19th, 1879, my friend, H. Carr H. Roberts, gives the following account of the circumstances under which the gall-stone now exhibited was passed.

"About the middle of June last I was called in a great hurry to see Mrs B—, a lady living close by. I found she had been con-

fined a fortnight before, and for a week previously had been obliged to keep her bed on account of excessive pain in her back (attributed to the impending labour), and constant diarrhœa of a pale-yellow colour. For several days she "had felt something in the back passage," and at last succeeded in hooking out with her fingers from the anus a huge stone, measuring 5 inches in its greatest circumference, 4 inches in its least, and weighing 5 drachms. The patient has had a large family, and, with the exception of shortness of breath (due probably to a fatty heart), has enjoyed good health. The urine is normal. She is not, and never has been, jaundiced, and at the time of writing is well and about her household duties."

Mr. Roberts placed the stone in my hands for examination.

It size is certainly remarkable. It measures 1⅝ inches in its long diameter, and 1⅛ inch in its transverse diameter. It is of a brown colour, and near one pole, having sustained some superficial damage, has been broken away in laminated fragments. It is composed of a mixture of cholesterin with biliary pigment. Now, this is the composition of the majority of biliary calculi. Some one has written anonymously in the 'British Medical Journal' to suggest that the stone is an enterolith. Enteroliths, however, do not show such a composition, but are made up either of matted hair or of matted undigested substances, such as husks and beards of seeds, or of the triple phosphate, or of lime salts, or, in the bezoars, of ellagic or lithofellinic acid.

The examination of the calculus in question leads me to make some remarks on the general structure of cholesterin biliary calculi. Such calculi consists chiefly of a mixture of cholesterin with biliary pigment. There may be present in addition small quantities of mucus, of lime salts, of the biliary acids, of carbonate of lime. In split sections cholesterin calculi present a very general uniformity of structural arrangement, which has been accurately described by many observers. Four principal layers are described :—Most internally is found a dark-coloured nucleus, fading into an investing layer of a pale colour; the second investing layer is manifestly composed of crystalline material arranged in radiating plates or columns; and, thirdly, outside are several concentric layers of varying colour and thickness, in which a low magnifying power reveals a radiating crystalline structure. These are invested, lastly, by the outer crust, usually more deeply coloured, and showing no traces of radiating, and little of concentric structure.

The microscope reveals marked differences in the several layers. (1) The outer layer consists of an intimate mixture of cholesterin with colouring matter. The cholesterin is not in rhombic plates, but either distributed in molecular form, or in spheres, or towards the deeper part of the layer in deeply-stained undulating crystalline fibres. (2) In the concentric laminæ the undulating fibres are still found with more marked crystallinity and distinct radiating arrangement. In successive deeper laminæ the fibres become more distinct, more crystalline, less coloured, the colour gathering into interstices instead of staining the crystal; and so by many gradations the lamina are exchanged for a tract (3) of radiating columnar masses of perfectly colourless cholesterin, with masses of pigment packed into their intervals. Lastly, the centre (4) is composed in great part of deeply-tinted subcrystalline pigment, with a small admixture of cholesterin, in rhombic and rhombohedral forms but not with radial direction. The pigment does not represent an original nucleus, but occupies rather loosely a cavity in the centre of the calculus, and is distinctly continuous with the pigment lying between the radiating crystalline columns, the cavity being, in fact, the meeting point of the spaces between the columns.

On consideration of the section and of the calculus, as a whole, it is evident that the outer layer (1) represents the latest additions to the concretion, and that this contains a mixture of formless crystalline matter with formless pigment and a few spherules. The central portion (3 and 4), also evidently the oldest, consists of separate masses of crystals and of pigment. An examination of calculi, of all sizes, from small to large, shows that this central part has been originally deposited, as might be supposed, in the condition seen in the outer layer, so that the state of layers 3 and 4 in larger calculi indicates the occurrence of a metamorphic change, consisting, in the slow but complete separation from each other of the cholesterin and pigment, at first indistinguishably commingled.

When first precipitated the cholesterin is disseminated through a bed of biliary pigment, a colloid of high molecule. This not only prevents the formation of separate crystals, but tends to group the crystalline matter into spherules. If the colloid always remained a colloid no further change would occur, save a minute radiating crystalline fibration, such as is found in uric-acid calculi. But the colloidal pigment tends, in process of time, to become crystalline, and

as step by step it assumes that condition, the two substances are segregated into two zones—a central one of the more adhesive pigment, an outer one of the polar crystal.

The change is slower in proportion as the pigment is in excess, as the series of specimens now exhibited clearly shows, the deepest coloured calculi having a predominance of dark concentric laminæ, the most lightly tinted being almost entirely radiantly crystalline.

I have recently described, in the 'Proceedings of the Royal Society,' the behaviour of cholesterin when deposited in the presence of colloids, and have shown that it passes through a spheroidal state to a state of radiating fibration, or to a still closer reversion to its normal rhombic form. An experiment showing the separation of cholesterin from bile-pigment, after deposition in combination therewith—an experiment not noted in the paper referred to—may be cited in illustration of the propositions advanced. A gall-stone containing a great deal of pigment is reduced to fine powder. Some of this is mixed on a glass slip with glycerine and glacial acetic acid and the mixture is covered with thin glass. The slip is then slowly heated over a spirit flame to ebullition. When the powder is in great part dissolved; the slip is transferred to the microscope. The fluid is found in a state of great agitation, and filled with very small yellowish spherules, which run together to form large spherules of all sizes. These move about the field under the influence of the currents, with all sorts of amœba-like changes of outline, but they are perfectly homogeneous, and do not affect polarised light. Presently they become stationary, lose their transparency, and begin to crystallise, the process beginning at one point and extending thence quickly over the whole mass. The crystallisation converts them into lozenge-like bodies, covered with somewhat round or angular projections, finely marked with bent parallel lines, indicating imprisoned acicular crystals. Very often the interior remains uncrystallised, but in a state of evident tension for some time. The crystals are perfectly colourless, the pigment being separated from them in subcrystalline nodules of a brilliant yellowish red, like that of hæmatoidin. After a varying time, sometimes many hours, the imprisoned raphides burst from their envelope, and the whole mass bristles with them, star-fashion. At the same time the tense interior arranges itself in concentric laminæ of parallel, radiating, crystalline fibres, still completely separate from the pigment, which forms alternate layers; so that we have before our eyes, within a few hours, the

spectacle of the formation of a tiny biliary calculus. The process, watched under polarised light, is wonderfully beautiful. The first-formed spheres, as has been said, do not affect polarised light, and are almost invisible with the dark field. When crystallisation begins brilliant light flashes out in the margin of the sphere, like a bright sunrise, and then extends over the whole mass with gorgeous play of colour, due to the varying thicknesses and tensions.

Jan. 6th, 1880.

---

15. *Œsophagus and stomach from a case of acute carbolic acid poisoning.* (*Card specimen.*)

Exhibited by ROBERT SMITH, M.D.

THE patient, a woman, æt. 45, was brought to Charing Cross Hospital, at 2 a.m., on July 13th, 1879, her friends stating that about half an hour previously she had swallowed about three-quarters of a pint of the ordinary commercial undiluted carbolic acid, and that she had exhibited no signs of delirium or of excessive pain afterwards, but had at once become insensible. At the time of taking the acid she had not quite recovered from the effects of a prolonged drinking bout. She was quite insensible when brought to the hospital; breathing was stertorous; the pupils were somewhat contracted, and did not respond to light; the pulse was small and irregular, and the skin cold. The stomach-pump was at once used, and about half a pint of dark grumous fluid, smelling strongly of carbolic acid, was removed before the patient's death, which took place about a quarter of an hour after she was brought to the hospital, or three quarters of an hour after the poison had been taken.

At the *post-mortem* examination, thirty-seven hours after death, I found the following condition of the specimens exhibited:—The root of the tongue and the adjoining surface of the epiglottis presented a glazed appearance, of a leaden hue. The whole of the inner surface of the œsophagus had that glazed leaden appearance very marked, as if it had been coated with a thin pellicle of sheet-lead. To the finger this glazed surface felt somewhat sticky and viscid, and thin patches could be easily removed from the affected surface. The stomach was found contracted into small bulk. It contained no fluid, but about a teacupful of undigested pieces of beef. The interior of the organ was much corrugated throughout, except over a small area near the pyloric orifice; the mucous membrane everywhere, except in the part mentioned, was roughened and easily broken off in small pieces. This rough condition of the stomach contrasted markedly with the smooth, glazed appearance

of the œsophagus, the boundary between the two conditions being quite abrupt at the lower end of the œsophagus. Perhaps the different character of the epithelial lining of the two organs, in addition to the difference of the length of time during which they were exposed to the action of the carbolic acid, may in part account for this marked difference in the appearance of the two mucous surfaces. The stomach and œsophagus smelt strongly of carbolic acid.

The condition of the other viscera and of the blood is not alluded to, as they are not exhibited. Some account of them appeared in the 'Medical Times and Gazette,' vol. ii, 1879, pp. 236-7.

January 20th, 1880.

16. *Acute fatty changes occurring in an enlarged liver (acute hepatitis?).* (*Card specimen.*)

Exhibited by C. H. Ralfe, M.D.

Five months ago patient was seized with severe pain in right side; rigors, sweats. Was in hospital in Ceylon for six weeks; constant pyrexia, lost considerably in weight, he stated five stone. After one week the pyrexia abated, and he was free from pain, and began to recover flesh. Sailed for England. Just before arriving was seized with old pain and return of fever; admitted into Seaman's Hospital, May 1st. Liver dulness up to right nipple, and bulging below margin of ribs three fingers breadth. Temperature ranging from 99° to 100° F. Rigors and sweating, &c.

Diagnosis.—Hepatic abcess. Aspiration; no pus. One day *before* aspiration temperature sank and the patient seemed low; after aspiration temperature remained subnormal; he became rapidly comatose and slightly jaundiced; death three days after aspiration. Leucin and tyrosin in urine. *May 18th*, 1880.

17. *Volvulus of small intestine due to a complete Meckel's diverticulum.* (*Card specimen.*)

Exhibited by S. Coupland, M.D.

The specimen consists of about five feet of ileum and the cæcum. From the free surface of ileum, three feet above ileo-cæcal valve, arises a diverticulum, which passes directly to the umbilicus. It is seven inches in length, and for the uppermost two inches (to which the great omentum was adherent), forms an impervious cord. At its point of origin the ileum was twisted on itself, causing complete obstruction; the coils beyond lying flaccid and empty in the pelvic cavity, whilst all the intestine *above* the diverticulum was distended with fluid fæcal matter, especially the portion here retained. This

part of the gut was intensely congested and in places showed commencing gangrene. There was no general peritonitis, and the other viscera were healthy.

Taken from the body of a young man, 29 years of age, who died in the Middlesex Hospital on March 27th, about twenty-four hours after admission. He was a painter, but had never had any intestinal trouble before the fatal attack, which commenced on March 25th with vomiting, severe *dragging pain at umbilicus*, and slight diarrhœa. The vomiting and pain persisted, but no motions passed after the morning of the 26th. There was distension of belly, dulness in flanks, and fluctuation due (as shown at *post-mortem*) to the liquid contents of the bowels. Death was sudden.

November 4th, 1879.

18. *Carcinoma (medullary) of duodenum, just beyond pylorus, occluding and invading hepatic ducts.* (*Card specimen.*)

Exhibited by S. COUPLAND, M.D.

THE specimen shows the liver, pancreas, stomach, and duodenum from an old man, æt. 80, a bootmaker, under Dr. Greenhow's care, at the Middlesex Hospital, from September 25th, 1879, to October 16th, 1879. His previous health was good. Nine months before admission he suffered from pain and tenderness in right hypochondrium, and three months later jaundice was first noticed. The icterus deepened; there was loss of appetite, constipation and increasing feebleness till his death; no vomiting.

The liver is enlarged and of an olive-green colour, its bile-ducts distended with clear fluid; gall-bladder fully distended with clear fluid; duodenum (first part) adherent to liver at the hilus, where a soft cancerous mass, apparently growing from the bowel, concealed the ducts. In the bowel the growth formed an oval ulcer with soft white margins and sloughing base. A bristle is passed through the pancreatic duct into the duodenum, and the common bile-duct has been laid open as far as possible, it being occluded by a polypoid outgrowth of the cancer. Microscopically it has characters of medullary cancer.

There were no secondary nodules.

The disease resembles somewhat, in its position and in its effects, a case of epithelioma of duodenum exhibited in 1873 ('Path. Trans.,' xxiv, p. 103). The subject in that case was also an old man (æt. 72).

November 4th, 1879.

19. *Hernia of ileum through a rent in the great omentum.* (*Card specimen.*)

Exhibited by S. COUPLAND, M.D.

THE great omentum and a large portion of ileum from a man, æt. 47, under Dr. Cayley's care, at the Middlesex Hospital, from February 15th to 19th, 1877, with symptoms and history of acute intestinal obstruction, setting in two days before admission. Enterotomy was performed on the 18th, but vomiting recurred, and patient sank.

[The case is fully reported in 'Med. Times and Gaz.,' 1877, ii, p. 462.]

Forty inches of ileum are included by the constricting band, which is seen at the right lower angle of the greatly fat-laden omentum, the site of the distal strangulation being four inches from the ileo-cæcal valve.

The artificial anus is seen in the ileum two feet above the constriction.

There was commencing peritonitis.

Note.—A similar case is figured in 'Pitha u. Billroth,' Bd. iii, 2nd Heft, 4th Lief., p. 15. *November 4th*, 1879.

20. *Hernia of some of the abdominal viscera into the left pleura, probably congenital.* (*Card specimen.*)

Exhibited by WM. EWART, M.B.

THE patient was a valet, æt. 34, of healthy aspect, who died from right pleuro-pneumonia soon after his admission into St. George's Hospital, and before any history could be obtained.

The left pleura was found to contain a portion of the abdominal viscera. The normal "cardiac space" was occupied by the transverse colon, carrying with it the omentum; behind these and to the left was the stomach. The stomach and the colon were both much inflated, and filled the greater part of the pleura. The pancreas, the upper part of the spleen, and a small supernumerary hepatic lobule, situated at the extreme left of the left lobe of the liver, had also found room in the thorax. The heart was pushed upwards, backwards, and to the right, and the left lung was compressed to a small volume in the upper part of the chest, where the apex had become adherent; it could be inflated without difficulty.

The herniated viscera possessed no peritoneal or pleural sac, and came into direct contact with the lung, constituting the less unusual form of phrenic hernia, or "false phrenic hernia" of Peacock.

The orifice was situated at the left tendinous centre; it was large,

oval, with thick, smooth edges. The œsophagus was normal, but its cardiac end had been drawn up into the orifice. It will thus be seen that, in the course of digestion, the food passed five times through the diaphragm.

The hernia was probably congenital; as supporting this view may be mentioned the fact that another malformation existed; the right kidney was absent.

The right pleuro-pneumonia was not severe; its rapidly fatal issue was probably accelerated by the occurrence of gaseous distension of the colon and stomach. *February 3rd*, 1880.

21. *Hernia into the vaginal process of peritoneum and undescended testicle.* (*Card specimen.*)

Exhibited by Frederic S. Eve.

Part of the right innominate bone with Poupart's ligament. Just above and parallel with Poupart's ligament is an incision through the aponeurosis of the external oblique muscle, laying open the inguinal canal, which was made in the operation of herniotomy. Protruding through the incision, just above the external ring, and occupying the canal of the vaginal process of peritoneum, is an undescended, ill-developed testicle; on its outer side is a knuckle of intestine, which has been inserted to show the position occupied by the strangulated gut. The termination of the vaginal process protrudes from the external ring.

History.—The specimen was taken from a boy, æt. 12, who was operated on for congenital hernia on the right side. The testicle on that side had remained in the inguinal canal, but a rupture had never before descended. The intestine had been strangulated nearly three days before the operation was performed. Death resulted from peritonitis.

The specimen is preserved in the museum of St. Bartholomew's Hospital, Series xvii, No. 103. *October 21st*, 1879.

22. *Patent vaginal process of peritoneum.* (*Card specimen.*)

Exhibited by Frederic S. Eve.

The left testicle and vaginal process taken from the same patient as the preceding specimen. The testicle had descended into the scrotum, but the vaginal process is patent; a glass rod is inserted into it. *October 21st*, 1879.

V. DISEASES, ETC., OF THE GENITO-URINARY ORGANS.

1. *The histology of granular kidney.*

By Robert Saundby, M.D.

[With Plates V and VI.]

Bright recognised three well-marked pathological types of diseased kidney, associated with albuminuria, but was ignorant of the intimate nature of the morbid process. In accordance with current pathological doctrines he regarded each variety as a stage in the development of a deposit or growth giving rise to granulations, and hence he called the whole process "granular degeneration." At present we restrict the term "granular kidney" to what Bright regarded as the third stage, and it is believed by many to have pathological and clinical characters which distinguish it altogether from the other two. This separation was not effected early in the history of Bright's disease, nor was it completed without opposition; indeed, it cannot be said that at the present time the points of distinction are generally agreed upon. The naked-eye appearances are sufficiently characteristic. It is only when we attempt to determine the intimate nature of the changes which have occurred that differences of opinion arise. Bright's doctrine of a morbid deposit soon gave way to the theory of an inflammatory process, first taught by Rayer, and confirmed by the histological researches of Johnson, Frerichs, and Reinhardt. According to Frerichs, the three varieties or types described by Bright corresponded to three stages of an inflammatory process, characterised respectively by:—1, hyperæmia with exudation; 2, fatty degeneration of the exudation; 3, absorption of the degenerated exudation and

DESCRIPTION OF PLATES V & VI.

Illustrating Dr. Saundby's paper on the Histology of Granular Kidney. From drawings by himself. (Page 148.)

PLATE V.

FIG. 1.—A mass of proliferating epithelium from the cortex of the kidney. *a*. Enlarged nucleus; *b*. hour-glass nucleus; *c* and *d*. cells containing two nuclei; *e*. tubules filled with young cells. Hartnack, oc. 3, obj. 8.

FIGS. 2, 3, 4, and 5 represent semi-diagrammatically the stages of cell proliferation observed in the epithelium in Fig. 1.

FIG. 6.—Convoluted tubules filled with small round cells, derived as above described. Hartnack, oc. 3, obj. 8.

FIG. 7.—Transformation of a group of tubules, filled with young cells, as seen in Fig. 6, into connective tissue, by the conversion of the round cells into spindle and stellate cells. Hartnack, oc. 3, obj. 8.

FIG. 8.—Cyst formation within the convoluted tubules, by the myxomatous degeneration of the cellular tissue produced by the proliferation of their lining epithelium. Hartnack, oc. 3, obj. 8.

FIG. 9.—Straight tubes undergoing transformation into connective tissue. The epithelium has proliferated and filled the tubes (at *a* and *a*) with young cells. At *b* the tubule is seen dwindling to a row of spindle cells, and becoming lost in the connective tissue around it. Hartnack, oc. 3, obj. 8.

PLATE VI.

FIG. 10.—A Malpighian body, showing proliferation of the endothelium covering the tuft and lining the capsule, with swelling of the fibrous tissue of the capsule. Hartnack, oc. 3, obj. 8.

FIG. 11.—A Malpighian body, degenerated by myxomatous transformation of the cellular tissue, resulting from the proliferation of the endothelium of the tuft and capsule. Hartnack, oc. 3, obj. 8.

FIG. 12.—A small blood-vessel from a part of the kidney in which the fibroid degeneration was much advanced, showing its walls composed of concentric layers of smooth muscular fibres, with some elastic tissue and a few small spindle cells. Hartnack, oc. 3, obj. 8.

FIG. 13.—An arteriole from the same part of the same kidney, showing (at *a*) the swollen elastic lamina with its layers separated and interspersed with nuclei. Next to the lumen is a broad band of lowly organised connective tissue, derived by proliferation from the endothelium. Outside the elastic lamina is the muscular coat, looking œdematous and containing a few muscular fibres. Outside the muscular coat is a cellular coat, which cannot be separated from the connective tissue in which the vessel is embedded. Hartnack, oc. 3, obj. 8.

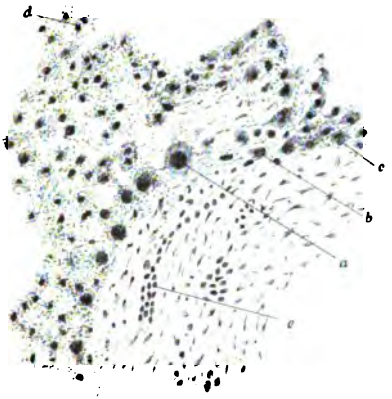

Fig I.

Fig II.

Fig III.

Fig IV.

Fig V.

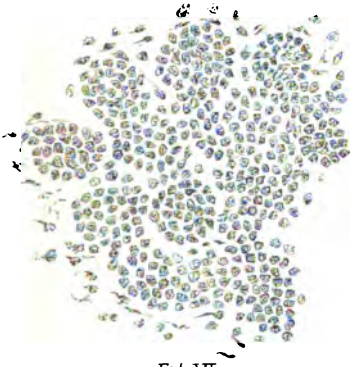

Fig VI.



Fig VII

Fig VIII



Fig IX

R. Saundby del

E. Noble. Smith fecit

Martin, Pros. Imp.

Fig. X.

Fig XII

Fig XI

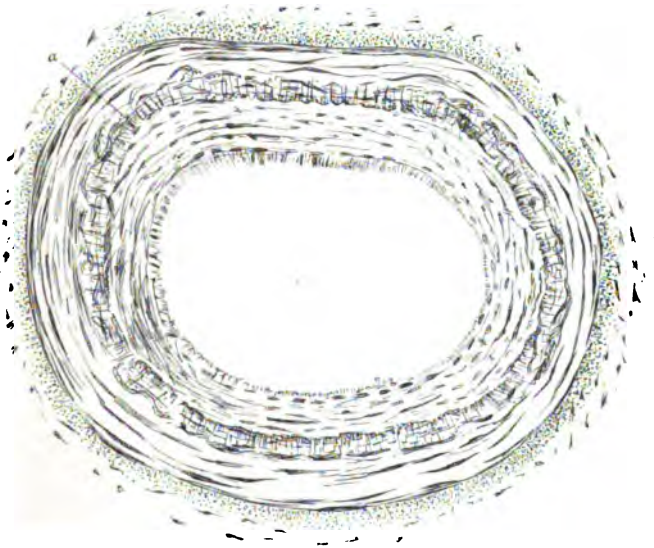

Fig XIII

R. Saundby del.

E. Noble Smith, fecit

atrophy of the organ. Nothing could seem more apt than this description, but it soon had to yield its place to the doctrine of parenchymatous inflammation brought forward by Virchow, according to which the seat of the lesion was the epithelium of the kidney. Dr. Johnson adopted this view with slight modifications, as he believed that the, so-called, second and third stages often occurred independently of the first, or at least that they were not preceded by an acute inflammatory attack. He drew attention to several points in the histology of these changes, especially to the small cells occupying the tubules and the hypertrophy of the walls of the blood-vessels as characteristic of the small red kidney, which he regarded as quite distinct from the small kidney which may follow an acute attack.

Traube was the first to lay down clearly the proposition that granular kidney is a distinct disease, separable by clinical and pathological features from all other varieties of Bright's disease. He maintained that the seat of the inflammation was not in the parenchyma, as in the other two forms, but in the interstitial tissue.

Grainger Stewart has brought forward evidence that the small contracted kidney may result from an acute attack, but he recognises the existence of a distinct variety, to which he gave the name of the "cirrhotic kidney," as he formerly regarded it as the consequence of a non-inflammatory hyperplasia of the connective tissue; but in 1878 he announced that he had abandoned this opinion and accepted Traube's view.

Gull and Sutton also support the doctrine of the independent nature of the lesion in granular kidney, and have described it as consisting in the deposit of a hyalin-fibroid material in the intertubular parts including the vessels, and in atrophy of the tubular and intertubular structures.

In 1874 Kelsch published a very minute account of the histology of granular kidney, in which he supported Traube's opinions. According to Kelsch, the seat of the lesion is in the intertubular tissue around the convoluted tubes which occupy the peripheral portions of what are known as the pyramids of Ferrein, the centres being formed by the straight tubes, a disposition of the lesion which he regards as explaining the granular appearance of the surface of the kidney. In 1878 Prof. Charcot endorsed these views, and insisted more especially on the appearance of the small

cells within the tubules, already described by Johnson, as the fundamental characteristic of the changes in the small red kidney.

The views of Johnson, Traube, and Gull and Sutton have each the great merit of bringing into strong relief one side of the process, and their fault is that while insisting upon one point they ignore or deny others. If we take them together we may regard the first as emphasising the changes in the tubules, the second the changes in the stroma and Malpighian bodies, and the third the changes in the blood-vessels.

Traube's view of the pathology of granular kidney is widely accepted, and we need no better proof of this than the almost universal adoption in all foreign countries of the synonym "interstitial nephritis." In this country Traube has many followers, but, either from caution or conservatism, the old names are more popular than this more precise term. We may congratulate ourselves upon our caution in this matter, as the tide of opinion seems to have turned, and several writers have shown indications of their belief that these hard-and-fast distinctions based on the supposed anatomical seat of the lesion cannot be maintained. Thus, Rosenstein has said that there cannot properly be said to exist either strictly parenchymatous or strictly interstitial nephritis, both tissues being affected, and both the large white and the small red kidneys resulting from *diffuse* inflammation. This latter statement is confirmed by the experiments of Grawitz and Israel, who found that after temporarily clamping the renal artery a diffuse nephritis occurred, which passed indifferently into either the large white or small red kidney. In the latter case they noticed particularly the absence of any nucleation in the stroma. Another writer, Dr. Carl Weigert, has stated that both the parenchyma and the stroma are affected in all cases of chronic Bright's disease, and that pure parenchymatous nephritis is only seen as an acute disease. Bamberger has announced his entire concurrence in these views.

My own observations have led me to similar conclusions. The small red and large white kidney, and all the intermediate varieties, are the result of inflammation which affects all the tissues, but varies very greatly in intensity. The parenchyma being the most highly organised tissue, suffers most in proportion to the intensity of the inflammation. The large pale kidney is the result of prolonged

or repeated severe inflammation; on the other hand, the small red kidney indicates an inflammatory process of prolonged duration but of minimum intensity; and the intermediate varieties correspond to all the different degrees of intensity possible between the two extremes. The fact of the existence of an indefinite number of intermediate or mixed forms between the two typical varieties of the large white and the small red kidney is a strong argument in favour of the doctrine of unity.

Dr. Greenfield regards the "large, pale, granular kidney," the "small, red, granular kidney," and the various intermediate, forms as a series in which the first is "typical of origin by essentially interstitial growth," the second by "atrophic change," and the intermediate forms by combinations of these two processes. In the small red kidney he states that the disease commences in the vessels and glomeruli, the affection of the latter being fibrous transformation with adhesion of the capillary tuft to Bowman's capsule, as a consequence of which, "*or of an associated inflammatory process*," the tube wastes. "In the larger form there is much more true interstitial growth or exudation."

The "associated inflammatory process" which Dr. Greenfield throws in, by the way as it were, to eke out his hypothesis, constitutes, in my opinion, the link which binds the whole together in one pathological series.

The preparations from which the drawings illustrating the descriptions I am about to give, were taken from two cases, of which abstracts of the *post-mortem* appearances are subjoined:

Case 1.—J. W—, male, æt. 49. Ascites and œdema of lower limbs. Heart, 21 oz., valves competent, muscular fibre healthy. Liver weighed 54 oz., appeared healthy, but under microscope showed commencing cirrhosis (specimen shown). Spleen enlarged and rather hard. Kidneys together weighed 7 oz., small, lobulated, with many cysts on surfaces; capsules thickened and opaque; cortices about one line thick, dark coloured; cut surfaces showed open mouths of dilated vessels.

Case 2.—M. H—, female, æt. 50. Ascites and œdema of lower limbs. Arteries of pia mater thickened and pigmented. Heart weighed 9 oz.; muscular fibre pigmented; valves healthy. Liver large, smooth, soft, yellow on section; old peritonitic adhesions compressed portal vein. Spleen small and dark coloured. Kidneys together weighed 7oz., surfaces granular and lobulated;

capsules thickened and adherent; no cysts; cortices only one line thick,

I shall deal with the histological details in the following order: *a*, the convoluted tubes; *β*, the straight tubes; *γ*, the Malpighian bodies; *δ*, the vessels; *e*, the connective tissue.

a. The convoluted tubes.—The cortex of the wasting organ presents the convoluted tubes in varying degrees of destruction. The changes may be best considered as they involve—1, the epithelium; 2, the basement membrane.

1. *The epithelium.*—As already mentioned, the changes in the epithelium vary with the intensity of the inflammatory process. In the more acute cases the epithelium proliferates rapidly, and the tubules become filled with fattily-degenerated cells. This is too well known to need further remark, but it is not generally understood that, even in the typical small red kidney, the epithelium also proliferates, although to a comparatively small extent. Plate V, fig. 1, shows a mass of epithelium from the cortex of the kidney of Case 1, undergoing proliferation; its protoplasm is *clear; the nuclei stain strongly with carmine; they are enlarged* (*a*), *oval or hour-glass shaped* (*b*), *or there are two nuclei* (*c* and *d*), and finally the tubules become filled with young cells (*e*). These changes are seen better in figs. 2, 3, 4, 5, and 6. This appearance of small cells filling the tubules was first described by Johnson, as already mentioned, and has been confirmed by Cornil, Ranvier, Kelsch, Charcot, and others, but I am not aware that any one has previously satisfactorily explained their origin. Kelsch imagined them to be due to the proliferation of the endothelia of the basement membrane. Moreover, none of these authors have followed the further changes in these young cells. One of the subsequent transformations is well seen in fig. 7, which represents a group of tubules like those seen in fig. 6, undergoing conversion into fibrous tissue by the elongation of these young cells into spindle cells, and their gradual metamorphosis into a hyaline connective tissue containing a few stellate and spindle elements.

Another mode in which the destruction of the tubules is completed is shown in fig. 8, which represents a comparatively early stage of the process. The drawing shows cross sections of several convoluted tubules filled with round cells, which are not so closely packed as in fig. 6. The sections vary very much in diameter, some of the tubules being evidently dilated. In some there are very few cells, in others none, the whole lumen being filled

with a hyaline material, staining very feebly with carmine. These appearances, which may be very readily seen, were first described by Mr. Simon, more than thirty years ago, as "cystic degeneration of the kidney," but have not received due attention. They are, in fact, due to the formation of a myxomatous or gelatinous connective tissue from the young cells filling the lumen, by which the basement membrane is distended, and a cyst is formed.

Besides these two definite changes a great deal of the epithelium appears to be undergoing simple fatty degeneration and wasting.

2. *The basement membrane* becomes swollen and hyaline, and is lost in the new formation of connective tissue, or forms the wall of a cyst.

β. *The straight tubes.*—The medullary parts of the kidney present, to the naked eye, much less appearance of alteration than the cortex. This is, in the main, due to the fact that the bulk of the cortex is made up to such a great extent by the large secreting epithelium of the convoluted tubules, that its destruction causes a very marked decrease in the thickness of the cortex; but the medullary part is made up of rows of narrow tubules lined with a comparatively small epithelium, and of numerous arteries and veins, so that the destruction of the straight tubules does not produce a very striking difference in the size of the pyramids. But the lesions are essentially the same as those I have described in the convoluted tubes. Fig. 10, shows rows of straight tubes filled with young cells (*a*), lying between the convoluted tubes, the epithelium of which is very fatty. This drawing is from Case 2. One of the tubules is seen to be dwindling to a simple row of spindle cells.

These appearances are so plain that I can conceive no other interpretation being put upon them by any one who studies the original preparations or the drawings with a mind free from prejudice. The objections that have been urged against this interpretation are (1) that it controverts Remak's law, and (2) that the new formation of all connective tissue arises from leucocytes. As to Remak's law, it may be said that all biological laws have exceptions, and, as Dr. Creighton has remarked, a physiological law may not hold good in pathology. But, by the concurrence of most authorities on embryology, the Wolffian ducts and the Wolffian tubes and glomeruli are formed from the mesoblast, so that Remak's law does

not touch this particular case. At the same time I consider that this process is quite analogous to the formation of fibres from the hepatic epithelium in cirrhosis of the liver, described by Dr. Hamilton, and from the epithelium of the mamma in breast tumours, maintained by Dr. Creighton. I possess preparations and drawings which confirm the statements of both these observers. I have, moreover, little doubt that the same process may be seen in the lung.

As to the origin of the connective tissue in the healing of wounds, that is a point which may be fairly considered as *sub judice*. True, Tillmanns asserts that pieces of liver or kidney hardened in alcohol, when introduced into the peritoneal cavity, have breaches in their surfaces healed by wandering cells from the blood-vessels, but on the other hand Von Wyss showed long ago that non-penetrating wounds of the cornea heal by proliferation of the epithelium at the edges of the wound, without any immigration of leucocytes or proliferation of the cellular elements of the true corneal substance.

γ *The Malpighian bodies.*—We know that the Malpighian bodies are very early affected in this disease. Thoma has shown that they are abnormally favourable not only to fluids but to colloids and small solids, such as crystals of cinnabar, and this in places where no changes can be detected with the microscope. Moreover, we meet with many cases corresponding to Traube's division of capsular nephritis, in which the lesions in these structures are much more advanced than elsewhere, and sometimes, as in one of the present cases (Case 1), not a single Malpighian body appears in a section of kidney nearly a quarter of an inch in diameter.

That the changes would manifest themselves very early in these structures is what we might conclude *à priori*, if we regard the morbid process as a chronic inflammation. In all inflammations as well as in other affections of the connective tissue, the arterial coats, especially the adventitiæ, show the first signs, and are the most advanced seats of the change, whatever it may be. These changes in the Malpighian bodies, so far as they can be followed with the microscope, consist in proliferation of the endothelium lining the capsule and covering the tuft, and the formation of a mass of cellular tissue by the blending together of the growth from the two sources. Fig. 10, Pl. VI, shows one stage of this process, the capsule and tuft being covered with young cells.

The further stage is seen in fig. 11, in which the cellular mass has become converted into a delicate gelatinous tissue, containing stellate elements. Still later the contents may be quite hyaline and stain feebly with carmine, forming a little mucous or colloid cyst, the whole process being quite analogous to that which I have described in the tubules, with this exception, that these Malpighian bodies are not enlarged, or at least not to any notable degree; often, indeed, they are small. The drawings illustrating these changes were taken from Case 2.

δ *The blood-vessels.*—We owe to Thoma the careful measurements which demonstrate, contrary to the statements of many observers, that the arteries of the kidney substance are absolutely *dilated*, in spite of the increased thickness of their walls, and that narrowing of their lumina is exceptional. He showed besides, by careful injections, that fluid runs well into the Malpighian bodies, but that the efferent artery is often destroyed and the capillary plexuses upon the tubules are to a large extent obliterated. The main point at issue is as to the histological details of the changes in the coats in the vessels.

Johnson, in his original papers, described hypertrophy of the circular and longitudinal fibres of the coats, meaning by the longitudinal fibres the inner coat. Gull and Sutton speak of the change as affecting the outer coat mainly, and deny that any true hypertrophy of the muscular wall is present. Figs. 12 and 13, Pl. VI, taken from two vessels of the same kidney from Case 1, are sufficient to show that both these descriptions are correct, and that Gull and Sutton err only when they deny the hypertrophy of the muscular wall, which though not constant is quite common. Fig. 13 is a vessel much dilated, with little or no hypertrophy of the muscular coat. The internal elastic lamina (*a*) is swollen, its layers are separated and interspersed with nuclei; within is the much thickened endothelial layer converted into a delicate fibrous tissue; outside the elastic lamina is the muscularis, showing widely separated spindle-shaped nuclei, and looking as if it were œdematous. Outside this, again, is a cellular connective tissue, in which no adventitial coat can be distinguished from the surrounding connective tissue. Fig. 12, on the other hand, represents a vessel which is made up almost entirely of muscular fibres. Near the inner margin some fibres of elastic tissue can be recognised on closer inspection, and some of the cells in the neighbourhood are more like connective-

tissue spindle cells than muscular fibres, while a few are round or oval, so that probably a transition is taking place, and we have to do with a new formation of muscular fibres. This is analogous to the growth of vessels by concentric layers of spindle cells, which may be readily seen in granulation tissue.

Some of the drawings of Gull and Sutton suggest the notion that they were actually made from vessels such as this (fig. 12), but that some imperfection in their histological manipulation preventing their recognising anything more than the blurred and indistinct structures they have represented in their plates.

e. The connective tissue.—There is so little connective tissue in the normal kidney apart from the structures we have been considering that it is open to question whether this title is correct. But in the diseased kidney the intertubular spaces are so much more easily seen, and are so obviously occupied by connective tissue of some sort, that it is necessary to refer to it. The changes in the capsules of the Malpighian bodies, the adventitial tunics of the vessels, and the basement membranes of the tubes consist mainly in swelling and hyaline transformation. There is no appearance of interstitial nucleation,[1] such as may be seen after ligature of the ureter, or in the early stage of surgical kidney. The absence of this is due simply to the essentially chronic nature of the process, such changes as take place partaking more of the character of growth than inflammation.

So far as can be seen, the changes are confined to those of swelling or broadening, and hyaline transformation, the results of simple œdema or surplus of plasma from the blood-vessels. The connective tissue suffers little from the abnormal state of the organ on account of its low organisation, though it tends to be reduced, as we have seen, to the gelatinous type, which is one of the lowest in the series of connective substances.

Bibliography.

Bright.—Reports of Medical Cases, London, 1827. Cases and Observations illustrative of Renal Disease—Guy's Hosp. Rep., vol. i, p. 338.

Johnson.—Med.-Chir. Trans., vol. xi, p. 1. Ibid., vol. xxxiii, p. 107. Disease of the Kidney, London, 1852. Lectures on Bright's Disease—Brit. Med. Journal, 1873.

[1] Since writing the above, a case has come under my notice which has convinced me that the kidney in this disease is liable to transient inflammatory attacks, in which the intertubular stroma becomes filled with lymphoid cells.

Grainger Stewart.—Bright's Disease, Edinburgh, 1868.
Gull and Sutton.—Med.-Chir. Trans., vol. lv, p. 273.
Kelsch.—Arch. de Physiologie, 1874, p. 722.
Charcot.—Le Progrès Médical, December 22nd, 1877, and February 2nd, 1878.
Rosenstein.—Paper read at the International Medical Congress, September, 1879.
Grawitz and Israel.—Virchow's Archiv, Bd. lxxvii, s. 315.
Weigert.—Volkmann's Samml. Klin. Vortr., 1879, Nos. 162–3.
Greenfield.—An Atlas of Illustrations of Pathology—New Syd. Soc., 1879.
Hamilton.—Journal of Anatomy, January, 1880.
Creighton.—Contribution to the Physiology and Pathology of the Breast, and its Lymphatic Glands, London, 1878.
Von Wyss.—Virchow's Archiv, Bd. lxix.
Tillmanns.—Ibid., Bd. lxxviii, Heft 3.
Thoma.—Ibid., Bd. lxxi, Heft 1 and 2.
Simon—Med.-Chir. Trans., vol. xxx, p. 141.

March 16th, 1880.

---

2. *Granular contracted kidney.*

By W. S. Greenfield, M.D.

[With Plate VII.]

Having been requested to show some specimens illustrative of the pathology of granular contracted kidney, with especial reference to the points raised by Dr. Saundby, I have brought before the notice of the Society a number of microscopic specimens illustrative of series of changes which are to be found in several forms of Bright's disease, and which appear to me to be especially instructive in relation to the more chronic and latent form known as the granular contracted kidney.

I must, however, premise that I do not pretend to discuss all the questions raised by Dr. Saundby's valuable communication; in fact I have not had a sufficient opportunity of ascertaining his views or examining his specimens to be able to do so. I have merely brought together in a short notice some of the specimens upon the study of which my own views as to the pathology of the disease have been formed, and I propose to give a general outline of these views. Of the specimens thus shown, only a very small number can be illustrated by drawings, owing to want of time for their preparation.

I shall best fulfil the end in view if I briefly state the special

points to which I desire to call attention, not because they are the only important points in the pathological histology, but because they have, I think, been too much overlooked. First, the glomerular changes common to several forms of Bright's disease, their nature, and the relation which they hold to its evolution in various forms; second, the relations of the granular contracted kidney to the subacute or chronic disease which follows an acute attack of Bright's disease, and which has its anatomical equivalent in the so-called "large white kidney;" and, third, the relation of scarlatinal nephritis to common acute nephritis, and to the granular contracted kidney.

My conclusions, based on the examination of a very large number of specimens of these various forms of renal disease, are somewhat to this effect.

1. That the glomerular changes illustrated in the various specimens shown are of almost constant occurrence in chronic Bright's disease, including the granular contracted kidney in its various forms, the so-called "large white" and "fatty" kidneys; and also in many acute cases; being especially constant in scarlatinal nephritis, and the nephritis following pregnancy, but also not infrequently occurring in other forms. That these glomerular changes may constitute almost the sole persistent lesion after scarlet fever, or in acute Bright's disease; but are the most constant change in the evolution of the chronic granular contracted kidney; that in the "large white" kidney they are also very constant.

As to the relation of the "large white" kidney and the granular contracted kidney, it may be roughly stated in this way. That whilst the former is essentially a diffuse interstitial and parenchymatous inflammation, in which changes in the glomeruli are associated with general interstitial inflammation, the granular contracted kidney in its most typical form, is not necessarily attended by interstitial inflammation, but may be dependent on primary glomerular change for its complete evolution. In other words, whilst the glomerular change is essentially of the nature of a chronic inflammation, the subsequent changes in the other secreting structures are simply atrophic.

The changes in the glomeruli, though presenting some differences, dependent on the rapidity of their evolution, are not widely different in the acute and chronic forms. The specimens shown are from

DESCRIPTION OF PLATE VII.

This Plate illustrates Dr. Greenfield's communication on the Local Changes in the Granular Contracted Kidney and allied conditions. From drawings by himself. (Page 157.)

FIG. 1.—Granular contracted kidney. Segment of the cortex seen under a low power (1 inch), showing a somewhat conical patch of disease.

a. Region of convoluted tubes, occupied by an apparently fibrous tissue, composed to a large extent of atrophied tubes.

a'. Denser fibrous tissue in deeper part of cortex.

b. Atrophied glomeruli, with thickened capsule and remains of the capillary tuft.

b'. Other atrophied glomeruli, completely transformed into masses of concentric fibrous tissue.

c. A glomerulus persisting, without obvious morbid change.

d. Thickened vessels.

e. Convoluted tubules in surrounding tract, somewhat dilated.

f. Colloid casts in these tubules.

FIG. 2.—Part of the apparently fibrous patch in the cortex, from *a*, Fig. 1, under higher power (⅛th inch), showing it to be largely composed of wasted tubules.

a. Wasted tubules, filled with remains of cells and nuclei.

b. Interstitial tissue, almost entirely consisting of remains of capillaries.

FIG. 2A.—Outline sketch of healthy, but somewhat dilated, convoluted tubes from a corresponding situation in another part of the same kidney, seen under the same magnifying power.

FIG. 3.—Malpighian body, from a case of subacute interstitial nephritis, "large white kidney," of eighteen months' duration, following albuminuria of pregnancy.

a. Capsule of Bowman, unaltered.

b. Capillary tuft, represented only in outline.

c. Fibrous tissue surrounding the capsule, arranged in concentric layers.

d, e, f. New growth of tissue between the capsule and the glomerulus, chiefly arising from the cells lining the capsule. *d.* Commencing proliferation of endothelial cells. *e.* Mass of similar cells hardly yet organising. *f.* Cells becoming transformed into laminated connective tissue, which as yet is only a loose "adenoid" structure; laminæ composed of flattened and branched cells, enclosing space in which are rounded or oval cells.

g. Commencing proliferation of layer of cells covering the capillaries; adhesion to the growth from lining of capsule is commencing.

h. Point, where adhesion of the capillary tuft to the new growth has occurred.

FIG. 4.—Atrophied Malpighian body from another case of subacute interstitial nephritis, "large white kidney;" also following albuminuria of pregnancy.

a. Connective tissue surrounding the Malpighian body, separated by a narrow crevice from it (? lymphatic space).

b. Laminated connective tissue, occupying the position of the thickened capsule.

c. Fibrous nodule, corresponding with the wasted capillary tuft.

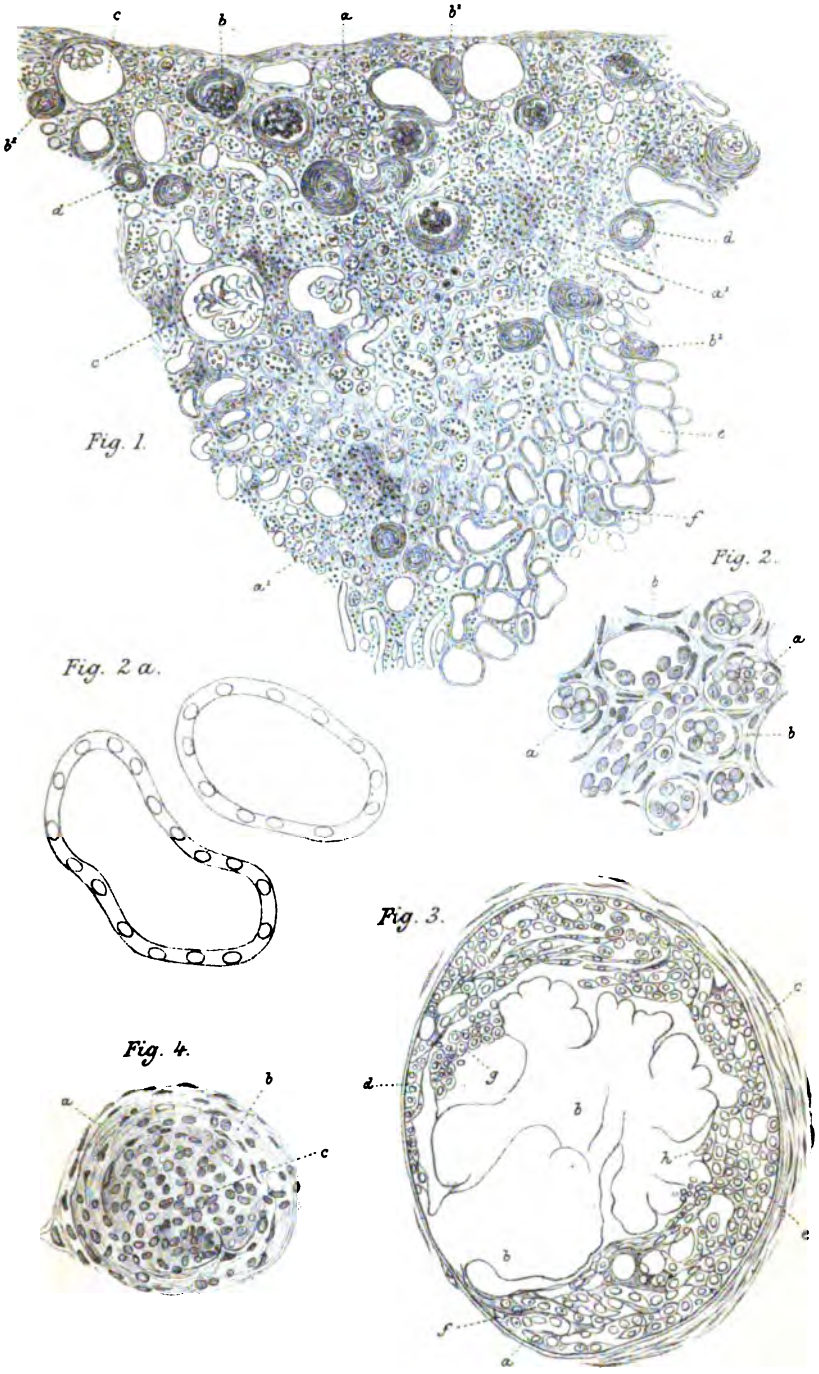

W. S. Greenfield ad nat. del.

F. Huth, Lith. Bc

cases of very various origin and duration; of scarlatinal nephritis there are four specimens, varying in the length of time from six weeks to twelve months; of nephritis following the albuminuria of pregnancy there are two specimens of twelve and eighteen months' duration respectively; and of granular contracted kidney there are specimens of the very large form with apparently much interstitial inflammation, and others of small granular contracted form. In all these analogous changes may be observed.

I have elsewhere[1] made a division of the change in the Malpighian bodies into three anatomical forms, classifying the changes as occurring in the capsule itself, external to it, and in its interior. Either of these may exist independently of the other, but the most important series of changes are those found in the interior of the capsule, between the capsule and the capillary tuft, and leading to the destruction of the function of the glomerulus. With regard to the change external to the capsule, it may be observed in cases of acute inflammation as an increase of nuclei around the capsule, especially near the afferent arteriole. As in other inflammations, there is a migration of leucocytes and liquor sanguinis from the smaller vessels, and this may be especially localised around the capsule. Subsequently the inflammation may lead to the formation of a patch of connective tissue around or alongside the capsule, and may end in its compression. Or in chronic cases, chronic inflammation may produce a similar result. Of the changes in the capsule itself the most important is a process of thickening analogous to the change in the intima of arterioles in endarteritis deformans, leading either to a simple thickening, or a lamination of the capsule.

The internal changes usually commence with a proliferation of the endothelium lining the capsule; sometimes also of that covering the capillary tuft. This process may be of very slow evolution, and then proceeds in an orderly manner, but in some cases it takes place very rapidly, as for example, in scarlatinal nephritis, and then masses of cells may be heaped up in irregular order between the capsule and the capillary tuft. In one of the specimens shown, from a case of scarlatinal nephritis, fatal about the fortieth day from the onset of the fever, all the glomeruli are in this condition. The capillaries are then usually obscured by a mass of cells, originating from the endothelium covering them, and probably from proliferation of the connective-tissue corpuscles in the stroma of the tuft. A more regular

[1] 'Atlas of Pathology,' New Syd. Soc., Art. "Kidney."

and somewhat slower form, of the same process, is seen in Plate VII, fig. 3, from a case of "large white kidney" following pregnancy. Here the various stages of the growth are well seen, at one point (*d*) the proliferation of the cells lining the capsule being seen; at *d*, *e*, *f*, their multiplication into masses, which become adherent to the capillary tuft, and then are transformed into connective tissue, in a manner which strikingly resembles the changes in the epithelioid cells of tubercle by which they are converted into fibrous tissue. Whether by slow or rapid stages, the new growth is transformed into a laminated connective tissue, which gradually contracts and leads to compression and atrophy of the capillaries. No doubt this process is facilitated by the changes which go on in the capillaries and the connective tissue investing them, as well as by the partial loss of function which ensues on obstruction of the outlet for watery transudation, through filling up and obliteration of the space between the tuft and the capsule. Gradually the whole glomerulus shrinks into a small fibrous knot, in which, however, the outlines of the structure may still be seen (Plate VII, fig. 4). Very various degrees of change in the several parts affected may occur, hence sometimes the change seems to be limited to the capsule; at others it is mainly on one side, so that part of the tuft is compressed, the rest looking fairly healthy.

It sometimes happens, when the process takes place more gradually, that layers of fibrous tissue are formed successively, which do not become adherent to the capillary tuft, but leave a space between, so that the functional action of the capillaries, though hindered, is not absolutely prevented. But it must be remembered that the change is often especially marked around the entry of the vessels, and that they are liable to be partially strangled by its contraction, and to this are no doubt due part of the degenerative changes sometimes seen in the capillaries at a comparatively early stage of the process.

In some cases, especially, so far as I have seen, in the large granular kidney, some of the glomeruli, although the capillaries are adherent all round to the capsule, appear to be much larger than natural, as if they had become swollen rather than contracted. It may be that this is due to a previous distension, similar to that which occurs in the convoluted tubes.

It is unnecessary now to dwell further on these glomerular changes, as my object is rather to call attention to them than to

discuss them. The sequence of events resulting from this change must be mentioned later, in speaking of the pathology of the granular contracted kidney; only this must be said, that in this process of evolution of connective tissue from the endothelial, or, as some prefer to call them, epithelial, cells, is seen the only instance which I have been able to trace of such a change in granular contracted kidney, *i. e.* I have entirely failed to trace any similar conversion of the epithelium of the convoluted tubes into fibrous tissue. Moreover, as the change I have described is more common in the acuter forms of renal disease, it is not to be considered as peculiar to the granular contracted kidney.

Passing next to consider certain points in the histology and pathology of the true granular contracted kidney, I would call attention to the fact that a large part of the changes seen in the most typical forms may be regarded as due to a primary change in the vessels and glomeruli, or, perhaps it would be more accurate to say, in the glomeruli first, then concurrently in the arteries and in the special excretory tracts, both occurring as a consequence of the glomerular changes. The study of the evolution of these changes cannot be made upon the organ when in an advanced condition of the disease; we must seek to trace it from its earliest stages. There is a considerable variety, however, even in the advanced degree of the disease, and, I think, sufficient to lead to a belief in different modes of origin. The mere facts of a granular surface, thickened and adherent capsule, cortex containing microscopic and macroscopic cysts, and thickened arteries, are not necessarily indicative of a constant and uniform origin. If we analyse them we find that they indicate merely that the disease process has affected a particular region first, viz. the region of the interlobular artery, and that usually the change has commenced at the periphery, viz. near the surface of the organ.

As I have shown elsewhere, the general distribution of the change in the granular contracted kidney is the same as that of many acute cases of nephritis, especially of those following scarlet fever, and we have clinical evidence that the ultimate evolution of this acute process may lead to a condition indistinguishable, with the naked eye, from the granular contracted kidney.

If, however, we take only cases which have run a latent course and in which the general symptoms of the chronic disease have also been observed, and compare them with specimens which show similar changes in an earlier stage, but in which death has been due to some

other cause, we find that the changes appear to be developed in many cases in a regular order. The earliest changes are found in and around the Malpighian bodies which lie nearest to the surface, those in fact which correspond to the terminal branches of the interlobular arteries. These changes are similar to those already described, but they tend to be evolved slowly, to show marked thickening of the capsule, and to degenerate completely into fibrous knots. It may be that a similar change is found scattered through the cortex in an irregular manner; and if not, there are often a few similarly affected glomeruli in the deeper part nearest to the bases of the papillæ. But it may usually be observed that as the disease progresses it travels down the region of the artery, more and more glomeruli being involved, and a somewhat conical fibrous-looking patch, with its base to the surface, being found in the region of a certain interlobular artery. Such a conical patch, somewhat advanced in degree, is seen in Pl. VII, fig. 1. In the patch we see, as a rule, a number of glomeruli, mostly shrivelled and transformed into fibrous knots, here and there crowded together; with them also are a certain number of thickened vessels, and the whole massed together by an intermediate substance which has a somewhat fibrous aspect, and is often spoken of as interstitial inflammatory tissue. If, however, we examine this tissue with higher powers, we find that in many parts there is no evidence of interstitial inflammation or fibrous tissue, but that instead the tissue is almost entirely made up of shrivelled uriniferous tubules, which contain the remains of epithelium chiefly in the form of cell-nuclei. (See Pl. VII, fig. 2.) The arrangement of the nuclei of the tissue which intervenes between them shows at once that it consists of capillaries either obliterated and degenerated, or still pervious. In other parts we find small patches of true fibrous tissue; the existence of the latter is, no doubt, evidence of the presence of a certain degree of chronic inflammation, but not a proof that this is the primary change. If we assume that the glomerular change is the initial one, we may explain a large part of the appearances without the subsequent intervention of inflammation. Atrophy of the convoluted tubes follow as an almost necessary result of the complete obliteration of glomeruli, for the watery transudation through the latter being arrested, and a part of the capillary circulation also cut off, there is neither proper performance of function nor proper blood supply to the corresponding region of the labyrinth, and atrophy follows as a natural result.

Again, the obstruction to the circulation of the corresponding interlobular artery would tend to increase of tension and consequent thickening and endarteritis, which subsequently reacts on the more distant arteries.

It may, then, be suggested that a certain number of the cases of granular contracted kidney are essentially degenerative, arising in connection with changes in the terminal twigs of the peripheral arteries. But, bearing in mind some experimental results as to the elimination of poisons and the distribution of emboli, we cannot but suspect that here also chronic irritation by some product conveyed especially to the peripheral glomeruli has a large share in setting up the chronic inflammation. It is evident also that in these glomeruli which are more distant from the large arterial trunks, and by the arrangement of their venous and lymphatic system less adapted for perfect drainage, such morbid products will be favoured in their action by the tendency to stasis, especially if there be the slightest antecedent degeneration of the arteries.

The production of a certain quantity of connective tissue subsequently is a fact of small importance, for in all degenerations of organs such a fibrous change is apt to occur.

If now we examine the conditions found associated with the more acute cases of renal inflammation, when the glomerular change is intense, we often find that there is interstitial inflammation in a high degree, involving not only the more peripheral portions, but extending deeply into the substance of the organ. This form of nephritis may be described with much more accuracy as an interstitial nephritis, and the term will include both a large number of cases of the so-called "large white" kidney, and of the large granular kidney. But as the consideration of these would lead me far beyond the scope of my illustrations, it must suffice to mention this fact.

With regard to scarlatinal nephritis, I must again observe that the changes found in this disease are extremely various, but that in nearly all severe cases the glomerular changes are well marked. I must, however, mention that although the examination of a large number of cases of scarlatinal nephritis had led me to believe that there was a greater tendency to glomerular change than in cases of non-scarlatinal origin, subsequent observations have shown that similar changes have been present in many cases in which scarlet fever could not in any way be traced, or even reasonably suspected; and I am inclined to doubt whether it is possible to affirm or suspect

a scarlatinal origin on the ground of microscopic examination alone. The study of the changes which occur in the kidney subsequent to a moderate degree of affection of the glomeruli would, I believe, throw great light on the evolution of the granular contracted kidney. In the more intense cases there is, as I have shown, a very close resemblance to granular contracted kidney in the distribution of the lesions.

I have said nothing of the changes in the vessels in chronic Bright's disease, and as I have not given any illustrations of the specimens shown, I may simply say that whilst all the changes of endarteritis, periarteritis, and thickening of the middle coat occur, they are not at all regularly distributed, and, though constant, they appear to be more commonly results rather than causes of the disease. *March 16th*, 1880.

---

3. *Case of cystic degeneration of the kidneys.*

By Frederic S. Eve.

William S—, a fairly-nourished man, æt. 47, was admitted into St. Bartholomew's Hospital July 3rd, 1879. He stated that a week ago his urine became bloody, but he had previously had no symptoms of renal disease. Three days ago he had epistaxis. For the last week he had been subject to cramps in the fingers and abdominal muscles.

Last Christmas he had bronchitis, due to getting wet, otherwise has had no serious illness.

On admission.—There was considerable dyspnœa; the skin was cold and clammy; the urine was acid, pale, sp. gr. 1010, and contained albumen—about two thirds.

July 4th.—He was very restless. Passed little urine. Petechiæ were noticed on the chest and abdomen. Pulse 72; temp. 97° (Fahr.); resp. 20.

The following day uræmic coma developed itself, and he died some hours later.

Autopsy.—There was no anasarca. The left ventricle was

hypertrophied. The arteries generally were atheromatous. A cavity, about 1 inch long and $\frac{1}{8}$th to $\frac{1}{12}$th inch broad, was found in the outer part of the right corpus striatum; it contained a little reddish fluid, and was surrounded by a small circumferential tract of softened brain tissue. Both kidneys were well-marked examples of cystic degeneration. They were about 7½ inches long, 4 inches broad, and weighed respectively 21½ and 20 oz.; their surfaces were irregularly lobulated from the projection of cysts of various sizes. The pelves were much dilated and the calyces elongated, extending nearly to the surface of the organ. The parenchyma of the organs was converted into congeries of cysts, varying from the size of a walnut to that of a pea, enclosed in a matrix of very vascular connective tissue. The cysts contained a dirty-brown fluid, having the odour and appearance of decomposing urine. No trace of the normal structure of the kidney was visible to the naked eye. An attempt was made to inject the tubuli uriniferi, but although some of the tubes ramifying on the walls of cysts were filled, yet the injection was nowhere found to have entered a cyst. The ureters were neither dilated, nor did they appear anywhere constricted.

Microscopic examination.—Portions for microscopic examination were taken from the interstices of the cysts and periphery of the organs.

Considering the gross nature of the macroscopic changes, the evidence of renal elements which microscopic examination revealed was surprising.

A marked feature was the great increase of the interstitial tissue, some sections consisting entirely of coarse connective tissue containing compressed tubuli and glomeruli.

Other sections consisted entirely of unequally dilated and tortuous tubes, for the most part denuded of epithelium, but occasionally traces of epithelium were observed in largely dilated tubes; a few contained granular matter, and very rarely a dilated tube was found blocked with nuclei and granular material, apparently of epithelial origin.

Stages of transition from simple dilatation of the tubuli to the formation of cyst-like cavities could be so plainly observed as to leave little or no doubt that the cyst development took place from the tubuli uriniferi, although the disease was far too advanced to permit of any conjecture as to the cause of the retention.

The minute cysts nowhere possessed a lining of tessellated epithelium, as has sometimes been observed. In no case could a glomerulus be traced in process of transition into a cyst, but it was observed that the glomeruli were not perceptibly altered in sections, showing a distinct dilatation of the immediately adjacent tubes. No indication of the formation of cysts in the connective tissue could be obtained.

The changes described agree in the main with the observations already placed on record.

Förster[1] states that the smallest cysts are developed as dilatations of tubuli or of Malpighian bodies, and the larger by amalgamation of the smaller ones. He also thinks they may be formed in the connective tissue, or by the metamorphosis into colloid masses of the epithelium in some portions of the tubuli.

Virchow's[2] observations, that crystalline urinary bodies are frequently found in the cysts as well as sero-albumen, points to their origin from the renal tubuli, and, as he remarks, serves to distinguish them from the cyst formations of granular atrophy.

Mr. Conway Evans'[3] observations on a case in an early stage of the disease led also to the conclusion that the cysts were formed by expansion of sections of the uriniferous tubes.

I am indebted to Dr. Southey, under whose care the case was, for permission to bring it forward. Dr. Southey has also been good enough to revise my description of the microscopic appearances, and gave me access to the manuscript of his forthcoming work on 'Diseases of the Kidney,' from which the above references were taken. *May* 18*th*, 1880.

[1] Förster, 'Path. Anatomie,' p. 468, 1873.
[2] Virchow, 'Gesammelte Abhandlungen,' p. 874.
[3] 'Path. Soc. Trans.,' vol. v, p. 183.

4. *Cystic kidney removed from a child.*

By W. H. Day, M.D., and J. Knowsley Thornton, M.B., C.M.

This cystic kidney was removed by abdominal section from a little girl, æt 7, at the Samaritan Hospital, on January 3rd, 1880.

It will be seen that the anterior portion is the dilated pelvis, and the sausage-shaped portion the dilated kidney spread out behind the dilated pelvis. For so large a cystic kidney the predominance of the dilated glandular portion over the dilated pelvis is unusual.

The ureter is altogether absent or represented by this small fibrous cord, which was traced down on to the bladder at the time of operation.

Traces of the pyramids and cortical portion remain in the posterior part of the cyst, and numerous partial septa, the remains of the calyces, may be seen projecting into the dilated pelvis.

The diameter of the cyst when moderately distended is eight and a half inches.

When tapped some weeks before removal, the cyst contained six and a half pints of brownish and rather thick urine, slightly albuminous. About the same quantity of similar fluid was again removed at the operation on January 3rd, but it was thrown away by mistake during the progress of the operation.

The history of the case is imperfect, owing to the early death of the child's mother, but she is known to have had a tumour in the abdomen since she was two years old, and it seems probable the impervious ureter was a congenital defect.[1] *January 6th*, 1880.

[1] The patient made a rapid recovery and has grown considerably, and is in much improved health, six months after the operation. The specimen is preserved in the Museum of the College of Surgeons. Full clinical details of the case will be found in the 'Lancet,' June 5th, 1880.

5. *Three cases of sarcomatous growths invading both kidneys from without.*

By JOHN ABERCROMBIE, M.D.

MALIGNANT disease of the kidney in childhood is not a very unusual occurrence, but a symmetrical affection of both kidneys is, I believe, very rare, and will, I hope, justify my bringing these cases before the notice of the Society. The cases all occurred at the Hospital for Sick Children, Great Ormond Street, and I am indebted to Dr. Cheadle for his permission to bring them forward to-night.

CASE 1.—Alfred D—, æt. 3 years and 3 months, was admitted into the Hospital for Sick Children, under Dr. Cheadle, on April 8th, 1879.

The following history was obtained from the mother:—His abdomen has always been rather big, but more especially so the last twelve months. Cut his teeth early. Has never been able to walk. Takes his food well; no vomiting; bowels regular. Always thin; is not losing flesh. He is the eldest child; one other died aged six months. Parents healthy; no phthisis on either side. They live off the City Road now, formerly they lived in the New North Road; soil not known to be damp.

State on admission.—Very anæmic. Tongue clean. Superficial glands in neck and groins enlarged. Heart's impulse beats in the fifth space, nipple line; no thrill; no increased dulness; systolic murmur at apex, audible all over præcordium. Chest otherwise natural.

In the abdomen there is a firm tumour on the left side, extending downwards and forwards from the left hypochondrium to beyond the umbilicus, and then sloping away to the left iliac fossa; the edge is very sharp. Liver felt two inches below margin of ribs. Urine contains a trace of albumen.

Blood, examined under the microscope, shows a diminution of corpuscles, especially white.

April 19th.—Temperature has been up the last two days. Temp. 103° last night. The cachexia is more marked. No increase of heart dulness; systolic and presystolic murmurs at apex.

22nd.—Restless night. Breathing becoming more laboured. Abdomen more swollen. Legs and feet swollen, and pit a little. 2.15 p.m., died.

Autopsy 24½ *hours after death.*—Body not well nourished; weight 21 lbs. Rigor mortis present.

Thorax.—Slight recent adhesions over right lung; a little fluid in each pleura. Pericardium natural. Right auricle and ventricle dilated and distended with blood. Left ventricle hypertrophied. Mitral valve shows old granulations along its free margins, and also recent endocarditis, as evidenced by soft vegetations and redness. Heart weighs 3¼ oz. Lungs natural. Bronchial glands a little enlarged.

Abdomen.—A little clear fluid in peritoneal cavity. Some recent perihepatitis over upper surface of liver, causing adhesions to diaphragm. On section, liver structure appears natural. Spleen immensely enlarged and very firm; capsule thickened in places; no marked naked-eye changes; anterior margin sharp; weight, 15¾ oz. Alimentary canal natural; pancreas natural; mesenteric glands a little enlarged. Prævertebral glands slightly enlarged; one just beneath hilus of left kidney considerably so, and quite soft; on section a purplish juice exudes.

Right kidney.—Capsule strips off easily; surface smooth; on section, kidney pale throughout, cortex increased in depth, and structure confused; pelvis much larger than usual, and presents everywhere a purple tint; lining membrane quite smooth. This purple colour is due to the presence of a new growth, which is pushing its way into the kidney at the hilus, but has not as yet actually invaded its structure anywhere. Weight 3¾ oz.

Left kidney.—Capsule peels off easily; on surface are seen two rounded projections, each about the size of a shilling, and other smaller similar ones where the kidney is dotted over with soft yellowish-white material, looking at first sight very like secondary tuberculosis. On section, quite half the pelvis shows the same appearance as has been described in the right, but in addition, in several places, running along the pyramids, are seen streaky deposits of the soft whitish material, apparently following the course of the blood-vessels. Weight 4 oz.

There is no connection between the growths in the two kidneys, and they do not form any external tumour. Supra-renal bodies natural. Bladder and ureters natural.

CASE 2.—Eunice H—, æt. 2, was admitted into the Hospital for Sick Children, under Dr. Cheadle, October 9th, 1879.

The following history was obtained from the mother :—Stomach has been big for eleven months. Has being losing flesh ; appetite poor ; vomits everything she takes. Bowels always much confined. Not weaned yet. One other child healthy. Two died, aged two months and five months respectively. Mother healthy ; no phthisis in her family. Father, aged twenty-eight, has had diabetes mellitus, but is better now.

On admission.—Ill-nourished. Profoundly anæmic, of a somewhat earthy hue. Has central and lateral incisors in both jaws only. Glands in neck slightly enlarged. Anterior fontanelle rather widely open. Chest natural to percussion and auscultation. Abdomen decidedly big ; on left side a firm mass, with a tolerably sharp anterior edge, can be felt coming down from left hypochondrium towards umbilicus ; from this point it slopes downwards and backwards to left iliac fossa. A notch can be felt about one inch below umbilicus. Liver palpable, three fingers' breadth.

October 13th.—At first temperature varied from 101° to 102°, but the last two mornings 99° and 99·6°. Some impaired resonance at right anterior and axillary bases, respiratory murmur weak here. Posteriorly no dulness ; a little occasional râle over right lower base. Has had some diarrhœa, but that is better now. Hands and feet swollen, and pit on pressure. Urine could not be obtained.

15th, 4·30 a.m.—Died.

Examination of body twelve hours after death. Not well nourished. Rigor mortis present. Pitting on dorsum of feet.

Thorax.—A little serum in right pleural cavity. Right lung shows patches of collapse in all three lobes, and some patches of lobular pneumonia in the lower lobe ; weighs 4¾ oz. Left lung shows slight partial collapse ; weighs 4 oz. Heart and pericardium natural. Heart weighs 2¼ oz.

Abdomen.—A little clear serum in abdominal cavity. Liver enlarged, reaching down to level of umbilicus, pale, firm ; on section natural ; weighs 1 lb. 4 oz. Spleen much enlarged, reaching quite down to iliac fossa ; it presents several notches, one especially deep, about an inch and a half from the top ; a little perisplenitis in places ; on section very firm ; weighs 8¼ oz. Supra-renal bodies natural. Pancreas natural. Kidneys much enlarged ; capsules strip off readily ; surface smooth, very pale, but mottled irregularly with pink patches,

about the size of a threepenny piece. On section the kidney is pale; cortex very deep; several patches are seen formed of groups of red radiating lines starting from the pelvis and going to the surface, where they betray their presence, as above indicated. The lining membrane of the pelvis looks deep red, owing to the presence outside it, in the hilus of the kidney, of a softish, deep red growth. Both kidneys are very much alike; the growth in one has no connection with that in the other; weighs 6¼ oz. A retroperitoneal gland on each side level with the vessels of the kidney is enlarged, soft, and of a deep reddish-purple colour. Alimentary canal natural.

CASE 3.—Louisa D—, æt. 4, admitted into the Hospital for Sick Children, under Dr. Cheadle, October 21st, 1879.

The following account was given by the mother:—Never a strong child, but failing more since two years old. Has always had a big stomach since three months old. Much worse the last three weeks; anorexia, pallor; bowels rather relaxed; no vomiting; rapid emaciation. Often small purple spots come out about her body. Gums occasionally get sore and bleed; no hæmorrhages from intestines or bladder.

The fourth child, born at the full time, seemed well up to three months old, then stomach began to swell; no snuffles. Weaned æt. sixteen months. Has had no infectious complaints.

Five others healthy; no bleeding; none dead; no miscarriages. Parents healthy; no phthisis on either side. Has always lived in Holborn; house considered healthy.

On admission.—Ill-nourished. Extreme pallor with marked cachexia. Large thick scab on back of head. Glands in neck enlarged on both sides. Anterior fontanelle not closed. A small fluctuating swelling in occipital region. Tongue moist, clean, very pale. Slight transverse constriction of chest; ribs a little beaded; no signs in front; behind some sharp râles over left back, no dulness. Abdomen very large, soft; a firm tumour can be felt coming down from left hypochondrium towards umbilicus, at this level, and about 1½ inches from the middle line, it bends sharply back towards the left iliac fossa; the surface is smooth, edge sharp, it moves with the diaphragm. Liver palpable, about three fingers' breadth; feet a little swollen. Urine no albumen. Blood is very pale and watery, but certainly no increase of white corpuscles.

November 2nd.—There has been a good deal of fever since admission, but less now. Gums bleed very readily. Loud systolic

murmur at left base, audible at apex. Spleen does not come down quite so low as it did.

20th.—The fever continues, but temperature decidedly irregular. Heart dulness to right margin of sternum and upper part of second left interspace; systolic murmur heard loudly over both front and back, louder at base. Has had some diarrhœa lately.

23rd.—Had some epistaxis this morning. Some purpuric spots on chest. Breathing much laboured to-day. Much diarrhœa lately; motions slimy, and contain some blood.

24th, 9.15 a.m.—Died.

Examination of body seven and three quarter hours after death.—Body thin, weighs 14½ lbs. Rigor mortis slight. Anterior fontanelle widely open. Brain not examined.

Thorax.—Some recent adhesions at base of left pleura. Both lungs full of frothy mucus; partial collapse and emphysema of upper lobe of right lung: middle lobe collapsed. Right lung weighs 4¾ oz.; left lung 4 oz. Pericardium natural. Right side of heart much dilated, and contains black clotted blood; mitral valve shows two small opaque granulations on its lesser flap. Heart weighs 2½ oz. Trachea and bronchi reddened. Bronchial glands soft, mostly about the size of a pea.

Abdomen.—Liver about one finger's breadth, and spleen four fingers' breadth, below margin of ribs. Stomach shows some small ecchymoses in its mucous membrane. Mucous membrane of small intestine reddened in places. Large intestine shows unusual prominence of the solitary glands. Pancreas and supra-renal bodies natural. Liver flabby, peritoneum on its upper surface rather firmly adherent, weighs 13½ lbs. Spleen very firm and much enlarged, thickening of capsule in places; no iodine staining; weighs 7 oz. One small splenculus near hilus. Both kidneys large, surface smooth; on section, cortex not increased in depth, not pale, not confused; when laid open the whole pelvis presents a deep purple appearance, owing to the presence of a soft purplish mass at the hilus of the kidney; the lining membrane of the pelvis is everywhere quite smooth. The mass in the hilus when viewed from the outside is flattened, about a quarter of an inch thick, and rounded towards the spine. The condition is exactly similar in each kidney; the growth in the one is quite distinct from that in the other; opposite the hilus of the left kidney is a prævertebral gland about three qnarters of an inch long by a quarter across, soft and purple; the

corresponding gland on the right side is about one third of this size and natural. Mesenteric glands enlarged, some of them caseous.

Microscopical examination of the extra-pelvic growth in Case 3 shows that it is mainly composed of a loose connective tissue, with masses of small round cells interspersed in its meshes; these are most abundant around the blood-vessels. In places where the round cells are less numerous there is a good deal of extravasated blood. In Cases 1 and 2 the growth is of similar structure, but more largely composed of round cells. The secondary deposits in these two cases consist of masses of round cells, the deposit of which is very extensive in Case 2. In these two cases, too, there is a certain amount of parenchymatous nephritis, as shown by the presence of blood-corpuscles in the tubules, and proliferation of their epithelial lining. The spleen in each case shows a simple hypertrophy of its normal constituent elements.

The coincidence of enlargement of the spleen in all the cases would raise the question of lymphadenoma, but to the naked eye these spleens presented no abnormal appearance, and on microscopical examination the Malpighian corpuscles were certainly not increased in size.

There was no enlargement of the lymphatic glands beyond an increase in size of the gland opposite the hilus of the kidney in each case. Moreover the blood (which was examined in two of the cases) showed no increase of white corpuscles. I am, therefore, unable to say what was the relation, if any, in these cases between the renal growths and the splenic enlargement, but their coexistence is very remarkable.

If the growth had been confined to one kidney, it might have been justifiable to surmise that this was the earliest stage of the ordinary form of malignant disease in childhood, but primary malignant disease of both kidneys is exceedingly rare, and it would be mere conjecture to say what would have become of these kidneys had the patients lived longer.

The only case that I have been able to find bearing on this point is the following:

Rayer[1] quotes from Rance (Bibl. Méd., t. xlvii, p. 124) the case of a little girl, æt. 1 year and 7 months, who was the subject of fungus hæmatodes of both kidneys. During life there was a painful tumour in each hypochondriac region. At the autopsy the tumour

[1] 'Mal. des Reins,' t. iii, p. 717.

on the right side was firmly adherent to the cæcum; on cutting into it there escaped a substance of the appearance and consistence of marrow; it was so soft that it could not be dissected. The left tumour was larger than the right, it was attached to the tumour on the right side, to the mesentery, mesocolon, and renal glands; no trace of kidney structure could be recognised.

Walshe[1] says, "Cancerous vegetations of fringed, cauliflower or flattened aspect spring from the submucous tissue of the pelvis free from all connection with any coexisting renal cancer," but he does not quote any cases.

Practically, there were no clinical symptoms by which this renal affection could have been recognised during life.

In the first case a trace of albumen was found, and in the second case its presence was suspected from the general anasarca, but no urine could be obtained; in both these cases there was parenchymatous nephritis, which may very possibly have been set up by the secondary deposits. In the third case there was no albuminuria, and no parenchymatous nephritis.

I may add that the cause of the enlargement of the spleen in these cases remains obscure; in none of them could it be attributed to syphilitic taint or malarial poisoning.[2] *May* 18*th*, 1880.

---

6. *Papilloma of the Fallopian tube, associated with ascites and pleuritic effusion.*

By Alban Doran.

(With Plate VIII.)

This specimen illustrates a form of new growth rare in the Fallopian tube, and associated with an open condition of its fimbriated extremity, usually closed when the tube is dilated or otherwise diseased. It was successfully removed from a single lady by Mr. T. Spencer Wells, by whom it has been presented to the Museum of the Royal College of Surgeons.[3]

In October, 1877, the patient, aged 50, a maiden lady, thin and

[1] 'On the Nature of Cancer,' p. 395.

[2] These specimens were referred to the Morbid Growths Committee, but as they were exhibited at the last meeting of the session, the report of the Committee could not be presented to the Society till the next session.

[3] 'Path.,' Series 2652A.

DESCRIPTION OF PLATE VIII.

This Plate illustrates Mr. Alban Doran's Case of Papilloma of the Fallopian Tube. (Page 174.)

Figs. 1 to 4.—Microscopical appearances of different portions of the growth. From drawings by himself.

FIG. 1.—Section of a papillary outgrowth:—*a*. Secondary papilla. *b*. Cystic cavity, formed by a coalescence of overhanging outgrowths. Two vessels are seen in the root of the growth. Camera × 40.

FIG. 2.—The papilla, *a*, Fig. 1. The cells of the stroma near its apex resemble cartilage-cells, those near the base are of the connective-tissue type. There is a hyaline matrix between these cells and the epithelium. Camera × 400.

FIG. 3.—Section of a cyst found among the papillary growths. Secondary growths spring from its inner walls; these involve smaller cysts. × 6.

FIG. 4.—A cystic cavity from the secondary growth, *a*, Fig. 3. It is lined with a single layer of columnar epithelium, which has not invaded the surrounding connective tissue. Camera × 400.

Fig. 5.—The Fallopian tube laid open, to show the growth. From a drawing by Mr. Sherwin.

a. Aperture of undilated part of tube. *b*. Fimbriated extremity of tube, into which a bristle is inserted, passing across the growth into the proximal part of the tube at *a*. *c*. Ovary. *d*. Small pedunculated cyst. *e*. Cyst springing from among the papillomatous growths.

Fig. 1.

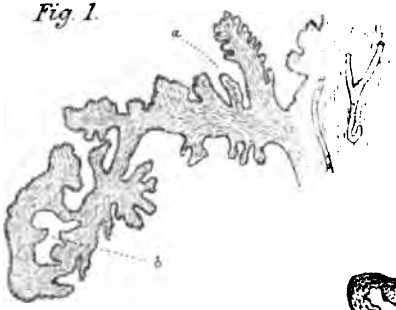

Fig. 2.

Fig. 3.

Fig. 4.

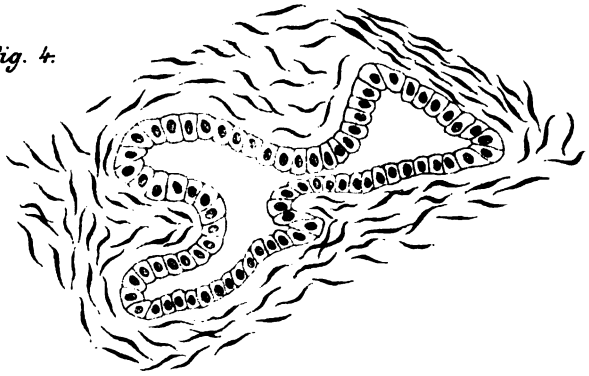

Fig. 5.

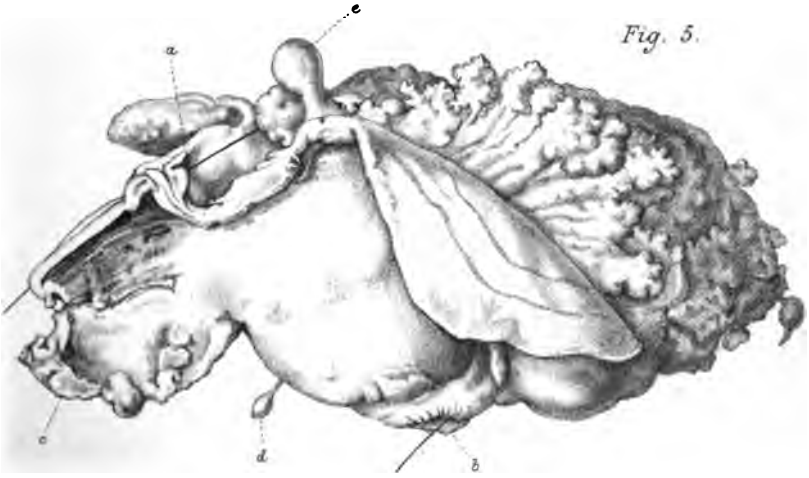

emaciated, came under the care of Mr. Bickersteth, of Liverpool. It was then a month after she had experienced a severe attack of menorrhagia following amenorrhœa, which had lasted several months. There were now symptoms attributed to inflammation of the right ovary and surrounding cellular tissue. The local pain was severe, and there was vomiting, constipation, difficulty in micturition, general tumefaction of the abdomen, and high fever. She recovered perfectly after remaining in bed for six weeks. But in March, 1878, she had an attack of pleural effusion on the right side. One hundred and twenty ounces of clear fluid were removed by tapping; then the abdomen began to swell, and on July 30th paracentesis was performed, and nine pints of fluid were drawn off; thirteen pints more had to be removed in September. In October the right pleura again required tapping, by which means 100 ounces of fluid were removed. In January, 1879, the abdomen having again become swollen, sixteen pints were drawn off by the trocar and canula. Ever since the subsidence of the symptoms of pelvic inflammation, throughout the period of recurrent pleural and peritoneal effusion, there had been neither acute disturbance of the system, nor even so little as the solitary objective symptom of rise of temperature; and after each tapping recovery appeared to be for a time complete, nor was there any evidence of cardiac or hepatic disease.

In March, 1879, two months after the third tapping of the abdomen, the patient was referred to Mr. Wells for consultation, as the nature of the abdominal lesion remained very uncertain. During the first enlargement of the abdomen, Mr. Bickersteth detected a clear percussion note persistently in front of the abdomen, and a dull note in both flanks, most marked on the right side, slowly and slightly altered by change of position. Mr. Wells recommended an exploratory incision, to which the patient at first objected, so the abdomen was simply tapped. Dr. Caton examined the fluid, which amounted to twenty-two pints. Its specific gravity was 1022, and it coagulated almost entirely under the action of heat and nitric acid. Its scanty flocculent deposit was found to consist of large cells, mostly grouped in clusters, and apparently proliferating; many were distinctly vacuolated. Mr. Knowsley Thornton, who examined microscopically the fluid removed during the subsequent operation, found and kindly showed me similar cells.

Mr. Wells, on examining the patient shortly after the final tapping, detected a hard, nodular mass behind the uterus, which

organ was freely movable, and so low in the pelvis that the cervix lay close to the vulva. Dr. W. H. Day, at the same time, examined the thorax, and found evidence of the presence of a small quantity of fluid in the right pleural cavity, without any sign of disease of the lungs themselves. On account of the tendency to pleural effusion he considered an operation imperative. Clusters of proliferating cells had been found in the pleural as well as in the peritoneal fluid.

On April 28th, 1879, Mr. Wells operated on the patient, employing strict antiseptic precautions. When the peritoneal cavity was laid open by the usual incision through the linea alba, seventeen pints of amber-coloured, opalescent fluid escaped. The left ovary was normal; to the right of the uterus, which was of the usual dimensions, a tumour was found, the size of a large orange, and consisting of the greater part of the right Fallopian tube; the ovary could be distinctly felt behind it. The tube and ovarian ligament behind the growth were secured by silk ligatures, and the tumour, with the ovary, which could not be separated from it, were cut away. The peritoneum was carefully examined for secondary deposits, but none could be found. The patient made a very rapid recovery, and is now in good health.[1]

On laying the tumour open it was found to be filled with cauliflower excrescences, covered with a mucoid secretion, which issued from the open fimbriated extremity. It may now be seen that about an inch of the innermost portion of the tube remains undilated and quite pervious (fig. 5, *a*). The remainder forms an elongated, oval tumour, three and a half inches long, two inches in vertical measurement, and over two in thickness antero-posteriorly. Its upper, anterior, and posterior surfaces are uniformly smooth and white. On the inferior aspect the abdominal orifice is plainly visible (fig. 5, *b*); it readily admits a stout bristle, which enters directly into the cavity of the tube. The fimbriæ, although thickened and shortened, remain quite distinct. One inch internal to the

[1] Mr. Bickersteth has kindly informed me that she had an attack of pleurisy in August, 1879, in September there remained "dulness and deficient respiration, with feeble sounds over the right side of the chest, indicating thickening of the pleura from recent inflammation (a few weeks before, Dr. Cameron detected friction-sounds over the same side)." There appeared to be no evidence of effusion or thoracic tumour. [Since September, 1879, there has been no relapse of any kind, and the patient is now in perfect health. A. D., Sept., 1880.]

orifice is a small pedunculated cystic body (*d*), which, from its position, is probably the "hydatid" believed to represent the extremity of Müller's duct. But I have observed similar growths in numbers on the surface of dilated Fallopian tubes, far from the fimbriæ. The ovary (*c*) is an inch and a half long, and somewhat flattened. Its outer portion adheres to the tube, and contains three menstrual corpora lutea, one apparently quite recent.[1] No cystic nor papillary bodies could be found within the ovary, but a small, transparent, thin-walled cyst projects from its surface. The broad ligament between the ovary and the undilated portion of the tube is much thickened, but contains no new growths.

The cauliflower excrescences may be seen to grow from all parts of the mucous membrane of the dilated portion of the tube. Several cysts with smooth exteriors and thin walls (*e*) rise by narrow pedicles from amidst the excrescences, and contain papillary outgrowths (fig. 3); other cysts have their walls roughened externally by similar new formations, also springing from their interiors.

On microscopical examination the cauliflower growths may be seen to be covered with countless secondary offshoots. On account of the nature of the morbid structure it was hard to make good sections; the specimens shown this evening were made mostly by myself, but one most perfect section was prepared by Mr. R. W. Parker. The free surfaces of the growths are invested throughout with a single layer of columnar epithelium; some, but only few, of the cells in this layer are ciliated. The stroma is almost universally made up of small fusiform connective-tissue cells, and is but poorly supplied with blood-vessels. In one secondary papilla (fig. 2, fig. 1, *a*) the cells of the stroma towards the extremity resemble cartilage cells, those at the base remaining small and spindle-shaped. A wide border of perfectly hyaline matrix separates these cells from the epithelium. This form of incipient chondrification I have very frequently observed in similar growths found in the interior of ovarian cysts. The deeper portions of this growth, contrary to the general rule when cartilage-cells are found near the surface, exhibit no trace of chondrification. The cysts owe their origin, at least partially, to coalescence of the extremities of masses of free papillæ. At *b*, fig. 1, a cyst is seen in process of formation, precisely as observed in certain

[1] During her illness the patient menstruated four times, at irregular intervals. The last period was about six or eight weeks before operation; the catamenia have never reappeared since the tumour was removed.

ovarian growths by Dr. Wilson Fox. In the intra-cystic growths (fig. 3. *a*) the stroma contains fusiform cells larger than those in the free papillæ, and in parts mucoid tissue, but nowhere cartilage cells. On the surface of these growths cyst-formation is going on, the cysts arising by the same process as that to which their parents owed their orgin. In fig. 4 a large cyst occupies the stroma of the growth *a*, fig. 3.

The absolute limitation of the epithelium to free surfaces in this specimen is sufficient to show that the growth is not cancerous. That the cells found free in the fluid by Dr. Caton and Mr. Thornton were derived from the epithelium, there can be little doubt; that these free bodies might infect the peritoneum is also highly probable, but Mr. Wells failed to find any secondary growths on the contents of the abdominal cavity which came within his reach during the operation. The subject of this method of infection and of allied processes of dissemination of morbid material from ovarian tumours has already been discussed before the Pathological Society.[1]

If these excrescences or outgrowths are to be looked upon as constituting a tumour it would rather be a papilloma than a glandular growth. For while papillæ may form as new growths where no papillæ are normally found, no glands exist in the mucous membrane of the Fallopian tube,[2] and glandular tumours do not occur away from glanudar structures, although I am quite aware that the newest school of pathology insists on the adenoid nature of certain tumours found on the simplest mucous surfaces. But this theory applies to growths which are absolutely and essentially true tumours, whilst these "papillomata," as I will presently endeavour to explain, are in some respects associated with the phenomena of inflammation. Rokitansky states that new growths developed from minute papillæ seen on the mucous membranes of diseased Fallopian tubes are rare, and seldom exceed the size of a pea or a bean.[3] Hennig has found that hyperplasia of the tubal mucous membrane passes into polypoid growth through the successive stages of warty and papillary tumours, these transitional forms being

[1] Goodhart, vol. xxv, pp. 197—9; Thornton, vol. xxviii, p. 192.

[2] Stricker, 'Manual of Histology,' vol. iii, Syd. Soc. Trans. Hennig alone believes in the existence of tubular glands in the human Fallopian tubes. See Klein and Noble Smith, 'Atlas of Histology,' p. 294.

[3] 'Lehrbuch,' vol. iii, p. 442.

often found side by side in dropsical tubes.[1] In a case of stricture of the tube by a band of lymph, this author found a warty outgrowth, one centimètre broad, close to the seat of constriction, which growth he considered to be the result of chronic catarrh. The specimen now exhibited before the Society is evidently an unusually large example of the outgrowth recognised by Rokitansky and Hennig. The excrescences are, perhaps, not so much tumours as hyperplasiæ produced by chronic inflammation. They closely resemble the condylomata around the labia in venereal patients, especially frequent in cases where the external parts are irritated by copious and chronic discharges, or by want of cleanliness. Dropsy of the Fallopian tubes is nearly always preceded by catarrh of the mucous membrane. This case began by symptoms attributed to inflammation of the right ovary, that is to say, the tube in reality was inflamed. The discharge of secretion through the abdominal aperture irritated the peritoneum and produced ascites, for the abundance of the fluid, removed by tapping, shows that the peritoneal cavity was filled chiefly by its own secretion, and not by that thrown off from the growths in the tube. As regards the condition of the peritoneum this case resembles another described by Gusserow and Eberth,[2] where ascites followed symptoms of inflammation of the ovaries. After the patient's death from strangulated umbilical hernia, the surfaces of both ovaries were found covered with large cauliflower excrescences. Similar cases have been observed by Wells and Durham.

The open condition of the fimbriated extremity of the Fallopian tube is a very unusual feature; indeed, Cruveilhier states that in dropsical distension, obliteration of that extremity is constant.[3] The continuous flow of free mucous discharge from the earliest stage of disease probably accounts for the patency of the abdominal aperture in this case. Had the discharge been scantier and intermittent, the fimbriæ might have adhered to each other and sealed up the tube, then the tumour would have attained a great size, but ascites would less probably have supervened, since no discharge could escape into the peritoneum so as to irritate that serous membrane, and spread a morbid influence as far as to the right pleura. *October* 21*st*, 1879.

[1] 'Die Krankheiten der Eileiter und die Tubenschwangerschaft,' Stuttgart, 1876.

[2] 'Virchow's Archiv,' pt, iv, vol. iii, p. 14 (1868).

[3] 'Traité d'Anat. Path. Gén..' vol. iii, p, 371.

7. *Ovarian cyst which had ruptured repeatedly during a period of nine years prior to its removal.*

By W. A. Meredith, M.B.

This specimen was removed from a patient in the Samaritan Hospital, by my colleague, Mr. Knowsley Thornton, to whose kindness I am indebted for the opportunity of showing it.

A single woman, æt. 47, first noticed some abdominal enlargement about ten years ago; an ovarian tumour was diagnosed, and she was tapped in August, 1871, when about twenty pints of fluid were drawn off. The cyst soon began to refill, and in three or four months' time the patient was as large as before. After suffering a sharp attack of pain near the seat of the tapping puncture, she noticed one day a sudden alteration in the shape of the tumour, and, within twenty-four hours, began passing large quantities of clear urine. This state of diuresis persisted for four or five days, at the end of which time all trace of the abdominal swelling had disappeared.

From that date (Dec., 1871), this refilling of the cyst, followed by spontaneous rupture thereof and complete removal of the effused fluid by diuresis, has recurred with remarkable regularity three or four times in the course of each year, until last April, when the patient was tapped by her doctor in the country, who drew off "a pailful of clear fluid."

Between April and October the cyst has twice refilled and ruptured.

When first seen, towards the end of last September, no abdominal tumour was to be detected, and the patient was advised to return to the hospital in two months' time.

On her readmission (Nov. 28th), the abdomen was found to be uniformly distended by a tense, distinctly fluctuant tumour, the girth at the umbilical level being thirty-seven inches.

Ovariotomy was performed on Dec. 4th. The only adhesions present were a few filamentous bands about the site of the recent tapping puncture; the peritoneum was quite healthy in appearance, and its cavity did not contain any free fluid. The tumour, of

which the fluid contents measured twenty-one pints, had originated on the left side. The right ovary was healthy.

The specimen shows one large cyst cavity with a group of small secondary cysts growing on its inner wall; the remains of the ovary, together with the adherent Fallopian tube, are seen on its outer surface. The cyst-wall, tolerably thick and fleshy in the immediate neighbourhood of the pedicle, is elsewhere remarkably thin and non-vascular; it is traversed by numerous intersecting fibrous bands, the interspaces between which are commonly quite translucent. The lining membrane shows no trace of papilloma.

On the inner surface of the cyst-wall are seen numerous examples of so-called "ulcerations," in various stages of progress or of repair. The most advanced of these vary in size from that of a shilling to a florin, with ragged borders shewing the different layers destroyed in varying degree; in several places, where perforation would evidently very shortly have occurred, the base or centre of the ulcer consists of the external serous coat alone. At other points, where reparative changes have apparently taken place, irregular patches of white, dense, cicatricial tissue are found.

Scattered about the cyst-wall are numerous irregularly-shaped patches of tawny discoloration, with abruptly defined borders; these areas, which in several instances are somewhat wedge-shaped, usually occupy the intervals between the larger vessels supplying the cyst-wall, and apparently partake of the nature of infarcts. Microscopical examination shows the tissues laden with fatty and granular materials evidently due to atheromatous degeneration; and changes of a like nature are also seen in sections made through the ulcerating patches.

There are, I think, several points of interest connected with this specimen.

It affords an explanation of one of the ways in which spontaneous perforation may occur in true ovarian monocysts, and enables us further to trace the steps of the process, which are probably as follows:—Deficient vascularity of the cyst-wall, consequent upon prolonged or (as in the present case) repeated distension, finally induces obliteration of vessels, with consequent fatty degenerative changes in the tissues; as the distension increases the lining membrane gives way at some one point, the softened tissues readily break down, and finally, a slit-like aperture is made in the outermost serous layer of the cyst-wall, through which the fluid

freely escapes into the abdominal cavity. A knowledge of the extreme rapidity with which plastic changes occur in connection with the peritoneum enables us to understand how the rent becomes closed as the cyst collapses.

It is probable that rupture of intervening septa between the adjacent cavities of multilocular ovarian cysts may take place by means of a somewhat similar process of atrophy; with or without the accompanying atheromatous changes here noticed.

The absence of any important cyst-adhesions, notwithstanding the very frequent recurrence of the effusion into the peritoneal cavity, is to be explained by the unirritating properties of the cyst-contents, the nature of which is further evidenced by the absence of symptoms of peritoneal irritation at the times when the ruptures occurred; the patient, during all these years was never once incapacitated for a single day for the performance of her ordinary duties as a housemaid.

The case is also of interest as showing what an enormous amount of ovarian fluid the peritoneum is capable of absorbing without being in any way altered. Rupture of the cyst occurred no less than thirty-four times during the nine years; and, on each occasion, the quantity of fluid which escaped into the peritoneal cavity cannot have been much under twenty pints; hence the total amount absorbed must have been very considerable.

December 16*th*, 1879.

---

8. *Mixed calculus of cystine and oxalate of lime.*

By Samuel G. Shattock.

The calculus weighs 260 grains, and is of an irregularly-oval form, an inch and five eighths in its chief diameter, and of a pale, transparent, yellow colour; it surface is rugged and crystalline.

On both of its sides it is considerably hollowed, and on one side there appear, in the bottom of the depression, a series of reddish-brown areas, such as might be presented by a calculus of oxalate of lime. The section of the calculus shows it to be throughout of a

compact crystalline structure, concentrically subdivided a short way beneath the surface by a narrow, wavy zone of harder, dull-brown substance.

The analytical report by Mr. Taylor is as follows:—"The central and outer portion of the calculus consists of nearly pure cystine—the thin, dark-coloured layer which intervenes, of oxalate of lime. The entire calculus contains a minute proportion of oxalate of lime, which is in somewhat larger amount towards the centre."

The calculus was removed at the West Herts Infirmary by Mr. Steele, who has furnished the following notes of the case:

The patient was 19 years of age, of dark complexion, and strongly built.

The great-grandfather, on the father's side, had died of stone in the bladder.

The parents of the patient are healthy; he has a younger sister who suffers from pain in the back and other obscure symptoms.

There is no family history of gout.

The patient was treated for a small vesical calculus when 9 years of age. After this he several times extracted calculi from his urethra.

In February, 1880, he was admitted into the West Herts Infirmary with the symptoms of stone in the bladder, for which he was sounded, and successfully cut.

The condition of the urine was as follows:—Specific gravity 1018, slightly acid, speedily becoming alkaline, greenish yellow, and oily-looking.

The excessive addition of acetic acid threw down a crystalline deposit, which the microscope showed to consist of hexagonal plates of cystine; octahedral crystals of oxalate of lime were also present in the urine. The urine of the parents was examined, but no trace of cystine was detected.

One half of this specimen is in the collection of the Royal College of Surgeons of England. *May 4th* 1880.

9. *Calculus removed by supra-pubic lithotomy.*

By Paul Swain.

This specimen, represented by the Woodcut, was removed by Mr. Paul Swain from the bladder of a child, æt. 10, by the supra-pubic operation. She was admitted into the Royal Albert Hospital, Devenport, on July 21st, 1879. Her symptoms were first noticed

Woodcut 1.

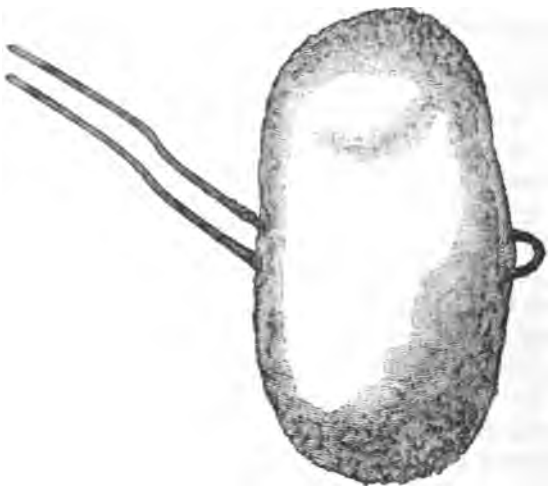

fifteen months before admission. She had been in the habit of passing a hair-pin into the vagina to relieve the irritation, and on one occasion the hair-pin slipped out of reach. A swelling appeared above and to the left of the pubes, which eventually broke and discharged pus and calculous matter. At that time a calculus was detected in the bladder, and an attempt was made to crush it, but without success.

On July 24th, under chloroform, the urethra was dilated, and a lithotrite placed on the stone, but it was so large that the screw failed to act.

On further examination a hair-pin was detected penetrating the coats of the bladder. It was then decided to open the bladder above

the pubes. The operation was performed under the carbolic spray, and the wound dressed antiseptically.

The stone was removed with little difficulty.

The Woodcut represents the stone transfixed with a hair-pin, the points of which had penetrated the coats of the bladder, giving rise to the abscess. The patient made a good recovery, without a single bad symptom.

---

10. *Calculus from the kidney.*

By William M. Ord, M.D.

The calculus had been found in the right kidney of a man who died in St. Thomas's Hospital of malignant disease of the bowels. It filled the pelvis of the kidney completely, and was so closely invested by the walls of the pelvis that there was difficulty

Woodcut 2.

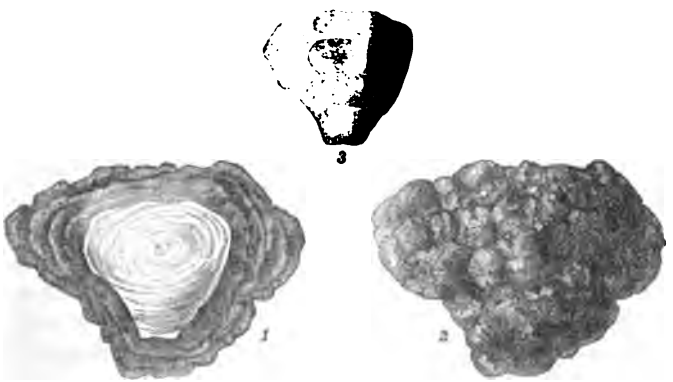

Renal calculus. (From drawings by Mr. C. Stewart).

1. Section of calculus; the nucleus lying free in the centre. 2. Outer surface of calculus. 3. Outer surface of nucleus, showing erosions.

in raising them from it with forceps. There was no pyelitis, and there had been no renal colic. When first removed the calculus was black and tuberculated, giving to the eye the idea of a dark mulberry, but to the touch it was moist and softish on the surface,

though evidently hard within. The impression given was such as might be given by a hard nut with a soft rind. After being slowly dried the mass was cut through, when it was found to consist of a much-wrinkled fragile black shell, with a hard kernel of a dark-grey colour. The section of the kernel showed concentric lamination; but on three sides the circumferential laminæ were interrupted as by erosion, and the surface at these parts was found correspondingly depressed and pitted. Between the kernel and the shell was a loose powdery layer, composed of large nearly colourless crystals of uric acid mixed with brown pigment and colloidal matter. The crust was composed of a colloid chemically related to chitin, arranged in thin, parallel, originally concentric, laminæ, about the size of those of the lens. This was deeply tinted with a brown colour, due neither to blood nor common urinary pigment, and giving no reactions of indican. The nucleus was an intimate mixture of uric acid with the same pigment, the uric acid being arranged in concentric laminæ, the laminæ again being composed of crystalline fibres, perpendicular to the surface. The inference drawn from these appearances is that the uric acid calculus grew in the pelvis of the kidney without producing irritation, till it filled the cavity, and then became subject to laminar deposit of the chitinous *débris* of epithelium, as false teeth in the mouth or a pessary may be coated with a thick non-purulent stuff, that some uric acid was also deposited in these laminæ, and that by the agency of this and the colloid the surface of the already formed calculus was eroded. The process suggested as having produced the erosion is that which is called by Mr. George Rainey "molecular coalescence." Mr. Rainey has shown that if spherules of mixed carbonate of lime and triple phosphate be formed in gum, and be afterwards removed to a solution of gum of different density, the spheres are disintegrated from circumference to centre, and the earthy portions reappear as crystals. The appearances in the specimen agree in a remarkable way with this experiment. In the centre we have a calculus in which the individual crystals are lost through complete admixture with a colloid; on the surface closely investing this is a soft colloid in a totally different state from the colloid within the calculus, and at the point of junction of the two are unusually large and colourless crystals of uric acid representing, as it seems to me, the uric acid set free by the process of molecular disintegration.

Nov., 1879.

11. *Congenital malposition and cystic degeneration of the left kidney.* (*Card specimen.*)

Exhibited by WILLIAM EWART, M.B.

THE patient, a man, æt. 32, died from hæmatemesis, due to chronic ulcer of the stomach. The right kidney weighed 7 oz., and showed evidence of interstitial and of tubular disease. The left kidney, after some searching, was discovered in front of the vertebral column, in the angle between the diverging common iliac vessels. It was converted into a cyst, as large as a small Seville orange, in which a few thin patches of secreting substance were recognised. The ureter was short, rather narrow, and patent throughout, but its orifice into the bladder was no larger than a pin's hole, and placed inferiorly. The left renal artery arose just above the aortic bifurcations, but several other small arteries were supplied from both common iliacs. The position of the left suprarenal capsule was unfortunately not determined.

January 6th, 1880.

12. *Cystic degeneration of the left kidney and ureter during intra-uterine life.* (*Card specimen.*)

Exhibited by WILLIAM EWART, M.B.

THE specimen was removed from the body of a newly-born infant, in whom the anus was imperforate and the bowel transposed. The left kidney was completely converted into a cyst, and the left ureter was much dilated and remarkably sacculated, closely resembling an inflated colon. No obstruction was encountered when the ureter was probed from its orifice in the bladder, but in attempting to reach the bladder from above the probe pushed forward a fold of the mucous membrane, which in this situation was very loose, It appeared probable that the results were entirely due to the valvular action of this fold in the portions of the ureter which traversed the coats of the bladder.

On the right side the ureter was doubled to within half an inch of its lower end. *January 6th*, 1880.

13. *Two complete ureters on either side of the body.* (*Card specimen.*)

Exhibited by WILLIAM EWART, M.B.

THE preparation was removed from the body of a man, æt. 45, who died from pulmonary phthisis and tubercular disease of the urinary organs.

Rather more than a year prior to his death he suffered from the symptoms of stricture, and soon after an abscess was opened in the neighbourhood of the anus.

A symmetrical abnormality was discovered at the autopsy. Both kidneys furnished two separate ureters, which began in distinct pelves, and terminated, independently of each other, in the bladder. All four ureters were pervious. The kidney presented, on both sides of the body, faint indications of having been double; it was larger than normal, and consisted of an upper and of a lower portion, which were continuous. On both sides the ureter contributed by the lower portion was uniformly dilated and much ulcerated, and the corresponding portion of the gland was so diseased as to present the appearance of a sacculated cyst, nearly devoid of any secreting tissue. The upper part was in a much earlier stage of tubercular disease, and the upper ureter was normal. The bladder was the seat of ulcerations, and the prostate was extensively excavated.

January 6th, 1880.

14. *Horseshoe kidney.* (*Card specimen.*)

Exhibited by NORMAN MOORE, M.D.

THE specimen was taken from a child, æt. 7 weeks, who was brought dead to St. Bartholomew's Hospital.

The bladder has been filled, and the renal arteries injected.

The lower end of each kidney is narrowed and curved upwards, and a process of renal tissue extends forwards and upwards from the left kidney, and unites it to the right kidney at the level of the fourth lumbar vertebra.

The left kidney has two renal arteries; the right one.

The ureters, as is usual in such cases, cross the anterior surface of the horseshoe kidney. *December 2nd*, 1879.

15. *Kidneys united by a fibrous band.* (*Card specimen.*)

Exhibited by H. A. LEDIARD, M.D.

THE patient from whom these kidneys were taken died in the Cleveland Street Infirmary, on March 15th, 1879, from double pleuro-pneumonia. The kidneys are apparently quite healthy, but are joined at their lower ends by a band, about one and a half inch in length, which is composed of white fibrous tissue. The arrangement of the arteries is unusual; the renal arteries are relatively small, and are supplemented by three branches of similar size, which spring from the aorta immediately above its bifurcation, and pass to the lower ends of the kidneys and the band. The arrangement of the veins is normal; the ureters also are natural.

In writing of the horseshoe kidney Dr. William Roberts remarks: "The isthmus usually consists of proper secreting structure, but sometimes it is composed merely of condensed fibrous tissue."

December 16*th*, 1879.

16. *Branched renal calculus.* (*Card specimen*).

Exhibited by C. H. RALFE, M.D.

TAKEN from left kidney of patient who died, in Seamen's Hospital, May 5th. No history could be obtained, as the patient was a foreigner. Symptoms, those of renal calculus, passing down to bladder intense; pain in *right* iliac region; vomiting; discharge of pus and blood with urine; retraction of *right* testicle. A few days after admission it was stated that a week prior to admission he had been struck over region of liver by a capstan-bar, and that the sickness and urgent symptoms had set in directly after. At the *post-mortem* the left kidney was found in the condition presented, the right kidney was enlarged and dilated, and a small calculus, evidently from the ureter, was found loose in the bladder.

The chemical composition of the calculi was phosphate of lime with an excess of organic matter, mere traces of uric acid, and some portions of the incrustations were composed of carbonate of lime.

May 18*th*, 1880.

17. *Mucous membrane of the bladder showing miliary tubercles; absence of tubercle in other parts of the body.* (*Card specimen.*)

Exhibited by WILLIAM EWART, M.B.

THE specimen was removed from the body of a maid servant, æt 20, who died suddenly from hæmorrhage into the pons Varolii. She was apparently quite well immediately before the seizure, but concerning her previous history no information could be obtained. The left side of the heart was hypertrophied. Both kidneys were granular and much atrophied, their aggregate weight not exceeding 5 oz.; they presented none of the naked-eye appearances of tubercle, although, under the microscope, a reticulated lymphoid cell-growth was discovered between the tubes. The ureters were rather wider than normal, and their orifice into the bladder gaped slightly. The urethra was normal, but the meatus urinarius showed a small fringe of vascular processes.

The muscular coat of the bladder was slightly hypertrophied. The mucous membrane presented miliary tubercles, which occurred chiefly at the fundus, and were arranged in small groups in the course of the vessels. No ulceration had taken place.

The remaining organs were free from tubercle, but two or three calcified glands occurred in the mesentery. *January 20th*, 1880.

18. *Syphilitic disease of testicle.* (*Card specimen.*)

Exhibited by FREDERICK S. EVE.

A LEFT testicle injected with carmine. The section shows that the whole substance of the organ is converted into a vascular, fibrous tissue, embedded in which are several firm, tough, yellowish nodules (gummata). On the anterior surface the gummata have become aggregated into a large mass, a portion of which protruded through an ulcer of the integuments. The epididymis is indistinguishable.

Microscopical appearances.—The gummata consist of a non-vascular, amorphous, granular tissue, in which neither cells nor fibres are distinguishable. They are surrounded by a vascular layer of delicate reticular, fibrous tissue, crowded with "indifferent" cells. The tissue between the nodules is composed of very vascular, fibrous tissue, arranged in a coarse reticulum, and enclosing, at wide intervals, tubes containing caseous material, which appear to be contracted seminiferous tubes.

History.—The specimen was taken from Thomas T—, æt. 35, who was admitted to Henry Ward, under the care of Mr. T. Smith.

Two years before, the testicle became swollen; it gradually increased in size, and finally an ulcer formed, which exposed the organ. A history of syphilis could not be obtained, but there was evidence of his having had a node on the sterum.

The testicle had on a previous occasion become swollen, but had subsided.

Castration was performed after the usual remedies had been tried.

The specimen is preserved in Series xxviii, No. 89, St. Bartholomew's Hospital Museum. *October 21st*, 1879.

19. *Persistent communication between the rectum and genito-urinary track in a new-born male child.* (*Card specimen.*)

Exhibited by SAMUEL G. SHATTOCK.

THE rectum terminates by a small opening in the fore part of the prostatic portion of the urethra, in front of (or below) the ejaculatory ducts and sinus pocularis. The malformation, it is evident, therefore, has arisen from the arrested development of the septum whereby the intestine is normally separated from the genito-urinary passage, the single cloacal aperture being closed from behind forwards, instead of its anterior or uro-genital division.

The malformation was operated for by a median incision, which, however, did not reach the intestine.

No further operation was considered advisable, and the child died ten days after birth.

Case under the care of Mr. Heath. *April 20th*, 1880.

20 *Uterus septus cum vaginâ duplici.* (*Card specimen.*)

Exhibited by W. J. WALSHAM, M.B.

THE uterus, externally single, is divided into two portions by a septum, each cavity being connected with a corresponding Fallopian tube. The septum extends through the cervical portion of the uterus into the vagina almost as far as the pudenda. The division of the vaginal and uterine cavities is complete, but not equal, the right half being more developed than the left.

The specimen is a good example of the deformity called by Küssmaul "uterus septus cum vaginâ duplici," which, as is well known, is occasioned by defective development in the Müllerian ducts in the second month of embryonic life; *i.e.* the contiguous and already blended, walls, instead of disappearing to form the single cavity of the uterus &c., remain and become developed into a septum often, as in this case, of considerable thickness. *November 18th*, 1879.

21. *Dilatation of Fallopian tubes.* (*Card specimen.*)

Exhibited by ALBAN DORAN.

THE right weighed, on removal, 4 lbs. 11 oz., the left 1 lb. 6 oz. Both contained a fluid like that found in multilocular ovarian cysts. To the left tube is attached the ovary; several pedunculated cysts spring from the broad ligament. Some of the cysts contain vegetations, similar, microscopically, to the papillary growth from the interior of the Fallopian tube, which I exhibited before the Society in October, 1879 (see p. 174 of this volume).

From a young woman who noticed a swelling in the left iliac fossa, gradually extending upwards, nine months before these tumours were simultaneously removed by Mr. Spencer Wells, in 1877. She has menstruated regularly ever since the operation till when last heard of, in January, 1880. *March* 16*th*, 1880.

22. *An alternating calculus, consisting of layers of lithates and lithic acid, finally encrusted by oxalate of lime.* (*Card specimen.*)

Exhibited by J. HUTCHINSON.

THE stone weighs 155 grains, and measures in its longest diameter an inch and a quarter. It was removed from the bladder of a healthy old man of 64. Symptoms had existed for five years, and its presence had been ascertained by sounding three years before the operation was performed.

It consists of alternative layers of reddish brown, probably lithates and lithic acid, with perhaps very thin layers of oxalate of lime. The feature of chief interest is, however, that it is encrusted by a layer of almost black oxalate of lime. This salt as an outside layer is probably very rare in elderly persons. It is possible that in the present instance its deposit dates from the time when the patient left off beer and wine (18 months). *October* 21*st*, 1879.

23. *Gumma of testis from a boy the subject of inherited syphilis.* (*Card specimen; a coloured sketch only.*)

Exhibited by J. HUTCHINSON.

THE patient whose testis is delineated in the drawing shown died in the London Hospital under Dr. Sutton's care. He had characteristic teeth and physiognomy. The testis was greatly enlarged, and showed on section an opaque yellow growth, which involved almost its entire substance. No softening had occurred. The appearances shown are those common in syphilitic sarcocele, and the chief interest of the case consists in the fact that the patient was the subject, not of acquired, but of inherited taint.

October 21*st*, 1879.

VI. DISEASES, ETC., OF THE OSSEOUS SYSTEM.

1. *Cases of osseous and articular lesions in tabes dorsalis.*

By THOMAS BUZZARD, M.D.

I HAVE brought to the Society this evening three patients who illustrate very perfectly the trophic changes in bones and joints which are apt to occur in tabes dorsalis, and for our knowledge of which we are principally indebted to Professor Charcot, of Paris. It is somewhat remarkable that the subject, although equally interesting and important to the physician and surgeon, should have hitherto failed, so far as I am aware, to have engaged the attention of any of the metropolitan societies, although the profession is indebted to you, Mr. President, for valuable contributions to it in your recent lectures at the Royal College of Surgeons. Last year I exhibited at the Harveian Society the male patient who attends here to-night, but with this exception, I do not know of any specimens having been shown of the remarkable lesions which are to be seen in the cases which I have the honour to present to you. It is on this account that I must ask your permission to enter into details at somewhat greater length than is customary at our meetings, whilst I give evidence, in the first place, that the patients are affected with tabes dorsalis; and secondly, that the osseous and articular changes are of the kind peculiar to that disease, and not accidental complications.

The two female patients are brought before the profession to-night for the first time, and I propose, therefore, to read notes of their history and present condition. The case of the male patient (to whom reference has been made), has already been published ('Lancet,' January 18th 1879). In spite of this I have ventured to bring him also to-night, because he presents a very interesting example of the subject under consideration, and his condition lends material aid to the recognition of that of the other patients.

As the history of his case is already in print, it will be sufficient for me to say now that he is a typical case of locomotor ataxia presenting electric shock-like pains, anæsthesia, ataxia, contracted and inactive pupils, and absence of patellar tendon-reflex. There is complete disorganisation of the right hip-joint, the head and neck of the femur having entirely disappeared. There is, besides, a sort of bony splint, about nine inches in length, extending down the front of the thigh, connected in some way with the quadriceps extensor muscle, and apparently the result of ossification of fibrous or muscular structure. I may add, too, because it is a point of extreme importance, that the disorganisation of the hip-joint was accomplished within the space of three months. The patient, who had been subject for six years to the lightning pains, was one day walking when a sudden pain, described as being "like a shock from an electric battery," shot upwards from his right heel to his hip, and caused him to drop to the ground. He got up and walked home, a distance of two miles, without pain or inconvenience. Next day he felt nothing wrong. A few days later, however, he was taken, he says, with a "kind of fever," and there was great swelling in the right hip, which extended also down the thigh, as far as the knee-joint. After keeping his bed three months, and enduring much suffering from lightning pains, he found his right leg shortened.

Case 1.—Elizabeth W—, æt. 50, widow, was admitted an inpatient of the National Hospital for the Paralysed and Epileptic, under my care, on December 31st, 1879. For the opportunity of observing this patient I am indebted to Dr. Lediard, under whose care she had previously been in the Cleveland Street Sick Asylum, and who kindly permitted me to take her for a time into hospital. The notes of the case were for the most part taken by Mr. A. E. Broster, Resident Medical Officer.

Patient has one child living, healthy, and has had, besides, three, who died, one a day or two after its birth, a second when nearly three years old, and a third at twenty-one years. She has never miscarried, and has had no stillborn children. Patient has never suffered from acute rheumatism or scarlet fever, and has never had a sore throat (except from cold) or skin eruption. In the family there is no history of tubercle or nervous disorder. Her husband drank heavily.

For the last eleven years she has been subject to frequent and

violent attacks of so-called "indigestion," the most severe of which occurred in July, 1878, and lasted till late in September. It was on account of this attack that she was admitted into the Cleveland Street Sick Asylum, where she had been for upwards of a year a patient when I saw her in October last. She would have attacks of gastric pain and vomiting, lasting ordinarily two or three weeks at a time, and recurring at intervals, which varied a good deal in length. She has had as many as four attacks in four months, and the longest period of exemption has been eight months.

In the attacks, she says, there is a "bad sensation" in the stomach and she can keep nothing down. There is great pain in the chest and stomach, which feel as if they were raw, accompanied by much flatulence and a great deal of retching. She will sometimes bring up greenish stuff and food, but she is sick even if no food has been taken. She has never suffered from diarrhœa, but at times there has been a tendency to tenesmus. During the retching there is a feeling of tightness across the chest, and afterwards a soreness.

Soon after the commencement of these gastric attacks, *i. e.* nearly eleven years ago, she had pains in her limbs, in the legs more than in the arms, very sharp shooting pains, so sharp at times that they would almost make her fall down, and indeed, once or twice, when the pains have seized her in the knee, she has fallen in the street. After the pains she observed a weakness in the extremities. The pains have continued at intervals. Frequently they have kept her awake all night. She may have a "bout" of pains, lasting a day and night, in one situation, and then after a few days, or even weeks' intermission, a recurrence in another place.

For the last four or five years she has had a fear of walking in the dark, and even in the light she would stagger as if drunk. Eight or nine years ago, while walking, a man stopped her and inquired: "Is'nt the pavement wide enough for you, ma'am?" This was the first time her attention was called to the staggering. There was weakness of the right leg, but she could walk without assistance three or four years ago.

In October, 1878, whilst walking quietly along the ward in Cleveland Street Asylum, "the right leg gave two snaps," and it was found that her thigh was broken.

In July, 1879, whilst retching in bed, the left hip-joint suddenly "bulged out."

Patient has never had double vision. Her bladder has never leaked, and no difficulty with the rectum is complained of.

At the present time the patient is confined to her bed or chair on account of the condition of her lower extremities. At my request Mr. William Adams has been good enough to examine the state of the hip-joints, and the following is his report:

"In reference to the condition of both the hip-joints, I made a careful examination on the 15th January, 1880.

"As the patient is lying in bed on her back the left leg is rotated inwards, and apparently shortened. There is no real or permanent shortening, for upon examination very little, if any, difference in measurement can be made. On both sides the measurement from the anterior superior spinous process to the upper margin of the patella is twelve inches. When extension is made on the left leg this measurement increases one and a quarter inch, and when on the right one inch.

"The right leg lies straight. The movements of both hip-joints are free, but limited in some directions, with crepitation much more marked in the right than the left.

"In the right, flexion and extension free; abduction and rotation inwards limited. The inclination is to rotation outwards.

"Left leg, flexion and extension free.

"Rotation outwards extremely limited.

"Rotation inwards much more than normal.

"The inclination is to rotation inwards, with a little flexion at the hip and knee.

"In neither of the thighs is there any evidence of fracture of the *shaft* of the bones.

"On the right side the top of the great trochanter is horizontally nearly on a level with the anterior superior spinous process, and rather depressed than otherwise.

"On the left side the top of the great trochanter is not much displaced upwards, but the whole trochanter is extremely prominent and the bone enlarged, at first sight conveying the idea either of dislocation or a large amount of callus thrown out after a fracture. Neither of these conditions, however, can be definitely made out.

"There can be no doubt about the existence of structural changes in the head and neck of the bone, as well as great enlargement of the great trochanter and upper portion of the shaft.

"There may have been spontaneous fracture of the neck of the thigh-bone in both hip-joints, or the present condition as to shortening (*i. e.* unnatural mobility in this direction, whilst mobility is limited in other directions) may be the result of complete disorganisation of the joint, with atrophic changes and absorption of the head and neck of the bone on the right side, and similar changes on the left side, associated with enlargement of the great trochanter from thinning out of new bone."

For the rest, she has had during the last three or four years great difficulty in buttoning or doing anything with her hands which she could not see, and this especially with the left hand.

She complains of an aching pain in the right leg. She has not had any sharp pains for a week or two. They come on, she says, in paroxysms, and last twenty-four to forty-eight hours. "It is like electricity," is her description, "shooting from one place to the other, sometimes down one arm and sometimes down a leg." She does not remember the pain ever to have occurred in both legs at the same time, but it will seem, she says, to shoot from one leg or arm to the other, and sometimes from the arm to the leg. The pains are always worse on the right side.

Her pupils are very small, and do not react to light. They both dilate when she looks up. They contract during accommodation. There is apparently some drooping of the eyelids.

No abnormality is to be noticed in the cutaneous sensibility of the face, pharynx, uvula, or palate. The right grasp measures, by the dynamometer, fifteen kilogrammes; the left the same amount.

Cutaneous sensibility.—Upper extremities.—A slight prick with a pin is not recognised in the tips of the left fingers; a sharp pinch is recognised after a delay of two seconds. Touch is felt as "numby." In the right finger tips a slight pinch is not recognised at all, a sharp one only after three seconds.

On both forearms and arms sensibility is not apparently affected.

Muscular sense, as to the position of the arm, very deficient, but she tells the difference in the weight of variously-loaded balls accurately.

Lower extremities.—Feels a needle pinch, after marked delay (two or three seconds), in the left leg and foot-sole, but does not feel it

at all in the right. She recognises a finger-touch, however, on each leg. The muscular sense is very defective. She feels as if her legs were across one another.

The patellar tendon-reflex is absent in each leg. The skin-reflex of the foot-sole is normal.

CASE 2.—Catherine M—, æt. 36, married, has two children, and has had miscarriages.

The patient is at present an out-patient of the National Hospital for the Paralysed and Epileptic, under my care. I am indebted for the opportunity of observing the case to Professor Henry Smith, by whom she was treated in King's College Hospital during the month of January last year. For the following notes of the case, at that time, I am indebted to the surgical registrar and dresser of the case:

"She has had 'rheumatic' pains in all parts of the body at different times.

"About six years ago she noticed weakness in her legs, for which she attended at St. Mary's Hospital. She describes the weakness as having been chiefly in the left leg, and accompanied by numbness. She could not feel the ground as she walked, and was constantly falling. At this time there was no double vision.

"The difficulty in getting about has been gradually increasing until two years, when the right leg became red and swollen, without being painful. With rest in bed the swelling subsided, but on getting up and moving about it recurred. Also, about this time, pains of a plunging character used to attack her, the shock of them lasting only a second or two. She was able to walk about till December, 1877.

"In June, 1877, she had another attack of swelling and redness in the right leg, which continued until September, when the swelling disappeared, but the joint was affected and useless.

"Before admission her left leg began to swell, and has remained more swollen than natural up to the present time.

"She also noticed a peculiarity in her vision, a shawl that she knew to be red and black appearing green. At times she is unable to distinguish colours. She says that when standing she was obliged to keep her eyes open, for on shutting them she felt as though she would fall.

"*Present condition.*—The patient is fairly nourished.

"The left leg is swollen, painful, and red. Left knee-joint not affected.

"Muscles of left thigh and leg are wasted; the same conditions exist on right side.

"The right knee-joint is disorganised; the skin over it is natural in colour and to the touch.

"There is no pain in the joint, even on applying firm pressure. Grating can be felt when the extremities of the bones in the knee-joints are moved upon one another.

"The leg hangs loosely, and is dislocated backwards and rotated outwards.

"The internal condyle projects inwards, and is enlarged.

"The external condyle cannot be felt.

"The patella rests on the outer surface of the lower end of the femur; the ligamentum patellæ can be felt, but is apparently wasted.

"Fluctuation can be felt in the joint.

"Bowels torpid; cramping pains continuous in belly. Partial loss of control over bladder. Micturition frequent.

"*Urine.*—Reaction acid; no albumen or sugar.

"Occasional sudden starting pains in limbs.

"Difficulty in picking up pins, from inability to feel them.

"No spinal tenderness; no headache.

"January 13th.—Since admission the patient has remained at rest in bed. The swelling and redness of the left leg have gone down.

"The knee-joint is considerably enlarged, especially the lower end of the femur.

"The leg is becoming dislocated backwards and outwards. There is great laxity of the ligaments of the joint.

"Other symptoms continue except those of the bladder, micturition being less frequent, and urine scanty, only thirty fluid ounces being passed in twenty-four hours; no incontinence.

"Both knees are now kept in place by leather cases."

Since her discharge from King's College Hospital she has lived at home, and, thanks to the support given by leather cases for her knees, has been able to employ herself in housework.

At a recent examination of her I made the following notes:—"She may go one or two months without pains, and then they attack her for three or four days and nights in succession, keeping her

awake. They are plunging and stabbing, 'just like being stabbed with a fork.' She usually has a pain at the pit of the stomach, going through to the back. There is dreadful griping and belching of wind. For three or four weeks past she has had this every day, but now she is getting better again. The attack usually begins about 4 or 5 a.m. It is not accompanied by diarrhœa, but she gets swollen up like a woman near her confinement.

"After a bout of pains of this description she may go one, two, or three months without any, and she feels as though she would never have them again. Then she will be suddenly seized with them.

"The stomach pains began more than ten years ago. She has been married ten years, and previous to that had suffered from the stomach pains, though not so severely as she has done since. At that time, too, she used to have stabbing pains in her knees and one of her finger-joints, which she thought was rheumatism.

"Formerly, when the stomach pains attacked her 'she would vomit all day and all night' for two or three days together. She threw up 'enormous quantities.' After a few days this gradually ceased.

"Between the intervals of the pains she feels quite well. Her appetite is good, and she has nothing (except the crippled state of her legs) to complain of.

"The plunging pains described attack her in the joints and limbs, but never in the trunk, except in the stomach. She may have gone three months, but never six months, without the stomach pain.

"She says that the swelling in the legs extended at first right down to the feet, so that she could not see her ankles.

"Her pupils are very large. They do not contract to light, nor, I think, during accommodation.

"She has lately had swelling about the right shoulder-joint, which has almost disappeared. But the joint creaks, and is somewhat painful when moved. The left shoulder-joint has also still more recently began to 'feel queer.' She recognises in these symptoms a close resemblance to the manner in which her knees began to get bad. There was no pain in the right knee-joint, she tells me, whilst it swelled.

"She is quite lost in the dark.

"There is difficulty in buttoning things. In sewing she has stuck

the needle into her finger and has not felt it. She has put her feet into water nearly boiling, and for a few seconds could not tell whether it was hot or cold, but has then had to withdraw them.

"The muscular development of her arms is very striking, and resembles that of a labouring man. Owing to the difficulty with her legs a great amount of work is thrown upon the arms in moving about."

Mr. Broster has been good enough to examine her knee-joints and the following account is derived from his report.

"On removing the leather casing from the right knee-joint, the joint seems to fall abroad. The patient can replace it herself and says that when she puts on the casing she has to take the bones and put them straight in their places, and bind them up with a bandage to keep them together whilst she puts on the casing. The joint can be twisted about and the bones knocked together audibly without causing pain.

"On manipulating the joint the feeling is as if all ligamentous connections had disappeared, and the bones were simply held together by the muscles and cutaneous tissues. It seems as if the lower end of the femur had had its condyles bevelled off, and the end turned into a rounded stump. The end feels smooth, and the posterior fossa can be distinctly made out.

"The patella, which is perfect, lies drawn upwards and outwards, about two inches above the end of the femur. Above it is felt what appears to be a synovial sac. The peroneo-tibial articulation (upper) seems perfect.

"The upper end of the tibia is bevelled off inwards; the fibula, with the outer part of this tibia, can be felt projecting along the outer side of the inner hamstring in a firm smooth mass, about one inch long by half an inch in diameter, somewhat rounded.

"The ends of the bones are not in apposition, nor can they be got into apposition. The tibia and fibula project upwards on the outer side of the femur. The upper end of the tibia and of the fibula is exceedingly loose, and it seems that when the patient fixes on her casing, instead of putting the bones in normal apposition 'end on,' she splices them together tightly side by side. She says the lower bone always projects outwards, never inwards. She says that 'formerly the joint was enormously distended.' There is certainly no distension now.

Left lower limb.—On removing the casing the bones, which had been in apposition 'end on,' at once separate, the tibia and fibula being dislocated backwards with a tendency outwards. There is marked laxity of the joint. The tibia and fibula can be moved slightly laterally and very freely backwards.

"The patella lies over the lower extremity of the anterior surface of the femur. The condyles appear to be rounded off, and the inner one is larger than it should be. No pain in examining the joint.

"*Cutaneous sensibility.*—In both foot-soles a pin-prick is not felt. In both legs a severe prick with a pin is felt after three seconds' delay, and then but very indistinctly. In both thighs the same is felt indistinctly after a delay of two seconds. The patient feels a pin on finger tips and hands very indistinctly after a delay of two seconds. In the forearm she feels a pin indistinctly, and in the arms she feels a pin but not so well as on the face."

Remarks.—It was in 1868 that Professor Charcot for the first time drew attention, in the 'Archives de Physiologie,' to the arthropathy which was apt to occur in the course of tabes dorsalis. He described the joint affection as characterised by—1st, considerable hydarthrosis, and 2ndly, a diffused swelling extending far beyond the joint, for the most part of hard consistence, and in which the ordinary characters of œdema were not apparent. The arthropathy was generally not accompanied by fever or pain. It was sudden in its onset, and might bring about irreparable disorganisation of the joint in a few days or weeks. Sometimes at the end of a few weeks or months the swelling disappeared, and the joint returned to its former condition, but in many cases, so far from this happening, there was a rapid absorption of a large part of the articular extremity.

His memoir was speedily followed by that of M. Ball, a translation of which appeared in the 'Medical Times and Gazette,' 1868-69. Soon afterwards Dr. Clifford Allbutt, published in the 'St. George's Hospital Reports,' 1869, "a Case of Locomotor Ataxy with Hydrarthrosis," the first example described in England. Since then a considerable amount of attention has been paid to the subject, especially in France, and numerous contributions have appeared at the hands, amongst others, of Richet, Bourneville,

Vulpian, Bouchard, Dubois, Voisin, Oulmont, Bourceret, Michel, Forestier.

About the same time Dr. Weir Mitchell in America, in an article "On the influence of Rest in Locomotor Ataxy" ('American Journal of Medical Science,' July, 1873), alluded incidentally to the frequency of fractures in tabetic patients. In 1874, necropsies published by Richet, Voisin, and especially those by Raymond, in 1875 and 1876, have thrown important light upon the subject.

As regards the affection of joints in this country, the only cases of tabetic arthropathy which have been published, so far as I am aware, since Dr. Allbutt's, have been two of my own; one in 1874, and the other last year, the one being a typical case of hydrarthrosis of the knee-joint in a tabetic patient, the other being the male patient, who is now present. In the 'Medical Times and Gazette' for August, 1877, a case is published by Dr. H. Thompson.

It was not till 1873 that Charcot communicated to the Société Anatomique of Paris the case of a woman affected with tabes dorsalis, in whom, concurrently with great disorganisation of certain joints, multiple *spontaneous fractures* of the neck of the left femur, of both bones of the forearm, right as well as left, had occurred. Until then the question had only been one of the influences of tabes in causing a condition of joint which had a *primâ facie* resemblance to arthritis deformans. The relation of a peculiar friability of the bones to this disease of the nervous system now comes under consideration.

Whereas at first the question was one concerning the joint affections, and next the occurrence of spontaneous fractures, more recently the lesions of the bone in general have come to the front, and at the present time Charcot tends to consider these osseous lesions as the primordial fact, the joint affection being only, like the fractures, secondary manifestations of this defective nutrition of the osseous tissue. "The fault of nutrition," he writes, "due to an influence of the nervous system which makes the bones fragile, and thus leads to spontaneous fracture, is also, I think, one of the principal elements which combine to the production of the singular arthropathies. The extremely rapid and extensive wearing away (*usure*) of the articular extremities is the principal character which distinguishes ataxic arthropathy from common dry arthritis."

"Destruction and disappearance, partial or complete, of the epiphyses," writes M. Talamon,[1] "fragmentation and absorption of the head of the humerus in one case, atrophy of the projecting portions, such are the principles and always identical alterations of the osseous extremities that have been met with in the shoulder, the hip, and the knee. In no case have there been observed the hyperostoses, the epiphysal hypertrophies, which characterise dry arthritis. In cases of spontaneous fracture from ataxia, certain bones have been found reduced to a remarkable state of thinness and deformity."

In one woman the left femur, which had been fractured, measured nineteen centimètres, the right forty centimètres. The bone was found to be formed of two portions united by an *exuberant* callus. And it is noteworthy, in reference to the first of my two cases, that it has been the rule to find in examples of tabetic fracture the bones consolidated with "voluminous and shapeless callus." "In one of the forearms," Talamon writes, "the work of cicatrisation had engulphed in one and the same exuberant mass the fractured extremities of both radius and ulna."

In the three patients who are present we have examples of all the conditions which have been described as characterising the osseous and articular lesions of locomotor ataxia—extensive swelling, sometimes painless, and never confined to the joint, but extending also down the long axis of the limb, disappearance or disorganisation of the articular ligaments, rapid erosion, and absorption of the ends of the bones entering into that joint. The rapidity with which these changes have been brought about is very marked, the period in each instance occupying but a few months. In the other case we have a spontaneous fracture of the neck of the femur, certainly on the right side, and I should have no doubt, from the history, also on the left, although the existing condition is compatible with the alternative of a disorganisation of the joint. But as regards this, I shall be glad to learn from surgical members of the Society. I would submit that the evidence of the patients being examples of tabes dorsalis leaves no room for doubt.

This is not the place to enter at any length upon the question of the probable seat of the central lesion which brings about such

[1] 'Revue Mensuelle de Méd.,' Paris, 1878. I have largely availed myself of M. Talamon's references.

startling changes in the nutrition of bones and joints in tabes dorsalis, but I should like to make one or two suggestions as to the direction in which, as it appears to me, pathological anatomy, and physiology might profitably shape their inquiries. I would remark, first, that, on account of a supposed analogy of these trophic changes with the atrophy which occasionally occurs in the muscular system in the cases of tabes, Charcot early suggested that a lesion of the anterior horns might probably be their point of departure. At first the result of observation appeared to be favorable to this view. In three cases, as I gather from Talamon (loc. cit.), atrophy of ganglionic cells in the anterior horns was observed. But in three more recent autopsies it has been impossible to find the least alteration in these cells. On the other hand, we must remember that very extensive lesions in the anterior cornua are frequently being met with in cases of progressive muscular atrophy and infantile paralysis, when certainly no such changes existed during life in the bones and joints as those we are now considering.

The enormous development of the muscles of the arms in Catherine M—, alongside of a commencing arthropathy of the shoulder-joints, seems quite inconsistent with the view in question. The evidence, therefore, so far as it goes, appears to be distinctly against the possibility of ascribing the osseous and articular disorders of nutrition to lesion of the large cells in the anterior horns of the cord.[1]

Now, I would direct attention to a very interesting circumstance which has struck me in connection with these cases. I find that the gastric symptoms of tabes—the *crises gastriques* of Charcot—are of extraordinarily frequent occurrence in these cases of ataxic arthropathy. The frequency of this association is far beyond what might be reasonably explained by an accidental association, as I think will appear evident presently.

The two women whom I show you both present typical examples of *crises gastriques*. It was this remarkable circumstance which induced me to inquire especially into this point. Vulpian[2] says that he has only seen one case of spontaneous fracture in a tabetic patient. That case was marked by *crises gastriques*. Out of the

[1] I have observed, in certain instances, an arthropathy connected with progressive muscular atrophy, but its characters resemble those of arthritis deformans. It is slowly progressive and apt to affect the fingers and smaller joints.

[2] 'Maladies du systême nerveux,' Paris, 1878.

seven cases characterised by osseous or articular lesions which are narrated by Charcot in his lectures no less than three were marked by gastric crises.

I may here say that, besides the patients who are here to-night, I have had under my care another case of marked arthropathy in a tabetic patient. In him, although there was a peculiar and unusual irritability of the bowels, occasioning frequent call to stool, there could not be said to be gastric crises in the marked and definite sense which is at present under consideration. Nor has there been any attack of the kind in the man W—, who is here now. Besides the cases I have mentioned I have met with a few others belonging to the class of ataxic arthropathy, but not so strongly marked as that I should like to use them for statistical purposes. But in looking through French periodicals I have come upon nine other cases of osseous lesions in tabetics, reported by different authors, and in two of these there were typical *crises gastriques*.[1] There must be more cases of tabetic arthropathy in print, but it chances that these are all that I have been able to meet with. If we add together these various observations we find that out of twenty-one cases of osseous lesions of this class no less than eight were characterised also by the occurrence of typical *crises gastriques*. I do not like to include the sixteen cases of arthropathy consecutive to locomotor ataxia published in the mémoire of Prof. Ball,[2] because many of these occurred in the practice of M. Charcot, and there would be danger, therefore, of counting a case twice over. It is worthy of remark, however, that M. Ball seems to have been struck by the unusual frequency of visceral symptoms in the cases of arthropathy which he groups together. The following is his reference to this point:

"Il est peut-être interessant de noter ici que dans un quart des cas (4 sur 16) des troubles viscéraux liés à l'ataxie locomotrice progressive, et paraissant dépendre d'une lésion du grand sympathique, se sont développés parallèlement aux accidents articulaires" ('Gaz. des Hôpitaux,' 1869).

The startling character of the proportion (eight cases of associated gastric crises out of twenty-one cases of tabetic arthropathy) will be evident when the comparative infrequency of the special gastric complication in tabes is considered. I have lately tabulated fifty-six

[1] Heidenbach, 'Société d'Anatomie,' 1874. Voisin, ib., 1874.

[2] 'Gazette des Hôpitaux,' 1868–69.

cases of tabes dorsalis, which have occurred in my own practice, for comparison. In only eight of these were there gastric symptoms, and in only four were these so marked and definite as to be properly included in the category of *crises gastriques*.[1]

It will be important, of course, to observe whether the proportion showing *gastric crises* is preserved over a larger range of numbers than I have been able to quote. But, even as it is, the frequency of this peculiar combination of symptoms appears to me to point, without doubt, to something more than a mere accidental coincidence. If this be so, and considering that the evidence as to the supposed primary seat of the changes causing the articular lesions being in the anterior horns has broken down, I feel justified in suggesting the advisability of directing our inquiry in future to the medulla oblongata. We have, side by side, gastric symptoms, for the explanation of which I suppose we may pretty confidently point to lesion of the nuclei of origin of the pneumogastric, and other symptoms which show a remarkable frequency of association with these. It is a legitimate inference that lesion of a structure adjacent to the

[1] In the course of the discussion upon this paper, the President (Mr. Hutchinson) mentioned the case of a patient of his own, a gentleman of middle age, who, after having been subject to frequent and periodical attacks of severe gastric pain and vomiting, became affected with what was at first supposed to be rheumatic arthritis of the right hip-joint, but which the presence of characteristic lightning pains and the subsequent occurrence of white atrophy of the optic nerves showed to be connected with tabes dorsalis. Dr. Allen Sturge referred to a case which he had under observation, that of a man affected with locomotor ataxia, with marked gastric crises, who had developed hydrarthrosis of the knee-joints. Dr. Gowers showed a specimen (the elbow-joint) from a case in which there was no history of gastric crises. Since this paper was read, three more cases of tabetic arthropathy have fallen under my observation. Particulars of these will be published elsewhere, but I might say that two of them are marked by typical gastric crises. One is a female, at present under the care of my colleague Dr. Radcliffe, in the National Hospital for the Paralysed and Epileptic, who has a swollen and disorganised hip-joint. The other is a man, with great enlargement of one of his shoulder-joints, the humerus hanging loosely like a flail, with probable absorption of at least a portion of its head. He likewise, as well as the woman, has had for years periodical attacks of gastric pains and vomiting. For the opportunity of observing this case I am indebted to Dr. Whitmore, Resident Medical Superintendent of the St. Mary Abbott's Infirmary, Kensington. If we add these cases to those already enumerated, we obtain a total of twelve cases of associated gastric crises, out of twenty-six cases of tabetic arthropathy.—T.B.

[2] 'Gazette des Hôpitaux,' 1869.

nuclei of the vagus may be found to explain the latter. Whether this may be in the so-called vaso-motor centre, or whether physiology may yet have to discover in the medulla oblongata a centre directly concerned in the nutrition of the osseous skeleton, it would be entirely premature to discuss. One cannot help feeling, however, that, were the existence of such a centre to be rendered probable, we might find in it a valuable clue to the explanation of the articular symptoms in acute rheumatism, as well as to the occasional tendency to high temperature, and still more to the extraordinary frequency of cardiac complications in that disease, an association for which hitherto no hypothesis has reasonably accounted. Light might be expected to be thrown, too, on the nature of arthritis deformans.

February, 1880.

---

2. *Malformation of arm.*

By Allen Sturge, M.D.

Herbert A—, æt. 22, admitted as a patient at the Royal Free Hospital for some trifling ailment, presented a congenital deformity of the left arm, belonging to the class of malformations which have generally been described as due to intra-uterine amputation.

Family history.—His father, who was a healthy man, died at the age of 71. His mother living and healthy. She asserts that when pregnant with the patient, she was frightened by a man who had lost an arm, and who ran after her in a wood. The patient has a brother and three sisters, all of whom are healthy and present no deformity of any kind. A brother, a soldier, died of "tumour of the brain." Two other children died in infancy.

The patient is a very fine man, his height being 6 ft. 3½ in., and he is well made in all respects except the deformity of the arm. The greater part of the left forearm and the hand are absent, the forearm ending in a somewhat conical stump about three inches below the elbow-joint. Both the radius and the ulna are present in this stump, the upper extremities of these bones being apparently normal. The lower end of the bones, which apparently do not

articulate with one another, taper off into points, the tapering extremity of the radius being rather longer and more sharply pointed than that of the ulna. Over the end of the radius the skin forms a conical projection, the size of a hazel nut, which stands out prominently from the general surface of the stump. There is no adhesion between the skin and the bone. The skin over the end of the ulna is umbilicated, the result, apparently, of adhesion of the subcutaneous tissue to the end of the bone. The skin over the end of the radius presents two faint whitish lines at right angles to one another, one of them being about half an inch and the other about a quarter of an inch in length. These appear to be old cicatrices. There are other cicatrices on the stump, which have the appearance of having resulted from large superficial sores. The patient says they are the remains of boils, several of which he has had on the stump.

On the flexor aspect of the stump, about midway between the ends of the radius and ulna, are five little projections, situated transversely across the stump. The projection nearest to the radial side of the forearm is the largest, and the others get smaller by degrees as the ulnar side is approached. The largest is about the size of a pea, and the smallest that of a moderate-sized pin's head. The largest and the adjoining nodules have well-marked nails, the free convex surface of which is directed towards the extensor aspect of the forearm. The nail on the second nodule is larger than that on the largest nodule. There is a semblance of horny growth on the third nodule also.

There is free movement of the stump. He can flex the elbow to an angle of about 60°, and he can extend it in an unusual manner, for when the elbow is fully extended the stump of the forearm, instead of being in a straight line with the arm, makes an angle with it posteriorly of about 120°. He seems to have very little power of pronation and supination independently of flexion and extension, but flexion is accompanied by a certain degree of pronation, and *vice versâ*. Pronation and supination of the bones can be easily produced by external manipulation.

The muscles of the upper arm and shoulder are considerably smaller on the left than on the right side, and there is shortening of the humerus, to the extent of about half an inch, as compared with the right.

Remarks.—This case comes within the category of those which have been described by Montgomery, Simpson, Annandale, and

others, as resulting from intra-uterine amputation. The amputation is attributed to the constriction exercised on the limb by bands of organised lymph due to inflammation in its neighbourhood. These bands having surrounded the limb in an early stage of intra-uterine development, gradually became tightened as the lymph contracts and as the limb grows larger, until at last they bring about a separation of that portion of the member below the seat of constriction.

That this is the true explanation of a certain number of deformities of this kind is proved by the fact that in some few instances the amputated part has been actually found; but I think that a reference to a number of cases of congenital deficiency of parts of limbs will show that in a considerable proportion of such cases the cause must be sought in some other direction than the hypothesis of amputation *in utero*.

This other mode of causation may consist of either one of two factors—(1) a primary inherent abnormal condition of the ovum, whereby its healthy development is interfered with in one or more directions; (2) a localised morbid condition of one or more parts of the embryo due to onset of disease in the embryo at some period after conception. The former of these two conditions must be invoked in explanation of many cases of monstrosity, of cases where there is congenital hypertrophy of parts, and it is the most probable explanation of supernumerary parts. There can be no reason, therefore, why it should not also produce the opposite conditions, viz. congenital atrophy of limbs and congenital absence of portions of limbs. On the other hand, an inflammatory process capable of throwing out organised lymph in sufficient quantity to produce intra-uterine amputation is quite as likely, if it attacks that portion of the blastoderm from which a limb is developed, to kill the delicate embryonic cells, or to modify their nutrition so profoundly that their subsequent development will be gravely compromised.

It is conceivable, therefore, that cases like that I have described may be produced by mal-development due to either of these two causes.

Mr. Annandale, in his work on 'Malformations, Diseases, and Injuries of the Fingers and Toes,' mentions thirteen cases of congenital deformity, characterised by absence or atrophy of portions of limbs. Four of these he attributed to intra-uterine amputation. He makes no reference to the causation of the remainder, but he

would probably attribute them to one of the two above-mentioned causes.

Of the four cases attributed to amputation two were marked by absence of one hand, the arm stopping short at the wrist. In both instances nodules were present on the stump, representing the digits. In a third case absence of the forearm and the occurrence on the stump of nodules representing the fingers was associated with very marked atrophy of the rest of the arm, which was scarcely larger than that of a new-born child. In the fourth case two of the fingers of the left hand were absent, and a third was constricted at the base. In this case all the other limbs presented deformities of some other kind.

Among the cases not referred to amputation was one of absence of both forearms and hands, each stump having one finger growing from it by a loose attachment. There were three cases of absence of several fingers of one hand, two cases of absence of fingers or parts of fingers in both hands, one of absence of fingers in one hand combined with atrophy of the whole arm, one case of absence of certain fingers in both hands, distortion of such fingers as were present, and malformation of one foot.

If these two classes of cases be carefully compared it will be found that there is no feature in connection with the first-mentioned class which justifies us in separating the cases of which it is composed from those forming the second class. For instance, the case of so-called amputation of the forearm in the first class very closely resembled the case in the second series, where both forearms were absent, the only essential differences being that the lesion was bilateral in the latter case, and that in the former case the whole limb was deformed, this latter character pointing rather in the direction of modified development than of intra-uterine amputation. The two instances in which one hand was absent differed also from the case of bilateral absence of the forearm in respect of the unilateral nature of the lesion alone. In the fourth case, attributed to amputation, there is nothing in the description to separate it from others of the same kind placed by Mr. Annandale in the second class; whilst the association of deficiency of certain fingers in one hand, with deformities of other kinds in all the other limbs, argues strongly in favour of mal-development as the cause of all the abnormal conditions present. In two of the four cases referred to amputation, therefore, there is internal evidence in the cases them-

selves that they were due to mal-development rather than to amputation; whilst the other two instances differ only from cases not classed with the amputations by being unilateral instead of bilateral. The question arises, therefore, whether we ought not, in the vast majority of instances, to look for the cause of congenital deficiency of parts of limbs in the direction of mal-development of the embryo, and whether we ought not to consider intra-uterine amputation as an altogether exceptional cause of such conditions. In certain instances the latter mode of causation can be excluded—those cases, namely, in which absence of a part of one limb is associated with deformity of other limbs, or with great atrophy or other deformity of such parts of the limb as are present. Where a part of the limb is absent, and the rest of the body, including the upper part of the limb itself, is healthy, the diagnosis of the mode of causation is more difficult; but a comparison of a large number of cases of congenital deficiency will show that every variety may be met with, from cases in which all the limbs are deficient or deformed in some other way, to cases in which the extremity of one finger only is deficient. As, therefore, no line of demarcation can be drawn, dividing the cases into two well-defined groups, so it will, I believe, be impossible to attribute those cases lying at one end of the scale to a cause essentially different from that to which the cases at the other end of the scale have been attributed.

There are two factors which may possibly be found to help us in coming to a correct conclusion with regard to certain of the doubtful cases, and to which, therefore, I think, more attention should be paid. These are—(1) the presence of rudimentary fingers on the end of the stump; (2) the presence of umbilications over the ends of the bones.

I think it is worthy of inquiry whether rudimentary fingers have been present in any of those cases in which the amputated limb has been found. It is very easy to account for them on the hypothesis of mal-development, for in that case they represent the amount of vitality left in the embryonic cells, from which the extremity of the limb should have been developed. On this hypothesis we should expect to find, as, in fact, have been found, many degrees of development, ranging from minute nodules representing fingers at one end of the scale, up to extremities of limbs, which differ but little from the hand, at its other end. This last condition was present in one of the cases recorded by Mr. Annandale. If it be found that no

rudimentary fingers occur in undoubted cases of amputation, then their presence would afford presumptive evidence in favour of the hypothesis of mal-development.

As regards the question of umbilication of the skin over the ends of the bone, with which may be classed the presence of scars on the stump, the question arises, "Do umbilication and scarring necessarily indicate amputation?" This question can only be answered by a careful examination of cases in which multiple deformity is present, so as to exclude the hypothesis of amputation. There is certainly no *à priori* reason why the formation of a rounded stump, after destruction of the embryonic cells from which the extremity of a limb should be developed, should not give rise to the appearances of cicatrisation any more than the healing of a stump after amputation. The skin in such a case would have no necessary tendency to develop uniformly round the end of the limb, and in order for it to cover in the stump of the bones and muscles some unusual process will have to be introduced, which may very possibly give rise to umbilication or slight scarring.

Further attention to these two points is, I think, called for.

The presence of deep depressions round a finger or a limb need not necessarily imply constriction by a band, for mal-development shows itself in curiously partial and localised ways, and there is no reason why it should not be present over a small area in the centre of a limb, in the same way that it is present over a small area at the tip of one finger. If there be disease of the embryonic cells, which should develop into the proximal phalanx of a finger, and not of those from which the two distal phalanges should develop, the proximal phalanx, or part of the phalanx, will be very small, whilst the other phalanges may be of full size. *May 4th*, 1880.

3. *Bony outgrowth of the great trochanter, complicating a case of impacted fracture of the neck of the femur, and simulating a dorsal dislocation of the hip.*

By Henry Morris M.A., M.B.,

John S—, æt. 69, an engine-driver, was admitted, under me, into the Middlesex Hospital, on Nov. 2nd, 1879. One hour before admission, and whilst coming downstairs, he slipped, and fell with full force upon his right great trochanter. He was unable to raise himself after the fall.

On admission the right lower limb was everted. Tested by measuring from the spine of the ilium to the inner malleolus, there was no shortening; but by Bryant's triangle, the limb was found to be three quarters of an inch shorter than the other. There was great spasm of the adductor muscles. The patient was able to move his thigh slightly, but passive motion was very restricted. There was an absence of crepitus, but a sensation was on one occasion felt as of a very slight shifting of bony surfaces on one another.

From the nature of the injury, viz. a fall upon the trochanter, and from the eversion and slight shortening of the limb, there was no doubt, at first sight, that there was a fracture of the neck of the thigh-bone; but the question of dislocation arose for the moment when on examining the hip a large bony mass was felt behind the acetabulum. It projected upwards and backwards over the dorsum ilii, and seemed to be continuous with the neck and great trochanter of the femur. The edge of this bony process, however, had not the rounded outline and smooth surface of the head of the femur, but, on the contrary, felt irregular, rough, and thin even to sharpness. Altogether it was more like what the fractured surface of the neck of the femur might feel after it had been detached from the head of the bone and turned backwards over the margin of the acetabulum, the head meanwhile remaining in its socket. Moreover, when it was remembered that a dorsal dislocation with eversion is extremely rare, that it can only occur after rupture of the posterior strong portion of the capsule, and probably also of the outer portion of the ilio-femoral ligament, and is necessarily attended with more shortening than existed in this case, the idea of dislocation was dismissed.

Nor were the eversion of the foot and the position of the trochanter major consistent with the hypothesis that the neck and shaft of the femur had been detached from the head, and displaced backwards upon the dorsum ilii; so that, in spite of the difficulty of explaining the projecting bony mass, the diagnosis of impacted fracture of the neck of the thigh-bone was finally adopted. The limb was placed in a Thomas's hip-splint, and further supported by the long outside splint; during the treatment the man was attacked with pneumonia and died on December 11th, 1879.

The following is a description of the specimen exhibited, which was dissected for me by Mr. Sutton, our Junior Demonstrator of Anatomy, and is now in the Hospital Museum.

In front the fracture extends along the inter-trochanteric ridge, being partly within and partly beyond the line of attachment of the ilio-femoral part of the capsule. Behind, so far as can be seen, the line of fracture is above the trochanteric ridge, but the greater part of the neck of the femur in this aspect is obscured by a bony outgrowth of triangular shape, the base of which is attached along the whole length of the posterior border of the great trochanter, and then along the upper two thirds of the posterior inter-trochanteric ridge. It is flat and even on its superficial surface, but its deep surface, which overhangs the back of the cervix femoris and the capsule of the joint, is somewhat irregular. Into the upper border of this bony mass the tendon of the gluteus medius passes, and into its lower angle and the lower end of the posterior border the quadratus femoris is inserted; whilst the tendons of the pyriformis and other small rotator muscles pass between the capsule and the deep surface of the mass to their insertion into the top of the trochanter. Indeed, the relation of the tendons of the gluteus medius and quadratus to the mass suggests that the outgrowth may have been formed by an ossification of these tendons. A fracture extends through the base of the mass, *i. e.* where it springs from the trochanter and posterior inter-trochanteric line, but the parts are still held together by fibrous tissue. Another and much smaller bony mass is developed at the tubercle in front, which is the meeting point of the gluteus minimus, crureus, and vastus externus. The fracture of the neck is so far impacted, and the parts are so far held together by the reflected and other fibres of the capsule, that the head of the bone rotates with the shaft. There is considerable eversion of the shaft, and now that all the soft tissues are

relaxed and flaccid, this eversion of the limb is seen to be a condition impressed upon it by the original injury itself, owing to the crushing up of the posterior portion of the neck of the femur, whilst it is maintained by the impaction of the fragments and the inclination and weight of the bone. *December* 16*th*, 1879.

---

4. *Specimen of a recent dislocation of the first phalanx of the thumb forwards.*

By Frederic S. Eve.

The specimen was taken from the body of a man, who was killed by the fall of an archway upon him. The first phalanx of the thumb was dislocated forwards and rested upon the anterior surface of the head of the metacarpal bone. The posterior portion of the capsule of the joint was completely torn across.

After the dissection was completed the dislocation was readily reduced by extension.

In vol. iv, p. 250 of the Society's 'Transactions,' there is an account of a similar case by Mr. J. Wood, in which the metacarpal bone was fractured.

The specimen is preserved in the museum of St. Bartholomew's Hospital, S. iii, No. 150. *January* 20*th*, 1880.

---

5. *Multiple sarcomata of cranial bones.*

By John Abercrombie, M.D.

Sarah R—, æt. 3 years and 11 months, was admitted into the Hospital for Sick Children, December 17th, 1878, under Dr. Gee. The following history was obtained from the mother:

Her illness commenced about three months ago with pains in stomach and back, bowels rather confined, no vomiting, anorexia. Is losing flesh, sleeps pretty well, but has cramps in her left leg

at night. Eyelids have been inclined to swell. A lump has been noticed to be forming on her head during the last six weeks. Does not complain of anything particular. Bowels regular now. Had measles when fifteen months old. No other illness. Five other children healthy. One died seven months old. Mother has had one miscarriage. Parents healthy, no phthisis on either side.

On admission.—Extremely pale, not well nourished. A small swelling, about the diameter of a shilling, over right parietal region, not tender. Glands enlarged in left side of neck. Tongue clean. Pulse 140, regular. No increase of cardiac dulness. Heart sounds natural. A little rhonchus over both backs, no dulness. Spleen not felt. A lump can be felt in left iliac fossa, movable, a little tender (?) an enlarged gland. Examination of blood shows diminution in number of the corpuscles, but no marked increase of white.

December 31st.—A little evening rise of temperature lately. Does not take her food so well. Tongue thickly furred. Extremely pallid, eyelids somewhat swollen. Soft prolongation of first sound of heart at left base.

January 23rd.—Examination of eyes by Dr. Gunn. Slight hypermetropia ($\frac{1}{24}$). Yellow spot surrounded by a white circle, in the centre of which is a red spot. Disc somewhat hazy, not pale. Vessels near the disc seem to be covered by a sort of sheen. Both eyes alike.

29th.—Temperature irregular, varying from 97° to 100°. Lump in left iliac fossa about the same. A small lump can be felt in right iliac fossa.

February 10th.—A few days ago left eyelids swelled up so much that she could not open her eye at all; this has gone down now, but there is a little swelling and tenderness of left cheek. Always extreme pallor. The nurse said she had a sort of convulsion last night.

14th.—The swelling in the right parietal region has enormously increased during the last few days, and now forms a hemispherical tumour measuring two and a half inches across; two incisions were made into it yesterday, but nothing but thin blood came away. Two other smaller swellings can be felt on left side of scalp. Veins on forehead more visible than natural. Blood examined; contains some granular matter, no increase of white corpuscles.

25th.—A few days ago it was discovered that she was quite

blind; now both optic discs are swollen and their margins are very ill-defined. The swelling in right parietal region has not altered much; that on left side is larger (about one fourth of the size of the other), and in front of it there is a smaller one. The lumps in the iliac fossæ have increased in size.

March 3rd.—Extreme cachectic appearance. All the swellings on the head have become larger. The superficial veins on the forehead are much dilated. Both eyeballs are unduly prominent, especially the right, eyelids a little swollen. Never complains of headache at all.

5th.—Some fever lately. Takes hardly any notice, but not absolutely unconscious. Optic neuritis very marked. Left angle of mouth a little longer than right.

7th.—Very restless, tears her hair out. Mouth distinctly drawn to left.

11.50 p.m.—Died.

Examination of body sixteen and a half hours after death.—Body not well nourished; weight 22½ lbs. Rigor mortis present.

Cranium.—On reflecting the scalp the skull presents the following appearance. A large, irregular, rounded swelling occupies the right parietal bone, extending to the middle line, and to within half an inch of the squamous portion of the temporal bone, from before backwards, and from side to side it measures five inches, and at its base the circumference is ten inches. Its surface is of a deep purple colour, with patches here and there, more or less yellow; it presents several rounded projections on its surface, and is everywhere covered by the periosteum, except at the points where the punctures were made during life; it feels elastic, and in places almost fluctuating. There is another tumour occupying the left parietal eminence; it is rounded, irregular on the surface, and measures one and a half inch from before backwards and laterally. In front of it is an elongated tumour, measuring two inches in length and one inch across. Both of these tumours were felt during life. Besides these, there are many other slightly raised purple patches, varying in diameter from half an inch to one and a half inch. On examining the internal aspect of the vault of the cranium, it is seen that the inner plate of the skull-cap is perforated in all cases where the tumour had attained any considerable size, and that an adhesion has been formed with the dura mater; corresponding to the lesser tumours in many places the inner plate

presents a honeycomb appearance. At the base of the skull deposits of the new growth were found in the following situations, viz. at the outermost portion of the posterior fossa near the basilar groove on each side, just in front of the base of the petrous bone on each side, at the most anterior and external part of the middle fossa on each side, and on the left side of the sella turcica in the region of the cavernous sinus. These tumours were all very soft, purple in colour, and connected with the subjacent bones. That near the left cavernous sinus had spread into the cavity of the orbit through the sphenoidal fissure. In this orbit another smaller tumour was found at its outer part. Another small tumour was found at the front part of the right orbital cavity. As above stated, the dura mater was adherent to these tumours wherever they made their way through the internal plate, but its lining membrane was everywhere smooth. The superior longitudinal sinus is filled with a firm, pale, non-adherent clot.

Brain.—Decided excess of fluid at base. Convolutions not flattened. In the left hemisphere the pia mater covering the præcuneus, and the anterior part of the occipital lobe (immediately behind the parietal lobule) is dotted all over with minute bright-red spots, and here a vein following along the external parieto-occipital fissure is filled with a pale non-adherent clot. Similar clots are found in a vein running along the fissure of Rolando, and another between the superior and middle frontal convolutions; the hemisphere feels very soft at the præcuneus, and a section here shows a tumour, about the size of a small marble, of purple colour, and surrounded by a patch of softening. On the surface of the right hemisphere the veins corresponding to those enumerated on the left side are found to contain firm, pale, non-adherent clots. The pia mater in the interpeduncular space is thickened and slightly opaque; there are no granulations, and there is no lymph along the course of the Sylvian arteries. The lateral ventricles are dilated, and contain some slightly turbid fluid; the commissures and central ganglia are natural, and the substance of the hemispheres is but little softer than natural. Cerebellum and pons Varolii and medulla natural. Spinal cord not examined.

Thorax.—In the centre of the second piece of the sternum is a slightly raised purple patch the size of a florin. At the corresponding point on the inner surface of the sternum is a similar patch; on section this presents similar characters to those of the

tumours of the skull. Some recent lymph over the surface of the lower lobe of the right lung, a little turbid fluid at this base.

Pleuræ elsewhere natural.

Heart and pericardium natural. Heart weighs weighs 2 oz.

Lungs rather pale, and in places slightly emphysematous. Right lung weighs 6¾ oz. Left lung 5¼ oz.

Bronchial glands not enlarged.

On examining the inner surface of the ribs it is seen that every rib, without exception, on each side has been invaded by the new growth, and they present irregular purple swellings extending from the angle of the rib to its junction with the costal cartilage; in no instance is the periosteum anywhere perforated.

Abdomen.—Alimentary canal not examined.

Liver natural in size and consistence, weight 1 lb. 3 oz.

Spleen natural, weight 1 oz.

Kidneys natural, weight 4½ oz.

Supra-renal bodies natural.

Mesenteric glands natural.

None of the viscera give the lardaceous reaction on being tested with iodine.

In the left lumbar region beneath the supra-renal body is found a greyish white firm mass, the size of a small walnut, having a fibrous aspect on section. In the right iliac fossa, lying against the brim of the pelvis, is found a swollen gland, purple externally, very soft on section, exuding a brick-red juice. In the left iliac fossa, starting from the brim of the pelvis, a chain of lymphatic glands can be traced up to a level with second lumbar vertebra, all swollen, and presenting an appearance similar to that of the gland in the right iliac fossa.

One of the growths in the skull was examined microscopically after being prepared in chromic acid and hydrochloric acid.

The growth was found to consist of small, mostly round cells, embedded in a scanty matrix, springing from the deeper layers of the periosteum and invading the bone.

That the tumour grew from the deeper layer of the periosteum was evident from the fact that bands of fibrous tissue could be seen passing down from the periosteum towards the bone. The lymphatic glands in the groins were found to be invaded by a similar small round-celled growth.

The chief points of interest in this case seem to be the escape of

the thoracic and abdominal viscera from secondary deposits, which are almost always found, according to the text-books; and next, the great extent of the bone lesions, nearly all the cranial bones, all the ribs, and the sternum being involved. *Nov. 25th*, 1879.

Report on Mr. Abercrombie's case of tumours of the vault of the skull, by the Morbid Growths Committee.

The specimen submitted to us for examination consists of the skull cap of a child. From the right parietal bone a large rounded and slightly lobulated tumour projects for about one and a half inch. Its base is about two and a half inches in diameter. On the left parietal bone are two tumours similar in appearance but much smaller, and scattered over the frontal, parietal, and upper part of the occipital bones are numerous smaller growths of the same kind projecting from the surface from one-tenth to one-sixteenth of an inch, in some parts looking like mere thickenings of the periosteum. On peeling of one of the smaller growths from the bone the compact tissue is found to be infiltrated by the tumour. The Haversian canals are enlarged and filled with a substance resembling the tumour to the naked eye. On the inner surface of the skull similar growths are seen between the dura mater and the bone. The largest of these corresponds with the large tumour externally. None of the other tumours seem to have completely perforated the skull. A mass of a similar growth, about one inch in diameter, is situated immediately behind the torcular Herophili, which, with the longitudinal sinus, is filled by a firm clot, evidently of some age. The serous surface of the dura mater was everywhere smooth and healthy. The inner table of the skull is worm eaten, and in parts deeply excavated opposite the growths on the dura mater. At the place where the large external tumour communicates with the corresponding internal growth the bone is not completely destroyed. In the area corresponding to the base of the tumour is a quantity of excessively spongy bone forming a layer much thicker than the normal skull. This is due apparently to partial destruction of the bone and separation of the remaining parts from each other by the growing tumour. The part of the tumour containing the spongy bone can readily be cut with a knife. Around the margin of the growth internally a very small quantity of new bone has been formed, but there seems to be no

true ossification of the tumour substance. All the other parts of the various growths are soft, and no bone can be detected in them by pricking them with a needle. The largest tumour is much blood stained. Sections were taken for microscopic examination.

1. From the large tumour.
2. From one of the smaller tumours on the outer surface of the skull.
3. From one of the growths on the dura mater.
4. From the bone beneath one of the smaller growths.
5. From the blood clot in the torcular Herophili.

The structure of all the growths is practically identical. The fully developed tumour shows, except in very thin parts of the sections, merely masses of round and oval nuclei each a little larger than a red blood corpuscle. The nucleoli cannot be recognised, as the structure is too granular from the effects of the strong spirit in which the specimen has been immersed. In the thinner part of the section it can be seen that the nuclei are surrounded by a small quantity of protoplasm, but it is scarcely possible to distinguish the individual cells from each other. There is but little stroma, and what there is, is arranged so as to enclose such irregular spaces. It nowhere forms a reticulum, nor does it enclose distinct alveoli. In many parts there is abundant extravasation of blood into the structure of the tumour. On the surface of the growth the periosteum is easily to be recognised by its yellow elastic tissu the bundles of which are separated from each other by accumulations of cells exactly resembling those of the fully developed tumour. A similar condition of the dura mater is found internally. A section of the bone beneath one of the smaller external tumours shows the ordinary appearances of infiltration of bone by a malignant tumour. The enlarged Haversian canals are filled with the growth. The blood clot from the sinus was evidently very old. As far as could be seen the tumour had not penetrated the sinus.

From the naked eye and microscopic appearances we therefore conclude that the tumour has originated in the layers of the periosteum and dura mater which lie in contact with the bone, and not from the bone itself. The destruction of the bone is purely secondary, and due to the pressure of the tumour. The elastic layers of the dura mater and periosteum have been stretched over the tumours without being perforated. The tumours from their microscopic appearance must be classed as small, round-celled sar-

comata (granulation sarcoma of Rindfleisch, encephaloid sarcoma of Cornil and Ranvier).

MARCUS BECK.
R. J. GODLEE,

---

6. *Ossifying chondro-sarcoma of both femora, with secondary deposits of a similar new growth in the lungs, in the bronchial, and in some lymphatic glands.*

By ROBERT WILLIAM PARKER.

[With Plate IX].

THE specimens were removed from the body of a child aged twenty months, who was admitted into the East London Children's Hospital, on October 4th, and died November 20th, 1878. She was first seen by me as an out-patient, and was then transferred to the wards. I am indebted to my colleague, Mr. Reeves, for permission to watch and report the case.

Clinical history.—She was quite well until two months before admission, when she slipped down on a board floor and hurt her left knee. A few days later it began to swell, and since that time it has continued to get larger and larger. At first there was no pain, and she was able to get about. It was seen at a London hospital, and diagnosed as a white swelling of the knee-joint.

On admission.—The child was found to be small for its age, pale, and not over well nourished. The anterior fontanelle was still unclosed. Hair very light; grey eyes. The body was spotted over with what appeared to have been varicella.

The left leg was the seat of an ovoid tumour; it involved the lower half of the thigh, the knee-joint, and the upper third of the tibia. The surface of this swelling was not quite uniform; it was firm, even hard to the touch, and the skin over it was marked by several large distended veins. The child winced when the tumour was pressed. Motion in the joint was not entirely abolished.

Neither foot nor leg was œdematous, nor was the skin over these parts in any way altered. There were two or three enlarged inguinal glands. Chest signs all negative. Heart normal as to

sounds. The liver could just be felt below the costo-sternal angle. Spleen was not felt. On making deep pressure on the left side, just above Poupart's ligament, a hard mass was felt, which was thought to be a secondary growth, and which, together with a history that the tumour was growing rapidly, precluded the possibility of any successful surgical interference.

The above notes were taken by Mr. H. R. Hutton, the house surgeon.

During the five weeks which intervened between her admission into the hospital and her death, the child gradually lost flesh, the growth about the left knee visibly enlarged, and the glandular swellings became more manifest. She had one or two accessions of dyspnœa, for which, however, we could not detect any physical signs. About a week before her death the right knee began to swell, it felt hard, and was obviously of the same nature as the swelling of the other limb. The skin over both joints, before death, gradually became tense and shining.

The autopsy was made about twenty-four hours after her death.

The left femur and the upper half of the left tibia were removed after dissecting off the skin. They were surrounded by a large hard mass of new growth, over which the muscles were stretched. The surface of this growth was irregular and nodulated. The bones were sawn through along their vertical axis. The condition which then presented itself is shown in the drawing (Plate IX). The whole length of the femur is affected, except the head and the great trochanter, which are still cartilaginous. The lower end of the bone is, however, the more advanced; here it is very much thickened and sclerosed, and its medullary cavity quite obliterated. Surrounding the shaft of the bone is a mass of new growth, which, as seen from the cut surface, appears to be continuous with the femur itself. This mass of new growth is hard; it consist, for the most part, of cartilage, through which strands of ossifying bone radiate towards the periphery. The amount of bone is greatest in the centre of the growth. Towards the exterior both the bony and cartilaginous elements become less well marked, until only a dense fibrillated structure remains, which gradually passes into the musculature of the thigh. The knee-joint itself does not appear to have been invaded, but its capsular ligament is everywhere closely beset with the new growth. The patella is surrounded and pushed

DESCRIPTION OF PLATE IX.

This plate illustrates Mr. Parker's Case of Ossifying Chondro-sarcoma. (Page 223.)

The new growth is seen to surround the shaft of the femur, the cartilaginous head of the bone and the lower epiphysis alone being free. The central portion, contiguous to the bone, is ossified, and ossifying strands radiate into the growth. The mass of the structure is cartilaginous, except on the surface, which is of a much softer material.

The tibia is in a less advanced condition. The cartilaginous epiphyses of the knee-joint are not attacked, although closely surrounded by the growth.

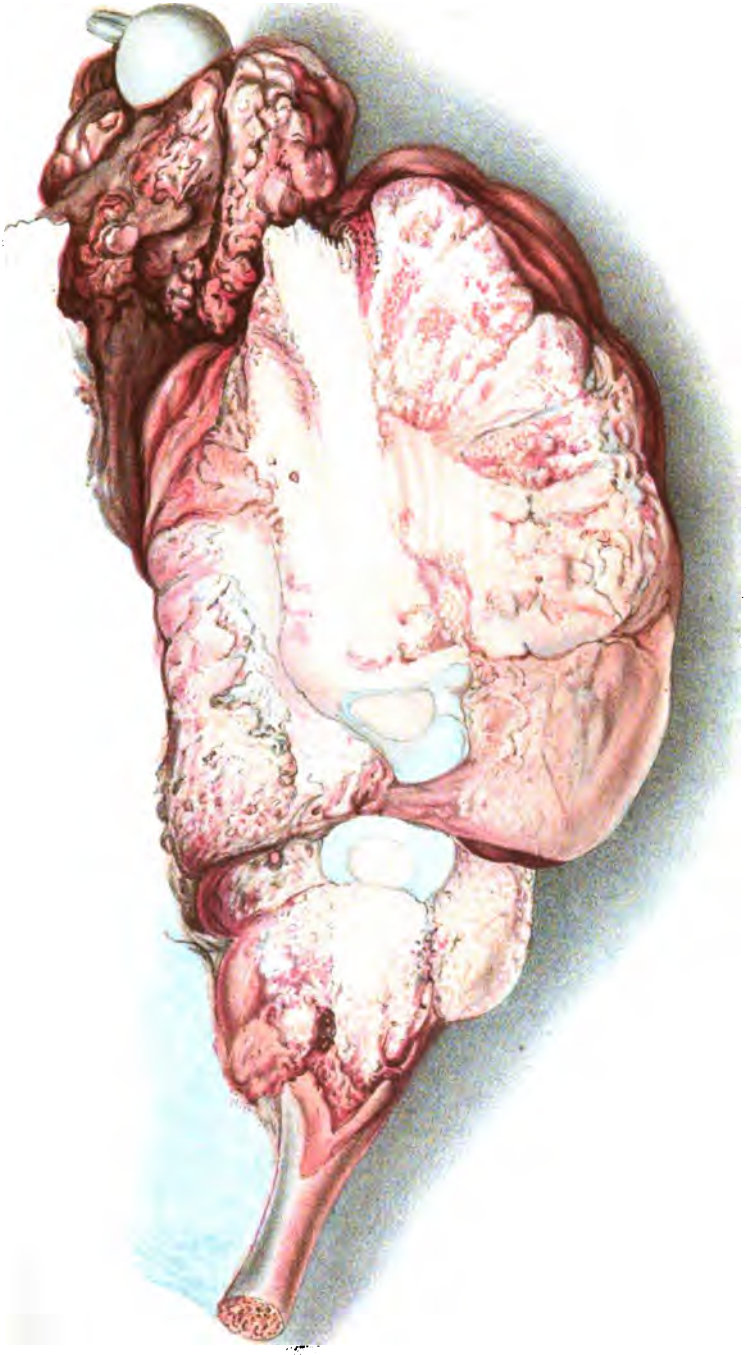

upwards, but has not been attacked. The upper half of the tibia is likewise affected.

The right femur and knee-joint present similar but less advanced conditions. It is interesting as showing how and where the original disease probably commenced, for on examining the left knee at this stage it would be difficult to say how the growth originated, but the clue is afforded by the condition of the right limb. Here we find, that although the periosteum is much thickened, it can, nevertheless, be separated from the bone for a certain distance, at which point it then becomes adherent to, and confluent with, the bone. The medullary cavity, too, gradually becomes obliterated from below upwards. I should believe, therefore, that the growth commenced beneath the periosteum or the perichondrium of the lower end of the femur, and thence spread.

The inguinal glands of both sides were infiltrated with a similar growth, and on the left side a chain of lymphatics along the iliac arteries was likewise greatly enlarged and infiltrated.

The iliac veins were quite free, as also the vena cava inferior. (This fact is interesting in relation to the doctrine generally held, that sarcomata are propagated through the blood rather than by the lymphatic vessels.)

The left lung was patched over with metastatic deposits, similar in structure to that in the thigh, containing portions of bony tissue as well as much calcareous material. The bronchial glands were in a similar condition.

The liver was quite free.

Brain free from deposits.

Ovaries and uterus appeared healthy.

Most of these growths required softening in acidulated water before microscopic sections could be made.

Microscopic examination.—The appearances varied a good deal. In places there was scarcely anything but bone, in others, strands of newly-formed bone were found lying in a matrix of fibrillated cartilage rich in cells. In other places strands of calcareous deposit alternated with collections of large cells, round, or angular, or star-shaped, having moderately thick capsules. The process of ossification was quite irregular, resembling on the whole that in membrane rather than in cartilage. *May 4th*, 1880.

7. *Bone lesions in congenital syphilis.*

By Robert William Parker.

(With Plate X.)

Case 1.—George M—, æt. 7 weeks, admitted into the hospital November 7th; died November 19th, 1879.

The following history was obtained:—The child appeared quite healthy when born, and was "as big again as now." The father was a healthy, steady man, who had never suffered from syphilis. The mother was also healthy, but was subject to "sore throat." She had had four pregnancies—first, a miscarriage; second, a girl aged 5, now healthy and well; third, a child, who died, aged 5 weeks, of "bronchitis;" fourth, the patient. When first seen it was a wasted little thing, constantly pining and crying, and had snuffles badly; there was a muco-purulent catarrhal discharge from the eyes. Its cry was hoarse. There was a papular eruption about its face; its lips were fissured; the mouth inside was healthy; there were some mucous tubercles about the anus; there was no rash on the trunk or limbs; the spleen could not be felt.

The bones.—Both elbows were swollen and nodular from enlargement of the bones. It was difficult to say whether the bones of the forearm were much affected; the lower end of the humerus was chiefly at fault. In the right elbow there was grating, owing to separation of the lower epiphysis of the humerus. The extremities of the ribs were considerably enlarged; the heads of the fibulæ and the lower extremities of the tibiæ also.

There was thickening around the margin of the anterior fontanelle; two small patches of cranio tabes were also detected on the parietal bones.

Under a mercurial treatment the child commenced to improve very fast indeed. The joint swellings diminished very much in size, and the epiphysial grating shortly disappeared entirely. We were then able to appreciate enlargements in the upper extremities of the bones of the forearms, about which we had at first been in some doubt. This, too, gradually subsided. The cry became less hoarse, and the dermatitis passed away. But the child wasted more and

DESCRIPTION OF PLATE X.

Plate X illustrates Mr. Parker's Cases of Syphilitic Bone Lesions. (Page 226.)

FIG. 1.—From Case 2.—Julia B—, æt. 13 years: symmetrical hyperostosis on lower jaw, corresponding with the insertion of the masseter muscles.

FIG. 2.—Left arm of the same patient, showing localised hyperostosis on the radius and ulna.

FIG. 3.—From Case 1—Left humerus: shows the sheath of new bone, which surrounds the lower half of the shaft. There is nothing abnormal along the junction of the shaft with the epiphysis.

FIG. 4.—Right tibia: the whole of the diaphysis is enclosed, as it were, in a sheath of new bone.

FIG. 5.—Left ulna: shows the nodulated condition of the surface of the bone. There was no sheath of new growth, as in the other bones, along the whole of the shaft, but rather a local thickening in two or three different places.

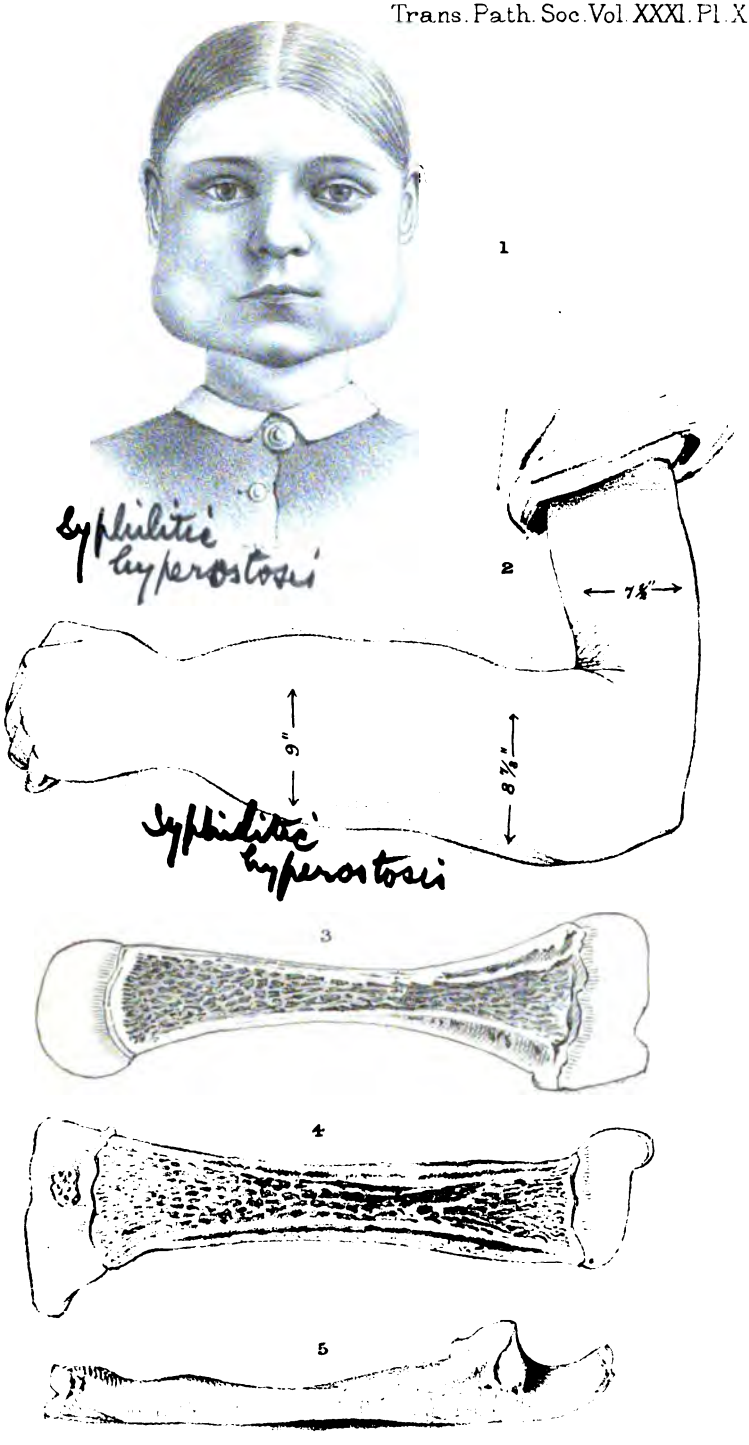

R. W. Parker del.

West, Newman & Co imp.

more, and died of general atrophy, twelve days after its admission.

At the autopsy the lungs, heart, *liver*, and *spleen* were found healthy. The stomach and intestines presented no naked-eye change. The brain was soft and watery.

Bones.—The calvaria: the anterior fontanelle was open; its bony margins slightly thickened; on each parietal bone, above and behind the parietal eminence, there was an irregularly-shaped patch of cranio tabes; the surface of the parietals was elsewhere smooth and normal. The interior of the calvaria likewise presented no abnormal appearance except the cranio tabes just mentioned. The tabetic patches are more or less circular; the margin of the patch is eroded bone; the centre appears to consist only of membrane, as though the salts of the bone had been entirely absorbed. The erosion seems to be the earliest stage of this condition.

Left humerus.—Its lower extremity appeared thickened. On making a vertical section through the bone the epiphysis showed no trace of having been separated from the diaphysis; but between the two there was a lamella, one line thick, of soft, gelatiniform material; this gradually passed into the cancellous bony tissue of the shaft. The medullary cavity was not well marked as a cavity; its place was occupied by a light, spongy, cancellous tissue, containing dark-red marrow (Plate X, fig. 3). The lower half of the shaft appeared as if encased in a sheath of new bone; this is separated from the shaft itself by a narrow cavity, containing marrow enclosed in delicate trabeculæ. The periosteum could be easily separated from the shaft, even over the sheath of the new bone just referred to. The upper extremity was normal. There was no centre of ossification in either epiphysis.

Left ulna.—This bone was stripped of its periosteum without any difficulty; its surface was then seen to be nodulated; this was most marked in its upper third, and at the junction of the middle with the lower third (Plate X, fig. 5).

Left radius.—The upper two thirds of this bone were encased, so to speak, in a shell of new bone, similar to that described on the humerus. The epiphysis appeared as if it had been partially separated from the diaphysis. But this may have been accidental, as there were no evidences of pathological changes between them.

Right femur.—On section it showed that the head and great trochanter were entirely cartilaginous, and together formed the upper

epiphysis; there was no centre of ossification present. Between this epiphysis and the shaft there was a dark line (? inflammatory) of demarcation. The shaft, in its whole length, consisted of a fine, trabeculated, spongy tissue, and contained marrow; there was no medullary cavity, properly so speaking. The line of junction between the shaft and the lower epiphysis was demarcated by a dark line, similar to the upper one; but beyond this there was no pathological condition to note. There was a small ossific centre in the middle of the lower epiphysis, somewhat nearer to its diaphysial than to the synovial surface. The periosteum did not appear thickened, neither was the surface of the bone altered.

Patella.—This was entirely cartilaginous and normal.

Right tibia.—The whole shaft of this bone, by contrast with the other bones, *appeared thickened* (Plate X, fig. 4). On section, that which appears to have been the normal shaft was ensheathed in a layer of new bone; this is particularly obvious on the posterior surface of the bone. On the anterior it is lamellated, as though deposited at intervals. As in the humerus, there is an interval between them, which contained a delicate trabecular structure filled with marrow. In the upper epiphysis there is an ossific centre; none in the lower one.

Right fibula. This was nodulated and thickened, after the manner described above in the ulna.

I was unable to remove any other of the bones, but I examined them as carefully as I was permitted; they did not present any such well-marked changes as were found in the bones just described.

Case 2.—Julia B—, æt. 13, an orphan. Her father died of phthisis, æt. 42; her mother of "chalky rheumatism," æt. 39. An accurate history of the patient during her infancy could not be obtained. Her guardians, however, stated, when she first came under observation, that the girl had enjoyed good health for some years past. She was one of three children; the eldest, a boy, æt. 16, had suffered from similar "lumps," but was now quite well; he was said to have a very large head. The youngest child, a girl, æt. 9, was quite healthy, though very pallid. (These children lived at some distance from London, and it was not possible to get to see them).

The patient herself began to suffer, two months before she came under observation, with an intense aching pain in some of her bones. This was shortly followed by an enlargement of the bone. The en-

largement came on very gradually. She was first seen on October 12th, 1879. At that time there was a marked swelling, of an ovoid shape, over the angle and ramus of the lower jaw on each side (Plate X, fig. 1). They corresponded roughly with the insertion of the masseter muscles. The movements of the jaw were in no way interfered with. These nodes were not painful when handled. The inner third of the left clavicle was the seat of a similar swelling, and others were found on both tibiæ, at the lower end of the left humerus, and on the left radius and ulna (Plate X, fig. 2). The calvaria did not present any appreciable changes. The central incisor teeth were sound and well-shaped. The girl appeared quite healthy and strong, and she presented no other appearances suggestive of congenital syphilis.

She applied at the hospital on account of a constant aching pain in her bones; the pain was not worse at night. In view of a possible, or rather probable, syphilitic origin, mercury and iodide of potassium, alone or in combination, were administered by turns. At the end of three or four months the pain quite disappeared; some of the nodules also disappeared (those on the clavicle and humerus), others diminished in size, while others, again—notably those on the jaws—continued to grow. *December 2nd*, 1879.

Addendum, May 21st, 1880.—The patient has continued under observation since being exhibited to the Society. The bone lesions have continued much in the same condition. If there be any alteration at all the hyperostoses are a little less bulky.

On the other hand, the bones of the right forearm and the right clavicle are beginning to enlarge.

---

8. *Disease of growing ends of shafts of long bones in congenital syphilis.*

By Thomas Barlow, M.D.

No. 1.

This specimen consists of the right radius and ulna taken from a child æt. 4½ months when he died. It will be seen that the lower end of the radius is more bulky than it ought to be, not from any increase in the intervening tissue between the epiphysis and the

growing end of the shaft, like that seen in rickets, but from actual displacement outwards, to a slight extent, of the lower epiphysis. On making a vertical incision through the lower epiphysis and shaft, it is found that just above the junction of the two what may be called the ossiform tissue is quite soft, and that very little effort would be necessary to entirely separate the epiphysis from the shaft. No such change is found at the junction of the upper epiphysis with the shaft of the radius or of the epiphyses of the ulna with its shaft. There is no change of the periosteum in the neighbourhood of the lower end or of the radius, but there is a little roughening of the lower fourth of the back of the ulna.

There is also some thickening of the periosteum and roughening of the front of the middle part of the right tibia.

There were no changes found in the vault of the skull, but at the outer portion of the anterior surface of the left petrous there was thickening of the periosteum and roughening of the surface of the bone, and in this situation there was also some addition of rather soft vascular bone.[1] There was nothing in the antrum of the mastoid or in the tympanum to explain this condition, and I conclude that it must be regarded as a specific osteitis. On the surface of the left hemisphere, and to a slight extent on the right, there was thin, yellowish lymph, and there was some opacity of the membranes at the base. I presume this meningitis was set up by the bone disease. No changes in the arteries were seen. The spleen was enlarged without any notable alteration of its substance. The capsule was much thickened. At the surface of one lung there was a small greyish-yellow mass, semi-gelatinous in consistency, the size of a split pea, which I took to be a gumma.

This child had been brought to the hospital when six weeks old for bad purulent ophthalmia. He was not suspected to be syphilitic until he was two months old. There was at that time a slight rash on the nates, but it was inconclusive, and my belief is, there was a very slight collapse of the root of the nose; but the diagnosis of congenital syphilis was made because of there being then distinct

[1] Congenital syphilitic disease of the bones, forming the basis cranii, must be rare, because M. Parrot in his extensive researches has not found it. But since making the above *post-mortem*, I have examined a skull in a syphilitic infant, aged seven weeks, where there was acute osteitis of the upper surface of the orbital plates of the frontal, and a similar condition on parts of the petrous on the two sides.

splenic enlargement, and very slight swelling and pseudo-paralysis of the right wrist, followed in a week or two by slight displacement of the lower end of the radius and the appearance of a node on the middle of each tibia.

No specific history could be obtained from the father, but it was ascertained that the mother had been a prostitute before her marriage, and no further details seemed required.

No. 2.

This specimen has been obtained by removing the left knee-joint from a male child, æt. 6½ months when he died, and making a vertical section antero-posteriorly. It will be seen that just above the junction of the lower epiphysis of the femur with its shaft there is considerable softening, extending over an area in the section of at least half an inch square.

There is some similar softening, though less in amount, at the junction of the upper epiphysis of the tibia with its shaft.

There is scarcely anything remarkable to define these softened areas from the adjacent structures; they differ scarcely at all in colour, and it is only when the finger is applied that it is found that the earthy material has quite gone, and that they yield to the slightest pressure.

There is no appearance of suppuration, caseation, or granulation; the ossiform tissue seems to have merely become pulpy.

The periosteum over the lower end of the shaft of the femur is thickened a little, but that over the tibia is not altered.

In the joint the synovial fringes certainly appear a little thickened, but that is all one can note abnormal. There had been during life some enlargement of the upper ends of the right radius and ulna, but these were not examined after death.

The other lesions found in this child were remarkable; some of them were syphilitic, some tubercular, and others probably simply inflammatory. On the outside of the skull there were at least five round areas of localised periostitis. They were situated on the frontals, parietals, and temporals, at some distance from the fontanelle. In some of them there was thickening and vascularity of periosteum, which could be detached without difficulty from the bone; in other places the subjacent bone was slightly worm-eaten, and in one spot, viz. above and external to the left orbit, the destruction had been so extensive that, for an area covered by half-

a-crown, the dura mater was exposed and presented a granular surface. Over none of these areas was there any attempt at new bone formation, as in the cranial osteophytes described by M. Parrot. They were, in fact, ulcerating nodes, and in connection with some of them there had been suppuration during life. No change was found in the brain or its membranes.

The liver was enlarged, and showed several small gummata, each the size of a lentil, on the upper surface, and on the under surface one gumma, the size of a hazel-nut, with a vascular zone round it, but strictly defined. No caseation had occurred in any of them. Besides the gummata, there was throughout the liver extensive interlobular infiltration with small cells, as shown under the microscope.

The spleen was not enlarged; there was some adhesion of peritoneum to it and granulations in the adhesions, and in the substance of the spleen were several small caseous nodules, obviously tubercular.

The mediastinal glands were all caseous and softening.

There were some grey granulations on the visceral pleura of the right side, a small pleuritic effusion, with some collapse of the lower lobe of the right lung, and some pericardial effusion becoming flaky.

The history of this case was indubitably syphilitic. The mother has been pregnant nine times. The first six pregnancies resulted in two miscarriages at four months, and in four children born dead. The first living child had the most severe syphilitic manifestations of skin that I ever saw in a child. He recovered, extensively scarred. After treating him, I found that the father was suffering from periostitis of the nasal bones, and there was a history of genital sore. Both parents were now put under a course of iodide of potassium, and the mother was also very slightly salivated by mercury. The child from whom this specimen is taken was born afterwards, and for three months was an exceedingly healthy child. Then a slight, though typical, squamous rash appeared on the trunk and genitals, and when he was five months old the lumps appeared on the head, which proved afterwards to be due to ulcerating nodes with some pus under the periosteum. Within a fortnight of the appearance of the lumps on the head, there was slight enlargement above the left knee, with unwillingness to move it; and in another fortnight there was enlargement at the upper ends of the right radius and ulna. The signs of pleurisy appeared

a day or two before the child's death. The supervention of tuberculosis had not been suspected. I have found such a condition in at least two other syphilitic infants on *post-mortem* examination.

Remarks.—This disease was well illustrated in M. Parrot's address given before this Society last year, and specimens of long bones so affected had been previously shown to the Society by Mr. Haward and Dr. Goodhart ('Path. Trans.,' vol. xxviii).

I shall not discuss the different renderings of the morbid process by Dr. Wegner as an osteochondritis, and by M. Parrot as a gelatiniform transformation. The points to which I wish to draw attention are that—(1) with regard to nomenclature, the disease is not in any sense an "epiphysitis," but a change at the growing end of the shaft; (2) that although it may be associated with periostitis, or with the formation of subperiosteal osteophytes, it may exist also quite apart from those conditions, that the change is strictly endosteal, and that the term "perichondritis," which has been applied, is not a correct one; (3) that clinically, the disease appears often to resolve completely, but that where separation of the epiphysis, partial or complete, occurs, it does not result, so far as I have seen, from actual suppuration in the softened zone, although suppuration in the structures surrounding the end of the bone is occasionally seen.[1] *December 2nd*, 1879.

---

9. *Case of disease of the bones in a fœtus, presumably syphilitic.*

By F. S. Eve.

The fœtus from which the bones were taken was aborted at the fifth or sixth month of pregnancy from a woman, æt. 31, at the time in St. Bartholomew's Hospital.

The evidence of syphilis is not conclusive, and is derived from the circumstances of the case taken together rather than on the condition and history of the mother. It rests on the following facts:—That the fœtus was aborted, the abortion occurring before the commencement of the treatment of the case; the changes in the bones

[1] Mr. Haward's case also supports this statement.

of the fœtus, which correspond to those described independently by Parrot[1] and Wegner[2] as due to congenital syphilis; and the uncertain, but to some extent corroborative evidence of syphilis suggested by the presence of a stricture of the rectum in the mother.

The stricture was annular, two and a half inches from the anus, and the symptoms of rectal disease had existed for three years; at the earlier part of that period she passed for a considerable time blood and slime with her motions, no doubt owing to ulceration of the rectum.

No history of syphilis could be obtained on questioning the mother. She had borne, she stated, two healthy children, but seven years had elapsed since the birth of the last child.

She left the hospital apparently cured, but has now a recurrence of the stricture, with the passage of blood and slime per anum, a year having passed since her discharge from the hospital.[3]

I have not been able to see the father of the child, who is an engineer in the docks.

The following changes were observed in the bones of the fœtus:

The bones of the skull showed a thin, porous deposit of bone along the margins on the outer table, especially around the anterior fontanelle, along the frontal and coronal sutures, and in the temporal fossa.

Both epiphyses of the femora and tibiæ, the lower epiphyses of the humeri, and the upper epiphyses of the ulnæ were separated from the diaphyses. The epiphyses were connected with the diaphyses by the thickened periosteum, and the interval between them contained a dirty, grumous detritus. The surrounding periosteum was discoloured, and in several instances separated for some distance from the extremity of the diaphysis, the bone beneath being rugged from absorption, as if carious.

On section, the extremities of the diaphyses were found to be soft and infiltrated with a yellowish-brown material.

The connection between the other epiphyses and diaphyses was loosened, and the extremities of the diaphyses were softened.

The left tibia and fibula were much thickened by the deposit of soft, chalky bone on the surface of the shafts. On the tibia the

[1] 'Archives de Physiologie,' tome iv, p. 319.

[2] 'Virchow's Archiv,' 1870.

[3] The above facts were ascertained after the communication of the case to the Society.

thickening was greatest at the centre of the shaft, producing a large nodular projection.

There was no apparent deposit of bone on the surface of any of the other long bones, except on the posterior surfaces and lower extremities of the humeri.

Microscopic appearances.—The following changes were observed at the extremities of the bones, the epiphyses of which had not actually separated (see fig. 1):

The epiphysial cartilage was normal.

The intermediary cartilage did not appear greatly changed, except that the continuity between the vertical lamellæ of calcified cartilage and the vertical lamellæ of bone appeared to be broken, probably owing to the delayed or deficient deposition of bone on the surface of the calcified cartilage. The spaces were choked with granular marrow substance, especially those between the lamellæ of calcified cartilage. The marrow was more granular, and apparently breaking down at the extremities of those bones, the epiphyses of which had separated.

The lamellæ of bone at the extremity of the diaphyses were thin, and presented distinct evidence of unusual absorption in the very large number of Howship's lacunæ containing osteoclasts, seen on their extremities and sides (see fig. 2).

The separation between the epiphyses and diaphyses appeared to take place at the junction of the intermediary cartilage with the bone lamellæ—that is, at the line where ossification normally takes place. The intermediary cartilage, in cutting sections, also separated from the epiphysial cartilage, thus becoming detached.

The periosteum was much thickened, especially at the junction of the epiphyses with the diaphyses. Beneath it there was a thick layer of fibrillar tissue, which in places showed patches of imperfect ossification (see fig. 1).

Transverse sections through the centre of the shaft of the fibula affected with the osteoid change (Parrot) showed that the enlargement was due to the formation of lamellæ of bone on the surface of the shaft, which formed a network, the meshes of which were elongated and vertical to the surface of the bone (see fig. 3). The ossification was very irregular and incomplete, the lacunæ in which the bone-corpuscles lay being extremely large, and in places many of them were united to form spaces.

Remarks.—The morbid changes in the bones appear to me to be

due to a hyperplasia of the elements out of which the osseous tissue is formed, with a deficient power of organisation and deficient deposit of bone-salts.

The process has a different result in the different situations at which ossification takes place.

At the extremity of the diaphyses there is a marked arrest of development of new bone, and a tendency to breaking down of the newly-formed marrow; while on the surface of the shafts the redundant fibrillar tissue formed beneath the periosteum is frequently converted into bone, and produces the thickening shown in the tibia and fibula described.

The difference probably depends on the different forms of ossification in each case, and probably also on the more abundant blood-supply to the periosteum.

---

10. *Cranio-tabes associated with congenital syphilitic disease of parietal bone.*

By Thomas Barlow, M.D.

This specimen is the left parietal bone of a female syphilitic child aged eleven months when she died. The child was under the care of my friend Dr. Sansom, to whom I am indebted for the specimen. It will be seen that at least three quarters of the outer surface is invaded by a finely granular deposit, which forms a band of decided thickening, two inches broad, parallel to the interparietal suture, and extending up to it. On the other parts of the outer surface, the deposit, though definite enough, is thin, and forms a band varying in breadth from half an inch to an inch, reckoning from the margin.

Everywhere the morbid bone is of a dull brownish-purple colour. The only part of the outer plate not invaded is the parietal eminence; there the surface is smooth and the colour normal.

The inner plate shows many smooth conical pits, but near the lower margin are two spots, where excavation has taken place to such an extent that the bone is reduced almost to a membrane.

It is to be observed, however, that the outer surface of the outer

table is over these spots quite continuous and complete. I wish also to point out that the whole bone is exceedingly flexible, and yields in quite a remarkable way to pressure. This applies to the thickened as well as to the thinned portions.

I have brought this specimen along with others illustrating the lesion of cranio tabes in syphilitic skulls, especially for the purpose of showing how it differs from Mr. Parker's specimen shown this evening, in which also there are perforations. Mr. Parker's specimen is an example of M. Parrot's atrophic form of congenital syphilitic skull, where, according to his nomenclature, there has been gelatiniform transformation of bone and disintegration of its substance. The perforations in Mr. Parker's specimen are different in position from those of cranio-tabes, inasmuch as they are near the upper margins of the parietals instead of near the lower posterior angles; but the important difference is that the loss of substance is in the outer table, and that it extends inwards instead of being in the inner table extending outwards.

In a recent paper by M. Parrot, in the 'Revue Mensuelle,' the subject of cranio-tabes is very exhaustively discussed, and this specimen illustrates very well some of the points in the etiology of the lesion, which M. Parrot sets forth. For the production of cranio tabes there would seem to be three factors—(1) bone inordinately soft and yielding; (2) the pressure of the brain on the inner surface; (3) some resisting body on the outer side against which the head lies.

Syphilitic bone in the infant is inordinately soft and yielding, as this specimen shows, even where there is thickening from new deposit. A syphilitic child is often a weakly child, and lies with its head back on the nurse's arm. Obliquity of the skull from flattening of the posterior part of one or other parietal is undoubtedly commoner in syphilitic than in non-syphilitic children, and it is impossible to resist the conviction that such flattening is often due to outside pressure on unduly soft bone.

The pits on the inner table which, carried to the extreme, give rise to the spots of cranio tabes, would appear in this specimen to correspond very well with what might be effected by the pressure of convolutions.

M. Parrot has been the first to describe the rare occurrence of cranio-tabes as a fœtal condition. All his specimens of this kind were from premature stillborn children, and so far presumably

syphilitic. It is important to note that in these cases the spots of cranio-tabes were not posterior, as in the ordinary cases, but in the frontals and anterior part of the parietals, in fact, around the fontanelle.

M. Parrot points out that in the ordinary position of the fœtus *in utero* downward pressure would tell more in this part of the skull than elsewhere. *December 2nd*, 1879.

---

11. *Two cases of disease of the skull-cap.*

By Norman Moore, M.D.

Case 1. Skull-cap of a female child, æt. 7, who died in St. Bartholomew's Hospital, in one of Dr. Gee's wards, of tubercular meningitis.

The inner surface of the skull-cap is irregular, rough, and thickened in parts. The thickening is greatest on the inner surface of the parietal bones, but it is also considerable on the upper part of the frontal bone, along the middle line, and on the upper part of the occipital bone.

On the right side there is a depression, of the size of a shilling, on the coronal suture, and a similar but somewhat smaller depression exists on the left side on the same suture, but a little nearer the middle line. The outside of the skull and the dura mater showed no morbid appearances.

The incisors were deeply notched. No scars were found, nor other evidence of syphilis. The frontal eminences were prominent, but no other bones gave any indication of rickets. The chest was of normal proportions. The right lobe of the cerebellum contained a caseous mass, the size of a walnut, under the microscope, merely structureless and granular. On the convexity, and about the Sylvian fissure, were numerous tubercles, and there was lymph around the nerves at origin, and abundant ventricular and subarachnoid effusion. Two bronchial glands were caseous, and the others contained fresh tubercle. Both lungs contained groups of recent tubercle.

There was no tubercle on the peritoneum. On both sides of the

ileo-cæcal valve were small ulcers, but they were not distinctly tuberculous.

On the anterior wall of the œsophagus were two rounded scars as of old ulceration. Thus, the child's body gave evidence of scrofulous disease in the cerebellum, bronchial glands, and intestine, and of syphilis in the teeth, and perhaps in the œsophageal scars. Such scars I have noticed twice in children, but I am not prepared to assert that they are syphilitic. The child had smallpox at one year of age, and they may have been due to that disease. Whether the skull disease is syphilitic or scrofulous is, perhaps, open to dispute.

Case 2.—Skull-cap of a female child, æt. 6, who died in St. Bartholomew's Hospital, in one of Dr. Andrew's wards, of ulceration of the intestines, with amyloid disease of liver and spleen and kidneys.

The skull-cap is somewhat thick at the centres of the parietal bones, and its inner surface shows numerous pencilled, dendriform patches of grooves, which give the surface a worm-eaten appearance. These patches vary from the size of a silver penny to that of a sixpenny piece. On the dura mater there were corresponding villous patches.

The incisors were notched. I could find no distinct scars, but the puckering around the anus was greater than normal. The lungs, mesenteric and lumbar glands contained caseous masses. The intestines were extensively ulcerated; the ulcers with tubercle at base.

I do not feel clear that this is a case of syphilitic disease of the skull-cap, but it is, I think, diseased. The visceral lesions would point to scrofula. *December 2nd*, 1879.

12. *Dislocation of the external semilunar fibro-cartilage of the knee-joint.*

By RICKMAN J. GODLEE.

[With Plate XI.]

IN opening an old knee-joint that had remained for years amongst the stock of anatomical treasures at University College, my friend, Professor Thane, noticed that the external semilunar fibro-cartilage was displaced. The specimen was exhibited to the Society, and a drawing of it will be found on Plate XI. It will be seen that the condition of things is quite unmistakable. The circumference of the fibro-cartilage has been torn away from its attachment to the capsule of the joint, and it now occupies a vertical position in the intercondyloid fossa. The displacement must have occurred some time before the death of the individual, for the fibro-cartilage remains stiffly in its present position, and appears to have somewhat shrunk from its natural size; it is also obviously flattened by the pressure of the inner part of the condyle. At the same time the inner surface of the capsule is smooth, and it will be observed that the cartilages on the femur and tibia show no signs of alteration, except a little change due to chronic rheumatic arthritis, which, it should be observed, occurs at a point on the tibia which, under ordinary circumstances, would have been protected from friction by the semilunar cartilage.

I am not aware that any specimen of this dislocation is to be found in any of our London museums, although a considerable number of cases have been placed on record, as, indeed, one might have been led to expect from the fact that in most instances a complete recovery appears to have been made; many, very likely, going about with the fibro-cartilage in the same position as that in my preparation, others, probably, after obtaining a complete reduction.

Mr. Hay was the first to draw attention to this class of injuries, under the term of *internal derangement of the knee* ('Pract. Obs.,' p. 332, 2nd ed.), but he does not appear to have arrived at any definite notion of the actual injury that occurred. The subject is more or less lightly treated upon in Sir A. Cooper's lectures, and

DESCRIPTION OF PLATE XI.

This Plate illustrates Mr. Godlee's Case of Dislocation of External Semilunar Cartilage. From a drawing by himself. (Page 240.)

a. External semilunar cartilage, occupying a vertical position in the intercondylar notch.

b. Outer part of capsule, from which the cartilage has been torn.

c, c, c. Patches of erosion from chronic rheumatic arthritis on the condyles of femur.

d. Patches of erosion from chronic rheumatic arthritis on that part of the tibia on which the semilunar cartilage originally lay.

e. Internal semilunar cartilage in the natural position.

f. Transverse ligament.

g. Tendon of popliteus muscle.

h. Anterior crucial ligament.

k. Posterior crucial ligament.

l. Infra-patellar mass of fat.

m. Tendon of triceps extensor cruris.

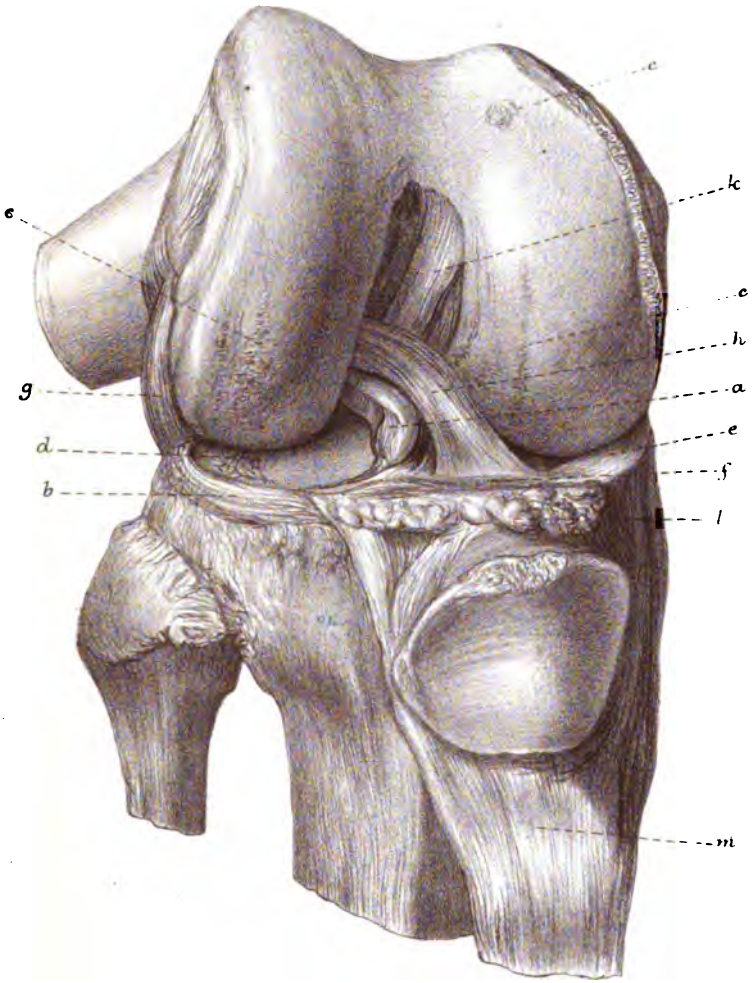

R.J.G. del. E. Burgess lith.

West, Newman & Co. imp

by more modern authors, Erichsen, Holmes, &c.; but the best account is to be found in 'Cooper's Surgical Dictionary,' under the heading "Dislocations." It is there pointed out that, whilst the older observers noticed no deformity whatever, except that Mr. Hay observed a slight relaxation of the ligamentum patellæ, in some of the later recorded cases a projection has been noticed, and almost invariably on the *inner* side of the knee. In *one* case the projection seems to have been at the outer, and in another at the inner and posterior part of the knee which latter must have represented a different kind of accident from that shown in my preparation. If the cartilage should assume the position which it does in this case, the only possible deformity which could occur would be a slight projection at one side or other of the ligamentum patellæ, caused, in all probability, not by the cartilage itself, but by the fat in the alar ligament pushed forward by the cartilage. There would, perhaps, be a depression corresponding to the place from which the cartilage had slipped. Such a condition of things existed in a case recorded by Mr. R. Clement Lucas ('Brit. Med. Jour.,' 1879, p. 744), which, I imagine, must have been of nearly the same nature as my case.

Looked at from an anatomical point of view it would seem most likely that the external and not the internal fibro-cartilage should be the one to slip, for it will be remembered that the cartilages are retained in position chiefly by means of their attachment to the capsular ligament of the joint. Now the shape of the external cartilage being that of a large segment of a small circle, as compared with that of the internal, which forms a small segment of a larger circle it follows that the anterior and posterior extremities of the external reach a position near the centre of the joint, being attached, in fact, immediately in front of and behind the two pieces of the spine on the upper surface of the tibia. The external cartilage has thus a much less extensive attachment to the capsule of the joint than the internal, and is, consequently, much more movable. The sheath of the tendon of the popliteus again communicates, often in two places, with the capsule of the joint beneath the external semilunar cartilage, that communication which is constantly found being to the outer side, that which occasionally occurs, at the back of the joint. This greatly diminishes the extent to which the cartilage is attached to the capsule. It is also possible that this cartilage is liable to irregular movements from the fact that the ten-

don of the popliteus muscle has a not inconsiderable attachment to it. But be this as it may be, it appears actually to be the internal which most usually suffers displacement, that is, if we are to accept all recorded cases as authenticated, a position I should be very sorry to occupy, when it is remembered how readily loose cartilages in joints, strains, &c., may be mistaken for this, not easily diagnosable, condition.

How the accident occurs is very much a matter of conjecture. The most common form of injury appears to have been a blow upon the toes when turned outwards, or a twist inwards of the foot, but it is probably produced in a number of different ways. I would merely point out how comparatively free is the movement of the tibia laterally over the condyles of the femur when the joint is flexed, especially in loose-jointed people, and that this movement of the tibia is more free towards the inner than towards the outer side. Of course, the cartilages move with the tibia, and it seems to me quite comprehensible that when the external cartilage is drawn already well towards the inner part of the outer condyle of the femur, a sudden jerk or twist might force it still further and cause it to pass actually outside the circumference of the cartilage, *i.e.* either in front of or behind it. This would be very likely to rupture the attachment of the capsule and to drive the cartilage into the position we have seen it occupying.

February 17*th*, 1880.

---

13. *Diseased jaw-bone from case of cancrum oris.*

By W. Harrison Cripps, F.R.C.S.

The patient, from whom the lower jaw was taken, was a boy, æt. 3, who had enjoyed good health until a few days previous to his admission to St. Bartholomew's Hospital. The parents stated that the child was in the habit of playing with a favourite cat, which, just before the disease broke out, had to be killed, on account of the face becoming greatly swollen, and a fetid discharge from the nose. On admission to the hospital, the left side of the lower jaw was swollen, the swelling being so hard and circumscribed as to suggest the idea of a sarcomatous tumour. In a couple of days the swelling had extended further forward, and was superficially ulcer-

ated. The discharge from the mouth became very fetid. During the next fortnight the disease slowly progressed until the whole aveolar margin of the lower jaw was swollen, and several of the teeth had dropped out.

For a few days the disease made no further progress. It then showed signs of attacking the left side of the upper jaw. A large, hard, brawny swelling formed on the outer side of the face over the angle of the jaw. A week later this commenced to slough, the sloughing action at the same time attacked the whole of the lower jaw and the right side of the upper jaw. So virulent was this sloughing that in forty-eight hours the whole of the parts were converted into a soft, creamy mass, as if the parts had been mixed with some virulent acid. The child rapidly died. At the *post mortem* examination the parts were so soft that they could be wiped away with a cloth, with the exception of the remains of the lower jaw. From this all the teeth had dropped out, and it had a worm-eaten appearance, large cavities being formed in places. The bone had partly succumbed to the corroding action of the disease, and probably had the child lived a little longer it would have been totally destroyed. *April 20th*, 1880.

---

14. *Ostitis (with ulceration) of skull; gummatous infiltration of dura mater; cerebral endarteritis; gummata in spleen and lung (?); fibroid testes. From a case of syphilis. (Card specimen.)*

Exhibited by S. Coupland, M.D.

From a man, æt. 46, who contracted syphilis twenty years before his death. Twelve months before death attacked with left hemiplegia, which appears to have improved, with the exception of the facial palsy on the same side. This even increased and was very marked, when he was admitted into the Middlesex Hospital, under Mr. Lawson's care, on October 3rd, 1879; at the same time there was deafness on the left side, and marked hyperæsthesia of skin of this side of face. He died six weeks after admission.

The *calvaria* is uneven, irregularly thickened on external surface, and on left parietal region presents a loss of substance of whole thickness. The inner table has a spongy, porous aspect, and was extremely vascular when recent.

Dura mater thick and opaque, adherent to left lateral lobe of cerebellum by syphilomatous new growth.

The main arteries at base of brain, all apparently the seat of endarteritic change; the left anterior cerebral, middle cerebrals, and posterior cerebral, are all plugged by recent clot. (No softening of cerebrum.)

Caseous nodules in upper lobe of right *lung*:—syphilomata (?).

Spleen.—Small yellow nodules; diffuse infiltration extending from a yellow mass in hilus.

Right testis slightly, *left testis* markedly, "fibrous."

January 6th, 1880.

15. *Cranial bosses.* (*Card specimen.*)

Exhibited by J. ABERCROMBIE, M.D.

THE skull is that of a female child, æt. 20 months. On the frontal bones are two large rounded bosses, greatly raised, having a diameter of about two inches; their margin is well defined everywhere, except posteriorly, where they run into bosses on the parietal bones, bridging over the coronal suture; this is much more marked on the right side.

Both parietal bones, but especially the left, are extensively invaded by bosses, the upper portions near the sagittal suture and the parietal eminences alone escaping.

When fresh these bosses were of a dull crimson colour, and presented numerous minute purple spots and streaks; they were soft and easily indented by the nail.

The pericranium was not adherent over the bosses. The anterior fontanelle is very widely open, and lozenge-shaped, measuring three inches from before backwards and two inches across.

The history of the case is very incomplete, as the mother died the day before the child was seen. She had had three other children, and was said not to have had any miscarriages. The child had a flattened bridge to its nose.

At the *post-mortem* the spleen weighed less than half an ounce, but was very firm. The child died of diphtheria.

May 4th, 1880.

16. *A united fracture of right ulna from a case of locomotor ataxy.* (*Card specimen.*)

Exhibited by W. B. HADDEN, M.D.

THE fracture is at the junction of its middle and lower third.

There is considerable thickening around the seat of fracture.

The patient was under the care of Professor Charcot.

No history was given with the specimen, which is preserved in the museum of St. Thomas's Hospital.

February 17*th*, 1880.

17. *Lower extremity of a right femur from a case of locomotor ataxy.* (*Card specimen.*)

Exhibited by W. B. HADDEN, M.D.

THERE is considerable reduction in the diameter of both condyles, the cartilage is removed, and the surface eburnated.

Some new bone has been formed, chiefly around the margin of the joint.

The patient was under the care of Professor Charcot.

No history was given with the specimen, which is preserved in the museum of St. Thomas's Hospital.

February 17*th*, 1880.

18. *A Dislocation upwards of the acromial end of clavicle with fracture of clavicle.* (*Card specimen.*)

Exhibited by FREDERIC S. EVE.

THE ligamentous connections between the clavicle and acromion are almost completely torn through.

There is a transverse fracture at the junction of the inner with the outer two thirds of the clavicle; the periosteum covering the superior and inner surfaces of the bone is intact.

From a man, æt. 35, who fell from a scaffold, a height of fifteen feet.

The acromial end of the clavicle projected upwards, and there was

so much separation that a finger could be inserted between it and the acromion.

Death took place from injuries to the head.

January 6th, 1880.

19. *Ostitis of right os calcis or combined periostitis and osteomyelitis (scrofulous.) (Card specimen.)*

Exhibited by WALTER RIVINGTON.

FAMILY history. Father and one child died of phthisis. Patient and other members of family suffer from winter cough.

This bone was removed this afternoon from a lad, æt. 15, who had been admitted into the London Hospital at the beginning of October, suffering from supposed rheumatism. Abscesses formed over the right radius and right os calcis. He was transferred from the medical to the surgical side of the house. He had some basic pneumonia, more extensive on the right side. The radius in the greater part of its length and os calcis were found to be bare of periosteum. After some days' rest the opening over the radius ceased to discharge and has closed, but the foot continued to discharge very freely, and the pus was offensive. As the discharge appeared to be exhausting the patient, and the presence of the bone to be detrimental to the lungs, the os calcis was removed. Section shows that the posterior part of the cancellous tissue is infiltrated with yellowish caseous-looking material, and that the nutrition of the epiphysis and articular cartilages on the upper surface has been interfered with. The anterior portion of the bone being comparatively healthy, the cartilage for articulation with the cuboid is sound. The yellow matter has not yet been submitted to microscopic examination. The posterior epiphysis is separated, being adherent only by the periosteum on the under surface of the bone.

The patient made an excellent recovery.

November 4th, 1879.

20. *Caries of spine producing aortic deformity and probable obstruction. (Card specimen.)*

Exhibited by ARTHUR E. BARKER.

THE specimen illustrates the effects of angular spinal curvature on the aorta, and the production in the latter of abrupt knuckling and folds projecting from its posterior wall into its lumen. This deformity of the vessel has been pointed out by Dr. Hilton Fagge as a probable cause of obstruction and consequent hyper-

trophy and other disease of the heart (*vide* 'Guy's Hosp. Reports,' vol. xix, p. 199). The specimen shows that the aorta is tied into the angle by the intercostal vessels. There was no cardiac hypertrophy.

The immediate cause of death was pneumonia and pleurisy, set up by the pus from the spine making its way to the pleura and invading it and the lung, a cause I have seen operate in two cases, though it must be rather rare. *October 21st*, 1879.

21. *Excision of knee-joint, bone twelve years afterwards.* (*Card specimen.*)

Exhibited by HENRY A. LEDIARD, M.D.

THIS specimen was taken from a man, æt. 29, who died in the Cleveland Street Sick Asylum, from caries of the lumbar vertebræ and kidney disease, on the 25th January, 1880. Twelve years previously the left knee-joint had been excised by Sir William Fergusson in King's College Hospital. The patient was a cab-driver, and had enjoyed good health for ten years after the operation, with great strength in the limb, which was shortened to some four or five inches. The preparation shows so solid and compact a bony union, that it is impossible to make out the exact seat of the operation.

There is osseous ankylosis of the head of the fibula.

April 6th, 1880.

22. *Dislocation of the hip-joint from disease.* (*Card specimen.*)

Exhibited by HENRY A. LEDIARD, M.D.

THIS specimen was taken from a youth, æt. 19, who had suffered from hip disease, as well as necrosis elsewhere, for several years—the bone disease following rheumatic fever.

The patient came under my care during the last few months of his life only, and suffered severely from general waxy degeneration

In this instance there has been disease of the head of the femur and destruction of a portion of it, as well as ulceration and absorption of the margins of the acetabulum.

A mass of carious bone projects into the upper part of the acetabulum, and upon this mass, as well as the upper rim of the acetabulum, the head of the bone has formed a new socket, to which it is united by fibrous tissue, not far from the anterior inferior spine.

There are two or more large osseous fistulæ in the acetabulum.

Although neither of these specimens show as clear a displacement as is met with in traumatic dislocations of this joint, still the head of the bone has escaped, more or less, from the acetabulum. I hold, therefore, that "dislocation from disease" is no misnomer, for, whether the dislocation results from disease of the head of the bone, or carious enlargement and absorption of the acetabular rim matters very little, the effect upon the limb is much the same. Again, as to the capsule of the joint, in these cases it would have been very difficult, if not impossible, to recognise whether any existed at all, so thickened, matted, and altered were the soft parts around the joint.

December 16*th*, 1879.

23. *Dislocation of the hip-joint from disease.* (*Card specimen.*)

Exhibited by HENRY A. LEDIARD, M.D.

THIS specimen was removed from a boy, æt. 14, who had suffered from hip disease for many years, and died from waxy degeneration of the internal organs. The limb was shortened and thrown across its fellow. The head of the bone is seen lying above the normal limit of the acetabulum, and rests upon some heaped-up bone on the dorsum of the ilium, near the sciatic notch. There is extensive disease of the acetabulum, with perforation and carious enlargement, and the head of the femur, though altered in shape, is not much diminished in size; it seems, therefore, that dislocation has resulted more from breaking down of the margin of the acetabulum than from disease of the head of the bone.

There is great thickening of the ilium.

The ankylosis of the head of the femur and the ilium is fibrous only. The epiphyses of innominate bone are ununited.

December 16*th*, 1879.

24. *Osteitis of the ulna in connection with inherited syphilis.* (*Card specimen.*)

Exhibited by JONATHAN HUTCHINSON.

THIS portrait was exhibited in order to illustrate a condition not unfrequently assumed when a node ulcerates. The bone exposed having been previously indurated by chronic osteitis is very slow to exfoliate and remains exposed, it may be for years, at the bottom of the ulcer. Partly from this long exposure, and partly from its roughened surface, the bone is very apt to become blackened. These conditions were well shown in the portrait, which

was from the arm of a girl, the subject of inherited taint who had many other nodes. This one had been open for more than a year, and the exposed bone remained firmly fixed. In the end it became loose and a large discoloured fragment was removed. This peculiar result of osteitis occurs both in inherited and acquired syphilis, but its best examples are seen in the inherited disease (see Case 27).

May 4th, 1880.

25. *Living subject showing dwarfing of the tibia following detachment of its lower epiphysis.* (*Card specimen.*)

Exhibited by JONATHAN HUTCHINSON.

THE subject of this case was a girl, æt. 14, who received a severe injury to her ankle nearly five years ago. The result has been that the lower end of the tibia is now imperfectly developed, being both too slender and too short. By the continued growth of the fibula the foot has been pushed over to the inner side. The fibula is now relatively to the tibia more than an inch too long. The tibia is also shorter than that of the other limb.

The accident consisted in a fall in a garden upon some pieces of wood. The foot was so much injured that the patient was confined to bed many weeks. Unfortunately the surgeon who attended her has since died, so that no evidence is obtainable as to the precise nature of the injury as diagnosed at the time. That there was a separation of the lower epiphysis with considerable displacement is rendered almost certain by the presence of a transverse ledge which crosses the tibia about two thirds of an inch above the tip of the inner maleolus. The lower part of the fibula is not only too long but appears to be thickened, but no distinct ridges, as if the results of fracture, can be traced.

I have never before happened to see this condition at the ankle-joint, but repeatedly at other articulations.

A *lithograph* taken from the Society's 'Transactions,' vol. xiii, was also shown in order to illustrate a precisely similar condition of things in the ulna and radius.

Also a drawing showing the same state from another case; a section of the bones of the carpus and forearm having been made to show their relative positions.

[A plaster cast of the girl's foot has been deposited in the museum of the Royal College of Surgeons.]

November 19th, 1879.

26. *Large recurrent enchondroma of the upper jaw.* (*Card specimen; two photographs and tumour.*)

Exhibited by JONATHAN HUTCHINSON, for J. H. KEELING, M.D. (of Sheffield).

PHOTO. 1—showing the state a year after the growth began. Eyeball displaced upwards.

Photo. 2—showing the state more than two years after the first operation, and just before the second.

The tumour began to grow in 1876. In July, 1877, it was removed by an incision from the floor of the orbit. In October, 1879, it had attained a large size and occluded both nostrils, and bulged the palate downwards. The upper jaw was now removed, and the tumour taken away in fragments.

The tumour was a nodular enchondroma with but little tendency to ossfication. It had grown into all the adjacent cavities, displacing and expanding the bones. It did not appear to have any bony capsule of its own, but wherever it came into contact with bone adhesions had formed. The bones, which had been expanded and thinned, were not disintegrated. Thus, it would have been quite possible to have avoided removal of the palate and alveolus, which were not really involved in the disease.

The part from which the tumour took its origin is not clear. It may possibly be yet further back than the parts removed (sphenoid bone ?). On the other hand, the early displacement of the eyeball by pressure from below would suggest that it began in the antrum.

It is feared that the removal is not yet quite complete.

November 4th, 1879.

27. *Chronic osteitis in connection with inherited syphilis.* (*Card specimen; part of a fibula which had been excised*).

Exhibited by JONATHAN HUTCHINSON.

THE subject of the case was a girl of thirteen, in whom many bones were affected. Her teeth and physiognomy were characteristic, and there was a complete history.

The fibula was greatly enlarged, and in consequence of suppurative periostitis a portion was exposed, rough and discoloured.

As the exposed portion did not become loose it was decided to excise the affected part. The periosteum was detached and the shaft of the bone cut through above and below the seat of the disease. The bone as shown was seen to be much enlarged and indurated, and its medullary canal almost obliterated. Its surface

was very rough. The outline of the portion which had been exposed in the ulcer could easily be distinguished, and although its boundaries could be traced in the section, there was no progress towards its separation.

The specimen was shown in order to demonstrate the tendency to general hypertrophy and induration of bone in congenital syphilis, and also the extreme slowness with which separation of fragments exposed by suppurative periostitis occurs (see Case 24).

December 16*th*, 1879.

VII. DISEASES, ETC., OF ORGANS OF SPECIAL SENSE.

1. *Optic nerve from a case of optic neuritis with good sight.* (*Card specimen.*)

[With Plate XII.]

Exhibited by E. NETTLESHIP.

JOHN W—, æt. 22, died with a cystic tumour of cerebellum, under Dr. Stone's care, at St. Thomas's Hospital, on November 5, 1878. Four days before I had found severe double optic neuritis; discs steeply swollen, striated, and greyish-pink, with only a single small hæmorrhage. He read $\frac{20}{30}$, or nearly $\frac{20}{40}$ Snellen, and made out No. 1 Jaeger after looking at it for some time; visual fields and colour perception not tested. He was ill and weak on his legs.

Microscopical examination.—Optic disc much swollen, varying from $2\frac{1}{2}$ to $3\frac{1}{2}$ times its natural thickness. Under a moderately high power the swelling is found to be caused chiefly by fusiform and globular enlargements of the nerve-fibres, which by mutual pressure cause the appearance of a reticulated structure with very thin mesh-walls; this change affects the whole papilla, and extends a short distance into the retina. In the papilla the small vessels appear to be increased in number, and scattered clumps and tracts of nuclei are present, especially around the small vessels, but there is no general increase of cells. Outer layers of retina near the disc œdematous.

Lamina cribrosa pushed somewhat forwards (towards the eye), and its anterior layers opened out by the œdema of the nerve-fibres. In, and still more just behind, it there is marked increase of nuclei, especially in the fibrous septa between the nerve-bundles. This increase of nuclei is also noticeable in greater or less degree throughout the whole *orbital portion of the nerve,* especially in the circumferential part (see fig. 2); the cells are often crowded into little groups, particularly at the nodal points of the septa.

The *subvaginal space* near the eye shows evident increase of nuclei, but no overgrowth of connective tissue; there was no marked distension of the sheath. The swelling of the nerve-fibres begins in the *lamina cribrosa,* and is wanting behind; but at one

DESCRIPTION OF PLATE XII.

Illustrating Mr. Nettleship's Case of Optic Neuritis with good sight. (Page 252.)

FIG. 1.—Longitudinal (axial) section of optic disc and neighbouring parts (only one half is shown; the other half is still more swollen).

R. Retina.

Ch. Choroid.

Scl. Sclerotic.

L. Cr. Lamina cribrosa, its anterior layers separated by the swelling of the bundles of nerve-fibres.

c. a. Central retinal artery.

c. v. Central retinal vein. × 55.

FIG. 2.—A small part of the periphery of the optic nerve in transverse section. The section is from the portion of the nerve in the optic foramen.

I. S. Inner sheath of the nerve.

The section shows increase of nuclei, especially at the nodal points of the fibrous septa and at the innermost part of the sheath. × 55.

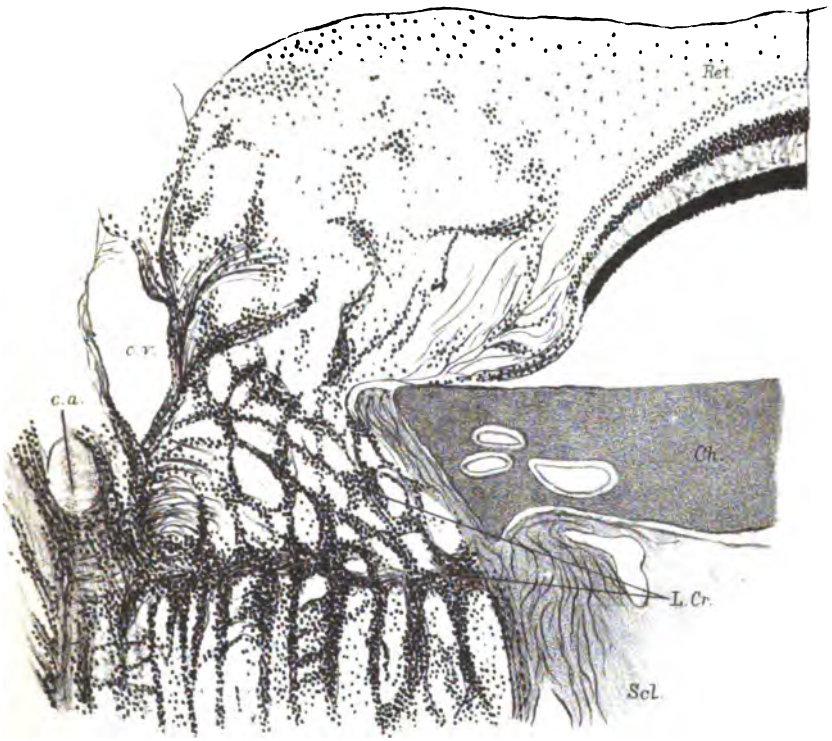

Fig I

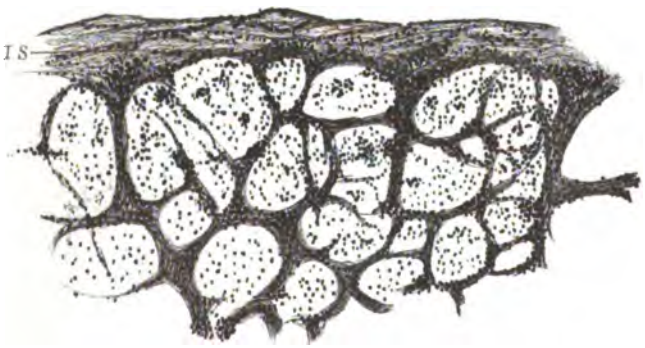

Fig II

$\frac{1}{100}$ In. × 55

part not far from the eye an apparently similar change is seen between the inner sheath and the nerve itself.

The *intra-cranial part of the nerve* was not examined.

January 20*th*, 1880.

2. *Eyeball degenerated and containing much cholesterin from a child.* (*Card specimen.*)

Exhibited by E. NETTLESHIP (for the President).

THE somewhat shrunken eye has been divided transversely. In one half the semi-opaque lens is seen from behind, partly covered by a soft substance which consists chiefly of cholesterin scales. This mass is united over about half the circumference with a tough membrane of varying thickness, which again is intimately adherent to the choroid and ciliary body; over the other half of the circumference it was less adherent and has been removed to expose the ciliary body, &c. The other glass-cell contains the posterior half of the eye seen from the front. The choroid is quite covered by the same tough membrane within which is the soft cholesterin pulp. The membrane varies in thickness and firmness in different parts, but its outlines are not now easily made out. The choroid is almost devoid of pigment over about half the circumference.

The retina cannot be identified; it is perhaps represented by the membrane adhering to the choroid, in which case the mass of cholesterin represents the vitreous humour; or the cholesterin mass may contain the remains of a detached and softened retina, the adherent membrane being adventitious. The latter is the more probable. Probably the cholesterin is derived from a copious hæmorrhage like that seen in the next specimen.

History, imperfect.—Cataract was noticed at the age of nine months. The eye was excised at three years. It was then soft and irritable, with a very deep anterior chamber, iritic adhesions, and opaque lens. No history of injury or illness.

May 18*th*, 1880.

3. *Spontaneous intra-ocular hæmorrhage in an infant.* (*Card specimen.*)

Exhibited by E. NETTLESHIP.

ONE lateral half of the eye of a child, æt. about 18 months, under the care of Mr. Duncan.

Retina detached and shrunken behind into a narrow cord, which expands in front to enclose the much shrunken greyish *vitreous*

humour. The wide *space between retina and choroid* is filled by blood-clot (containing well-formed corpuscles), which in front is buff-coloured, but at the back of the eye has a dark chocolate hue.

Iris in contact with cornea; posterior aqueous chamber contains some curdy substance.

Lens flattened and pushed forwards, its central part being in close contact with the iris; its posterior part is of a reddish-brown colour. A thin layer of dark brown colour is seen at the junction of the retina with the shrunken vitreous. The globe was hardened in spirit, and consequently became puckered.

At the age of fifteen months the child was very ill, with screaming attacks and other apparently cerebral symptoms. He recovered well, but during, or shortly after, the illness a reddish appearance was seen in one eye. No history of injury either to head or eye. At the time of excision the eye was shrinking and soft, the pupil was irregular from iritic adhesions, and a reddish-yellow reflex was very apparent from behind the lens. *May* 18*th*, 1880.

4. *Atrophy of optic nerve and retina, and other changes in an eye lost by erysipelas spreading to the orbit.* (*Card specimen; microscopical specimens.*)

Exhibited by E. NETTLESHIP.

SPECIMENS are from right eye of John H—, æt. 40.

May, 1878, erysipelas beginning at left ear, spread superficially to corresponding cheek and eyelids, across nose to right eyelids, where it passed deeply into orbit and caused sloughing of cellular tissue of upper lid. There was solid chemosis, immobility and some protrusion of eye, and ulceration of lower part of cornea. All perception of light lost early in the case, but no ophthalmoscopic examination possible. Tension not noted. Solid œdema of lids and conjunctiva, and muco-purulent discharge remained for many weeks. Eye excised at end of July, and œdema, &c., slowly subsided.

Adhesion of conjunctiva and fascia to globe at front of eye, but not further back; parts around optic nerve thickened and tough, but nerve itself shrunken. Vitreous humour normal except some albuminous exudation and excess of cells on its surface; pigment epithelium separates too easily from choroid.

Microscopical changes—.Œdema without inflammation of cornea, optic nerve sheaths and outer layer of sclerotic; œdema of conjunctiva with cell-exudation and extravasation of blood; œdema of ciliary body without cell exudation, the muscular tissue being but little affected; iris thickened and containing excess of nuclei, the fibres of its *ligamentum pectinatum* thickened, unusually distinct, and containing probably excess of nuclei; large extravasations beneath

conjunctiva and into retina (chiefly its nerve-fibre layer), and some blood in subvaginal space of optic nerve; atrophy of optic nerve and disc, with cupping of disc, but no evidence of previous swelling; atrophy of nerve-fibre and ganglion layer of retina, leaving its connective-tissue framework unaltered. No marked or important changes in choroid.

Details.—*Corneal œdema* is caused by dilatation of its cell-spaces, which are usually empty, but sometimes contain non-staining granular matter; corpuscles flattened against sides of the spaces and not increased. Descemet's epithelium badly stained and not increased.

Intervaginal *trabeculæ of optic nerve*, its *inner sheath* and inner layer of *outer sheath* much swollen, but no cell-increase; empty ramifying spaces (lymphatics) at head of intervaginal space. Nearly whole breadth of cut end of *optic nerve* (about $\frac{1}{12}$ in. from eye) appears to be necrotic, but this change affects only one half of the nerve at the *lamina cribrosa.* In this necrotic part all the elements are soft, ill defined, scarcely stained, and entirely devoid of nuclei, the nuclei of its small intrinsic vessels alone remaining. Other part of the nerve well nucleated, but showing degeneration of nerve-fibres. *Optic disc* moderately cupped, partly owing to complete atrophy of nerve fibres, partly from depression of lamina cribrosa, indicating probably heightened intraocular pressure; fibrous tissue forming floor of disc very richly nucleated.

State of the blood-vessels.—Engorgement of *veins* of conjunctiva and loose episcleral tissue, both in front of eye and near optic nerve; small veins of ciliary body often contain great excess of leucocytes. Schlemm's canal widely open and empty, and irido-corneal angle quite free. Veins of choroid and sclerotic proper usually empty though patent; vessels of chorio-capillaris often empty.

Arteries.—Anterior and posterior ciliary arteries upon and in sclerotic, and central retinal artery in optic nerve and disc, show—1, *adventitia* much swollen, clear, and homogeneous; 2, muscle coat greatly thickened by swelling, without multiplication, of its elements; 3, *intima* often corrugated, and *lumen* sometimes considerably narrowed; most of the large arteries are full of blood. Similar changes, but less marked in the choroidal continuations of the posterior ciliary arteries. *February 3rd*, 1880.

VIII. MORBID GROWTHS.

1.—*Tumour of face, plexiform sarcoma?*

By Jeremiah McCarthy.

[With Plates XIII and XIV.]

A. B.—, æt. 76, was admitted into the London Hospital, April, 1880, with a tumour, of the size of half an orange, completely concealing the right eye. It was somewhat circular, slightly lobulated on the surface, about three inches in diameter, and an inch in thickness. It extended from the right eyebrow to nearly the angle of the mouth, and from the nose to the temporal region. It was very vascular, bled freely on the slightest manipulation, and sometimes spontaneously, and looked like some fungous growth from the orbit. On examination, however, it proved to spring from the right cheek immediately below the lower eyelid. There was no enlargement of the lymphatic glands and but little pain, which the patient referred to the part of the scalp supplied by the supra-orbital branches of the fifth nerve.

Patient stated that he had had a small wart on his face from which he used to pull off a scab; that this wart had grown to about the size of a walnut, and was then burned off with caustic, but that it soon returned and grew to the above-described size in thirteen months.

The tumour was in chief part removed with the benzoline cautery, and the rest freely excised. There was some troublesome hæmorrhage from large vessels near the nose, and a raw surface about the size of a florin left, in which were seen the fibres of the orbicularis palpebrarum completely exposed. Three days after, this surface was grafted with about twenty pieces of skin obtained from a supernumerary finger removed from an infant. All the grafts took, and in three weeks the wound had completely healed with

DESCRIPTION OF PLATES XIII & XIV.

Illustrating Mr. McCarthy's Tumour of the Face. (Page 256.)

PLATE XIII

Gives a front view of the tumour as it appeared during life.

PLATE XIV.

FIG. 1.—(Hartnack, obj. 2, oc. 3, tube closed.)

a. Trabeculæ of fibrous tissue.

b. Cord-like bands of round cells.

c. Necrosed portion in centre of these bands.

d. Apparent space between fibrous tissue and round-celled growth probably due to shrinkage of the latter.

FIG. 2 (Zeiss' obj. F., oc. 3, tube drawn out).—Slightly oblique section of a blood-vessel in a bifurcation of band of round-celled growth. The component cells of vessel are much swollen, and the nuclei large and in some instances subdividing. The intra-nuclear network is well seen in the surrounding "round cells."

FIG. 3.—(Zeiss' obj. F., oc. 3, tube drawn out.)

a. Fibrous tissue, with connective-tissue corpuscles.

b. Apparent sinus between fibrous tissue and "round-celled" growth, with very fine interlacing fibres passing across.

c. Elongated nuclei of cells, showing intra-nuclear network.

d. "Giant nucleus" subdividing.

e. Mulberry giant nucleus.

These microscopic drawings are by Mr. Frederick Treves.

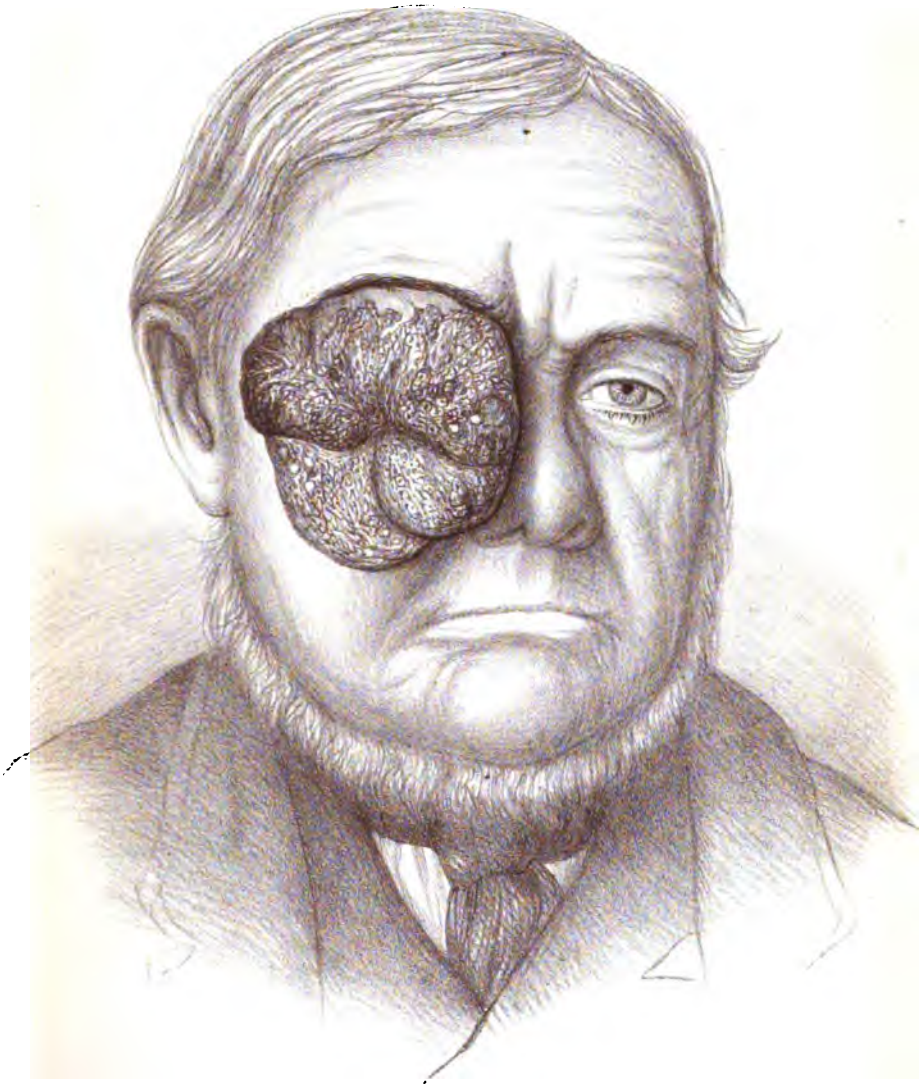

F. Burgess del et lith

West, Newman & Co imp

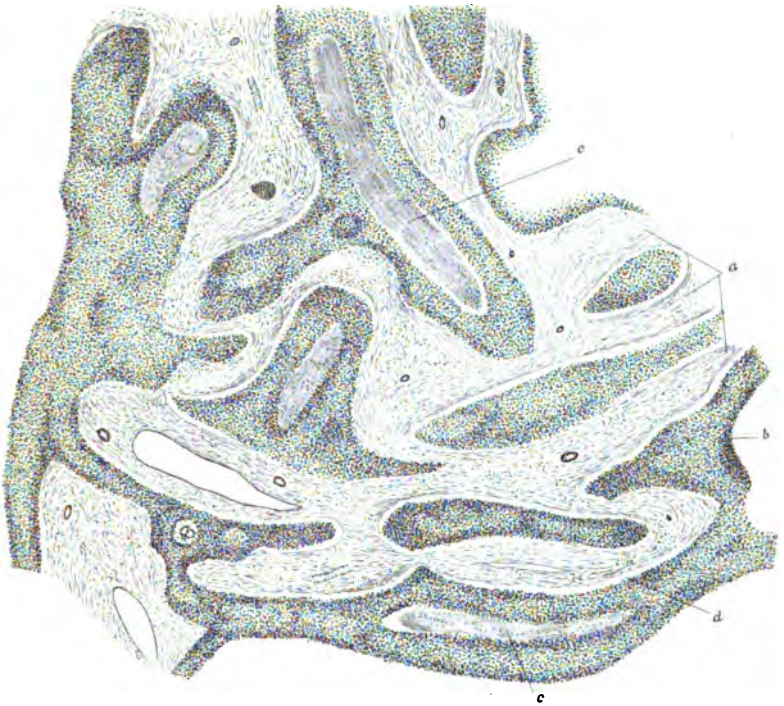

Fig I

Fig II

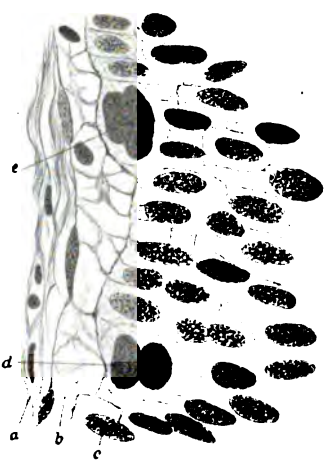

Fig III

F. Treves del.

E. Noble Smith, fecit.

scarcely any eversion of the eyelid. The patient, who had greatly improved in condition while in the hospital, was dischared cured.

The tumour, on section, presented a juicy, somewhat fibrous appearance, and was studded with numerous yellow masses, each about the size of a pin's head.

The results of microscopic examination were as follows :—The free surface was bounded by a very thin membrane, in vertical sections appearing like a sharply-defined line, and much resembling the basement membrane of the skin. There were, however, no papillæ, nor any trace of epidermis, except near the attached border of the tumour, where there was laminated epithelium, with the component cells swollen and loosely connected together. Beneath this membrane was rapidly growing fibrous tissue, with a great abundance of connective tissue and lymph corpuscles, and in some parts many coloured blood-corpuscles; occasionally the outline of a capillary vessel could be distinguished, but for the most part these blood-corpuscles were free in the interstices of the tissue, and their presence there was most likely due to the manipulation and pressure inevitable in the removal of the tumour. Deeper still similar fibrous tissue was arranged in trabeculæ with large meshes. This part was very vascular, and contained some large blood-vessels and many capillaries. Some of the blood-vessels appeared to be becoming occluded by increased cell-growth in their walls, and much resembled the condition of blood-vessels to be found in the thymus gland of a newly-born child, the precursors of the so-called Hassall's corpuscles.

The meshes of this tissue were filled with plexiform cord-like bands composed of cells with large oval nuclei, showing a very distinct intra-nuclear network. For the most part no outline of the cells could be distinguished, and the narrow interval between the nuclei presented a finely granular appearance and did not stain with hæmatoxylin. At the periphery of these cords, however, in some parts, very distinctly outlined columnar cells could be seen, the nuclei forming the largest part of the cell. Again, in many parts of these cords, were nuclei so very large that the cells to which they belonged might fairly be called "giant cells." These cells had usually a well-defined limiting membrane, and the cell-substance formed a narrow colourless line round the nucleus. This was sometimes segmented on the surface so as to resemble a mulberry, and at other times had thick processes projecting irregularly.

Some cells contained four or more nuclei, so arranged as to suggest their origin by segmentation from a single nucleus. Sections stained with eosin and hæmatoxylin showed some very fine fibres passing from the surrounding connective tissue between the peripheral cells of these cord-like masses, and in some parts these fibres were larger and formed a distinct network, in each of the meshes of which was contained a single cell. For the most part, however, these fibres could only be traced between the peripheral cells. Many of these cords contained in their centre a necrosed mass, consisting of granular *débris* and some corpuscles. Lastly, these cords were altogether non-vascular, and in many parts there was a space between them in their surrounding connective tissue, much resembling a lymph sinus of a lymphatic gland. These spaces, however, obviously resulted from shrinking of the softer substance under the influence of hardening reagents, and in some parts traces of ruptured fibres could be seen in them.

The history of this tumour, its macroscopic and indeed, to a great degree also, its microscopic appearance, correspond with the descriptions given by Virchow and Billroth of sarcomatous growths originating in warts. An illustration of so-called plexiform sarcoma in 'Billroth's Pathology' might serve as a diagrammatic sketch of portions of this tumour.

With the greatest deference to these authorities, it requires a large degree of faith to believe that these cord-like masses are of connective-tissue origin. Their sharp differentiation from their surrounding connective tissue, the absence of blood-vessels, and the appearance of the individual cells, suggest rather some form of rapidly growing epithelial structure. *May* 18*th*, 1880.

---

2. *Pulsating tumours of the left parietal bone, associated with others similar tumours of the right clavicle and both femora, and with great hypertrophy of the heart.*

By Henry Morris, M.B.

[With Plates XV and XVI.]

Mary B—, æt. 40, a needlewoman, was admitted, under my care, into the Middlesex Hospital, on August 6th, 1874, for a large pulsating tumour of the head. She was a short, stout woman, with a thick, fleshy neck, and some general swelling of the thyroid body. She had always enjoyed good health, with the exception that when quite a girl she had "white swelling in both knees," which had caused her to walk slightly lame ever since; old cicatrices over the lower end of each femur firmly adherent to the bone beneath, indicated also some other previous affection. She was a widow, and thirteen years ago had a child, now dead; her catamenia had always been regular. There was no family history of any disease.

1872.—Two years ago she fell whilst romping, and struck the left side of her head against a table drawer. She fainted at the time; a small blood tumour quickly formed, but had disappeared by the next morning, and an aching pain was felt for some hours afterwards.

One month after the blow a hard but painless lump, the size of a Barcelona nut, was detected on the parietal bone a little to the left of the sagittal suture.

1873.—This increased slowly but continuously, and in the summer of 1873 was the size of a small apple; then a second lump was noticed in front of it, and nearer the temple than the first. Before Christmas, 1873, these two swellings had united into one, and went on increasing in size more rapidly up to the time of admission. For three or four months previous to admission she had suffered from a dull, throbbing headache, involving the left half of the head and affecting the left eye.

1874.—*On admission* there was a very prominent, soft, pulsating circular tumour to the left of the middle line on the vertex of the skull. It measured 13 inches in circumference, 5¾ inches from side

to side, and $5\frac{7}{8}$ inches from before backwards. Above, it reached to the middle line and forwards to the line of junction of the hairy scalp with the forehead. It was most prominent towards the top of the head, and around the circumference of its base a hard raised ridge, probably bony, was felt.

The tumour did not move with the scalp; the skin covering it was no where ulcerated, but was mottled with a purplish blue colour, and large distended veins ramified over the lower and anterior part. Pressure caused no actual discomfort, though a sense of relief was felt on its removal. The sight of her left eye was slightly impaired, and she stated that when the headache was very intense she saw flashes of light in it. There was no alteration in the appearance of the eye. There were no enlarged cervical glands.

Six days after admission the tumour was punctured, and a little blood withdrawn. She thought she was relieved by this.

On August 15th the accompanying photograph was taken.

25th.—An uniformly *pulsating* and *expansile* tumour was distinctly perceptible both to eye and hand immediately above the sternal end of the right clavicle. There was dulness on percussion over the manubrium sterni down to the second interspace, and extended a little to the right of the sternum. The left common carotid pulsated more distinctly than the right, and could be seen pulsating along its whole course. There was no difference in the radials at the wrists. Dr. Coupland examined her chest, and reported that the apex beat of the heart was rather nearer the nipple than normal, but the area of cardiac dulness was not increased. Both heart sounds at apex were rough and accentuated; at the second left interspace a faint systolic murmur was heard, followed by an accentuated second sound; at the second right cartilage there was a rough systolic murmur, which could be traced in a curved direction across the manubrium sterni to the second left interspace.

September 3rd.—As the tumour was increasing and the cutaneous veins more distended, an attempt to check its growth by compression was tried. For this purpose a cap of strong elastic webbing was placed over it, and fastened across the head and around the forehead by bands and buckles.

11th.—The tumour measured $12\frac{1}{3}$ inches in circumference, and had, therefore, diminished half an inch. The compression was causing some pain.

19th.—The tumour was stationary, but as the cap caused excessive "wearing" pain, it was ordered to be abandoned at night, and a few days later it was discontinued altogether.

October 6th.—She left the hospital, the tumour being then 6½ inches in antero-posterior, and 7 inches in transverse, measurement. There were no cerebral symptoms whatever, and the only thing complained of was a sense of general fulness in the tumour and distension of the thyroid gland.

She returned to the hospital on December 24th, 1874, when the following report was made:

"Not much alteration in the tumour. No cardiac trouble, no shortness of breath, no cerebral symptoms. The hard rim formerly felt around the base of the cranial tumour is now distinct only in places, but at the front part of the circumference there are small movable bodies. The scalp is quite supple and can be wrinkled up between the finger and thumb over the surface of the tumour. Both the right and left temporal and the left supra-orbital arteries are felt pulsating strongly as they converge to the tumour, and a small artery beats very forcibly just above the outer angle of the left orbit. When the sterno-mastoid muscles are put on the stretch, the soft pulsating swelling below and between their origins is seen extending upwards for 1¾ inch. It spreads under the right muscle, but does not pass beyond the inner edge of the left sterno-mastoid. The pulsation of the tumour is communicated to the fingers placed on the right sterno-mastoid. There is swelling and pulsation over the front of the sternum, over the right sterno-clavicular joint, and right first intercostal space, for 2 inches downwards from the sternal notch, and for 2½ inches to the right from the median line. A depression along the origin of the right sterno-mastoid muscle marks off the deep cervical from the superficial thoracic part of this swelling.

"There can be but little doubt that the cranial tumour is springing from the diploë, and the swelling in the neck is in all probability a growth of the same kind from the sternum or clavicle, but the following questions occur as to the head tumour:—Are the movable bodies phleboliths or detached nodules of bone? Is the unaffected condition of the skin due to the protective and limiting agency of the pericranium, and will the dura mater act in the same way to protect the brain? Will not death be soon caused by compression of the brain, or will the tendency be to increase outwards,

being prevented from growing freely inwards, by the constantly acting hydrostatic force of the cerebral circulation?"

During her short stay in the hospital at this time, she was examined by several of my colleagues, including Mr. De Morgan, Dr. Thompson, and Dr. Greenhow, who all concurred in my opinion that the neck tumour was not aneurysmal, and that the cranial tumour was in all probability diploic in origin.

On January 1st, 1875, Dr. Greenhow reported that a distinct systolic murmur was heard over the sternal tumour and extending along the right carotid artery; that resonance was greatly impaired all over the area of this tumour; that the tumour pulsated and was expansile; that immediately to the right of the spinal column, between it and the scapula, a distinct murmur was audible; and that a distinct murmur was also audible over the greatly enlarged left temporal artery along its course to the tumour on the head. The patient now went to reside at Brighton, and on March 16th, 1875, she wrote: "I am sorry to tell you that the tumour in my head continues to increase; it measures 14 inches in circumference and 6½ inches in diameter, it is also much harder than it used to be. My chest is very painful, I cannot move my right arm without much pain, and I find my right breast is affected from the swelling in my chest, and hurts me when I cough or even sigh."

For information respecting the further progress of the case I am indebted to my friend, Mr. Couling, of Norfolk Square, to Mr. Field, at that time attending at the Sussex County Hospital, and to Mr. Morris, of Dorset Gardens.

On November 6th, 1875, Mr. Couling wrote: "The swelling at the top of the chest has increased somewhat, and the swelling on the top of the head has very much increased. She is very anxious to have the latter punctured, as she says she had so much relief after you did this during her stay in the hospital."

On the 22nd of November, 1876, Mr. Couling wrote: "Both swellings are increasing, and she has another on the top of the right thigh, which I discovered yesterday."

On April 21st, 1877, I had the opportunity of examining her again. She was confined to her bed, and had been for a very long time past. She was suffering much, and had become quite thin. Her general intelligence and sight were unaffected. Her pupils and radial pulses were equal. There was an enlarged gland in the pos-

terior triangle of the right side of the neck. A large, smooth, rounded, and softly-pulsating tumour was situated near the right hip-joint, and had all the characters of an expansion of the upper end of the femur. The thigh was flexed on the abdomen and adducted; it was seldom moved, and then only with great and lasting pain.

The chest tumour was very prominent, pulsating, expansile, and of rounded outline. The fingers could now be easily dipped down behind it at its upper border. The head tumour was larger, and all the chief arteries leading to it pulsated visibly.

On May 12th, 1878, I saw her for the last time. All the growths had increased; that on the scalp had spread over the median line, and was much more prominent. The tumour of the right thigh was as big as a large adult head. Another pulsating tumour had appeared in the left hip. The veins of the forehead and left side of the neck pulsated. She suffered intense pain.

On October 27th, 1878, I heard of her death through Mr. Couling, and subsequently I received the following account from Mr. Morris, of Brighton, who made the *post-mortem* examination:

"I attended Mary B—, on and off, from September, 1876, till she died, of bronchitis, October 27th, 1878. She had had several previous attacks, and the expectoration was generally very fœtid. During the last six or eight months she occasionally coughed up a considerable quantity of blood.

"About nine months before her death a swelling similar to the others appeared in the left hip. All the superficial blood-vessels of the neck and scalp were enlarged and pulsated strongly, and there was a murmur at the base of the heart. Her pupils were nearly equal, the left a little larger than the right. Her intellect was clear. though her temper was very irritable. Her chief troubles were shortness of breath, inability to lie down, and pain in the different tumours. On inspection after death a fifth tumour was found over the inner condyle of the right thigh-bone, about five inches in length by three inches in breadth, which could be grasped in the hand and moved, though it was adherent to the bone beneath.

"The right thigh looked as if it was dislocated, being rotated inwards, so that the inside of the thigh rested on the bed. On removing the skin from the upper part of the chest and neck the blood-vessels were found to be very large and full of blood. The heart was very large, like a bullock's, but the valves were

healthy. The kidneys were healthy, and there was no deposit in the lungs.

"On sawing through the bone around the parietal tumour, and cutting through the dura mater to the same extent, the latter was found, at one point, to be adherent to the pia mater.

"I should think, from the appearance of the growth, that it most decidedly began in the diploë. The skull as bone seemed to be completely destroyed in the situation of the growth. There was no sign of inflammation or congestion about the brain, which was flattened and depressed by the tumour. The tumour, at the inner end of the right clavicle, was as large as an egg; it was in the substance of the clavicle itself. The sternum was not implicated at all, and the right sterno-clavicular joint was healthy.

"The other tumours were not dissected, owing to want of accommodation and the objections of friends."

Subsequently I received one half of the cranial tumour, the other half having been placed by Mr. Blaker, of Brighton, in the Museum of the Sussex County Hospital.

The growth is seen to be well limited by the pericranium on the outer and the dura mater on the inner side, each of which rises off their respective surfaces of the bone over the convexities of the tumour. On the *outer* surface of the bone the tumour spreads wider, is more prominent, and altogether larger than on the inner surface. At the centre the whole thickness of the bone has disappeared for a distance of an inch and a half, and from this the tumour spreads at once over the ragged edges of the bone on to the outer surface, both in front and behind, for about one inch and a half. Though the tumour is tightly compressed between the pericranium and the bone, it seems to have been but loosely connected with the latter, and gives the idea of having simply spread itself out upon the external surface of the skull. On the *inner* side the bone slopes off gradually up to a thin edge of the inner table, which projects a little over the convex surface of the tumour, so that the inner table is destroyed to nearly double the extent of the outer, and the diploë is encroached upon to a greater degree than either table. The bone is very much increased in thickness, and is very hard. The branches of the middle meningeal vessels are plainly visible running over the inner surface of the tumour, beneath the dura mater, and the grooves on the cerebral surface of the bone for the ramifications of the meningeal artery are very much wider than usual. A diploic

vein, of large size, is seen at the cut edge of the bone, far beyond the tumour.

The microscopical structure of the head tumour having given rise to much diversity of opinions on the part of several who examined it, I asked my friends Dr. Goodhart and Dr. Thin to give me a report of it, and the substance of their reports was stated to the Society when the specimen and drawings were shown. It is satisfactory to find, from the subjoined accounts, that they at least have arrived at much the same conclusion as to the nature of the growth, and that, too, though their investigations were conducted independently of one another.

Dr. Goodhart writes:

"To the eye the section is spongy in texture, and under the microscope it is seen to be composed of a hyaline basis like that found in rapidly growing enchondromata or myxomata, and for either of which it would very well do. This basement matrix contains very few cells or nuclei that can be said to be proper to the tissue it makes, but it is crowded with cells, which can, I think, be traced from one or two together up to those forming a definite lining membrane to spaces with which the field is covered. It appears to me that the earliest stage is one of single cells embedded in the tissue. The next one of clustering of three, four, or five cells together, all of similar appearance and probably derivatives of the isolated cell; in these clusters the central parts give way, and a cyst is formed lined by these cells. The cysts then gradually expand, and so form the spongy texture which the tumour exhibits. All the larger cysts are lined by a very uniform lining of cutical cells, and many of them are, I believe, a secondary process, filled with blood-corpuscles.

"From the appearances presented, the tumour, though confessedly of doubtful nature, is probably a rapidly growing enchondroma. And for the following reasons:

"1st. The matrix of it is of a peculiarly colloid appearance, unlike anything save the basis of some enchondromas and myxomas, and the tumour is certainly not a myxoma.

"2ndly. Though the cells are undoubtedly small, I think certain stages of cyst formation can be traced.

"3rdly. That the cutical cells which line the space are unlike the cells of a columnar epithelioma, are unlike those lining the

vascular spaces of a nævus, and are quite like those found in some cases lining the cyst of an enchondroma testis, and sometimes of parotid enchondromas.

"It has been held by some that the tumour is a nævus, but the spaces are quite unlike nævoid spaces in the existence of so well-defined an epithelium, and further, the mere presence of blood in many of the spaces, and, I may add, the existence of pulsation in the tumour during life, are not necessarily any contradiction to this view; for many tumours not intrinsically nævoid pulsate, and some undergo a secondary conversion into nævoid tissue at a later period of their history. Cavernous tumours of the liver, for instance, originate in fibrous tumours."

Dr. Thin writes:

"The tumour, a portion of which was given me to examine, has been fourteen months in spirit. On cutting it I found that its consistence was more favorable for obtaining thin sections than would have been the case in a tumour composed of ordinary fibrous connective tissue. A portion was soaked in water for two days, and still retained sufficient resistance to the knife to permit sections to be cut.

"The tumour is composed of a matrix and cavities. The former is homogeneous, and sparsely infiltrated with minute rhomboidal particles, and does not stain well with carmine. It is divided into lobules by bands of fibrous tissue, which stain strongly with carmine. The fibrous tissue of the investing pericranium also stains well in carmine.

"The cavities vary in size from that of the ordinary cartilage capsule seen in hyaline cartilage to cavities sufficiently large to be easily seen by the naked eye, some of them being equal in diameter to that of an ordinary sewing needle.

"In their least developed stage the minute cavities contain a single cell in their centre, but very few were found in this stage. All the other cavities, even the very small ones, are lined by a single layer of cells. Seen from the surface these cells are observed to be of nearly uniform size; the nucleus is round, the cell protoplasm scanty and granular, and the outline of each cell very distinct. The cells are polygonal, many being pentagonal, and are very epithelial-like in their arrangement.

"Their length and breadth are about equal, ·012 mm. and ·006 mm

being extremes of measurement in either direction, the majority and the mean of a number of measurements being ·009 mm.

"The cells are planted in the matrix, side by side, like an epithelium, but there is nothing in the appearance of the individual cells that I consider to be absolutely decisive in favour of their epithelial nature.

"Logwood has an affinity for the matrix, which it stains readily, contrasting in this respect with carmine.

"The large cavities are filled with a homogeneous substance, which stains readily and deeply with logwood. Dr. Hamilton, of Edinburgh, to whom I sent a portion of the tumour, has given attention to the nature of this substance, and writes me to the effect that 'it is not fatty nor amyloid, and that it is exactly like colloid, with this exception, that it does not readily moisten with water.' Around some of the large cavities, from which the cells have fallen out, a thin delicate membranous-looking shred is seen in carmine-stained sections, but I have not observed any appearance to which I think it would be justifiable to give the name of membrana propria.

"I consider the matrix of the tumour to be cartilaginous, and in consideration of the cavities I consider that the growth might be termed a cystic enchondroma. I do not think that the appearance resembling tubular epithelium is sufficiently definite to decide the nature of the growth. Possibly it is tumours in some respects like this one that have been described as instances of a combination of chondroma with alveolar sarcoma.

"The appearance of the cell-lined cavities is unlike anything produced by morbid action originating in the sweat or sebaceous glands, so far as my reading or experience teaches me."

A portion of the tumour having been sent to M. Cornil, of Paris, he reported upon it in the following letter to Dr. Thin:

"PARIS; *le 2e Avril*, 1880.

"MONSIEUR ET SAVANT CONFRÈRE,—Je n'ai jamais vu de tumeur absolument semblable à celle que vous m'avez envoyée: M. Ranvier non plus.

"Elle est formée de petits kystes fermés, à contenu colloïde et à revêtement formé par une seule couche de cellules pavimenteuses constituant une membrane parfois isolée par le hasard de la préparation.

"Dans la partie de la tumeur qui vous m'avez envoyée (j'ignore si toute la tumeur etait constituée de la même façon) tous ces kystes, même les plus petits, avaient absolument la même structure. Le stroma etait fibreux sans caractère spécial. La substance colloïde qui remplissait complètement les kystes etait assez dense, homogène, sans qu'il y eut d'etat intermédiaire entre elle et les cellules pariétales des kystes.

"La partie que vous m'avez envoyée présentant le développement complet sans qu'il y ait d'éléments normaux de la peau ou des parties voisines en voie de modification, il m'a été impossible de déterminer l'origine de cette tumeur.

"Les préparations de cette tumeur ne ressemblent absolument à aucun tissu normal. Elles se rapprochent un peu de la structure de la glande thyroïde. Elles peuvent être comparées aux tumeurs kystiques multiloculaires de l'ovaire et du peritoine dont cependant elles diffèrent par la structure uniforme et par le volume des kystes qui sont tous très petits.

"On pourrait encore comparer ces kystes à quelques uns de ceux qu'on trouve dans certains carcinomes ou épithéliomes colloïdes. Mais là encore, à coté d'alvéoles à contenu colloïde, on en trouve qui présentent nettement la structure du carcinome ou de l'épithéliome à cellules pavimenteuses ou cylindriques.

"Si tous les points de la tumeur sont identiques à celui que vous m'avez envoyé, s'il n'y a pas moyen, aux bords de cette tumeur, de déterminer son origine, je la regarderais comme ne rentrant dans aucun cadre connu ; comme se rapprochant des kystes à contenu colloïde—adénome ou épithéliome colloïde—ou micro-kystome colloïde.

"Veuillez recevoir l'assurance de mes sentiments très distingués,

"V. CORNIL.

"6, rue de Seine, Paris."

Professor S. W. Gross has sent me a report of a case which has not before been published, and which in some particulars bears a resemblance to Mary B—, although in others it is as strikingly different. These will be best appreciated by given the description in his own words.

"*Multiple central medullary round-celled sarcoma of the osseous centre system, occurring in a mulatto boy,* 51 *months of age.*

"At the age of 42 months pain was experienced just below the

left shoulder-joint, and, four weeks subsequently, a small swelling was detected near that locality, which continued to increase, without interruption, until it finally measured five inches more in circumference than the opposite arm. Shortly before death it was tender, soft, elastic, bossed, and hot to the touch, while the skin was glossy, the seat of ecchymotic spots and enlarged capillaries, and the subcutaneous veins were somewhat prominent.

"One month after the appearance of the swelling near the shoulder a tumour developed in or over the left parietal bone, which gradually extended over the entire corresponding side of the head, until, just before death, it mounted 3½ inches above the level of the side of the cranium, and 2½ inches above the vertex, its bulk being almost equal to that of the head itself. It was hot, soft, and fluctuating; the veins of the head and face were unduly large, and both upper eyelids were ecchymotic.

"Five months after the first symptom in the left shoulder, the lower extremity of the left femur began to enlarge, there having been pain in this situation for one week previously. It was 2½ inches greater in circumference than its fellow, and its external features were similar to those of the tumour of the left humerus.

"At this time, or three months before death, the belly began to swell, and suffering was experienced in the right shoulder, which terminated in the appearance of a tumour in the head of the corresponding humerus, one week before the fatal issue, when a swelling was discovered at the angle of the left lower maxilla. For the last two weeks of its life the child's general condition notably failed rapidly, it having lost flesh, strength, appetite, and spirits, and its sleep having been broken by suffering. Death ensued on the 10th of September, 1879, *the total duration of life having been only nine months.*

"On *post-mortem* inspection, the tumours were found to have originated in the medulla of the involved bones. Their tissue was rosaceous-white, soft, and almost diffluent. Of the left humerus nothing remained save the lower epiphysis; the left femur was involved throughout its lower three fourths, while the tumour of the right humerus was confined to its head. In deference to the wishes of the parents the cranium was not examined.

"The retro-peritoneal glands formed a mass as large as an adult head, which was most prominent on the left side, and closely adhered in front to the small intestines. Its surface was largely bossed, its

consistence soft and elastic, and its tissue, on section, was of a delicate pink tint, mottled, here and there, with extravasated blood.

"The left kidney was atrophied; the right was enlarged one third, and pale; the liver was hypertrophied, fatty, and friable, and adherent to the diaphragm. The thoracic viscera were normal.

"The minute structure of all the growths was that of a myxomatous, small round-celled sarcoma.

"The successive development, at short intervals, of tumours in the osseous system and in the abdominal lymphatic glands, shows that the neoplasm of the left humerus was the primary one, and that the others were of a secondary nature.

"The points of interest are the early age of the subject and its unusually rapid course. In my paper on "Round-celled Sarcoma," in the 'American Jour. Med. Sciences' for October, 1879, I show that of twelve cases the earliest age was nine years, the average being twenty-eight, while the average life of those which was a natural course was twenty-three months." *March* 21*st*, 1880.

Report of the Morbid Growths Committee on Mr. Morris' specimen of pulsating tumour of cranium.

The specimen submitted to us consists of a portion of the vault of a skull, on the outer aspect of which is what appears to be the larger part of a flattened tumour, about an inch in thickness, Corresponding with the centre of this is a smaller tumour of the inner aspect of the skull, also flattened, and about an inch in thickness, which communicates with the external tumour through an aperture in the skull an inch and a half in diameter. The outer tumour is completely covered by what appears to be the pericranium, the inner by the dura mater. The bone is thickened and sclerosed at the circumference of the aperture. The thickening is greater on the inner side, and this aspect of the opening is much wider than the outer. The bone is nowhere continuous over the surface of either of the masses.

A section of the growth presents, to the naked eye, a very fine spongy appearance, traversed by a few fibrous bands, and in the intracranial portion are found several spiculæ of bone. The inner table of the skull around the growth is deeply furrowed by branches of the meningeal arteries, the grooves for which are much larger than natural.

DESCRIPTION OF PLATE XVI.

Illustrating the Report of the Morbid Growths Committee on Mr. Morris's Pulsating Cranial Tumour. From drawings by Mr. R. J. Godlee. (Page 270.)

FIG. 1.—A section, seen under a low power. × 56 diameters.

Shows large and small alveolar spaces, some filled with colloid material, some empty.

FIG. 2 and 3.— × 275 diameters.

2.—Some of the smaller spaces; a piece of the wall being looked at directly shows the arrangement of the epithelium.

3.—Parts of three large spaces filled with colloid material.

FIGS. 4 and 5.— × 370 diameters.

Two groups of very small spaces indicating their earliest development. In Fig. 4 are seen two single cells, which are apparently forerunners of the alveolar spaces.



Fig I.

Fig IV

Fig II

Fig V

Fig III

Sections examined microscopically display the following structure:—The basis substance is composed of a homogeneous material traversed by bands of fibrous tissue and by vessels. Contained in this basis are numerous spaces differing in size, for the most part circular in shape, but sometimes elongated and irregular, most of which are distinct, though a few appear to communicate with one another. The larger spaces are lined with a single layer of small distinct polygonal cells, containing each a single nucleus. The interior of these spaces is filled with a homogeneous substance staining both with carmine and hæmatoxylin, which in rare instances contains some altered blood or a few cells which may possibly be adventitious. The smallest spaces are packed with cells similar to those which line the larger ones. Where the smallest spaces are most abundant, single large granular cells are occasionally seen, which appear sometimes to be undergoing subdivision. We do not find any cells resembling those of cartilage or mucous tissue, nor have we been able to discover in any part of the tumour individual cells distended with colloid substance; but as soon as the spaces reach any considerable size, a globule of colloid material appears surrounded by a single layer of cells.

We have not met with any primary tumour of bone presenting the foregoing characters; and the specimen submitted to us does not resemble any form of sarcoma or enchondroma with which we are acquainted. We have been struck with the resemblance between the structure of this growth and that of certain enlargements and tumours of the thyroid gland; and the same idea seems to have occurred to M. Cornil, to whom a section of the tumour has been submitted. We have since discovered that this patient suffered from a considerable enlargement of the thyroid, which indeed is well illustrated by the photograph appended to the report. The question therefore arises whether this and the other tumours were not secondary to a primary affection of the thyroid body. In support of this theory we may refer to a short paper by Cohnheim, in 'Virchow's Archiv,' Bd. 68, s. 547 (1876), which contains the details of a case of colloid tumour of the thyroid (Gallertkropf), with secondary growths in the lungs, the bronchial glands, the vertebræ, and the femur. The structure of these tumours appears to have corresponded precisely, in almost every particular with that of the growth in Mr. Morris' case. Cohnheim also refers to a similar case, reported by Max Runge ('Virch. Archiv,' Bd. 66,

s. 366, 1876), the microscopical examination of which was made by Von Recklinghausen, when, with a similar enlargement of the thyroid, a tumour presenting the same microscopical characters existed in the axis and atlas. In each of these cases, as well as in that submitted to us, tumours of a similar microscopical appearance *existed* in bones, and on each of them an enlargement of the thyroid gland was present.

The tumour therefore appears to belong to the same group as those to which we have referred. They are evidently malignant, but the evidence with regard to them is, at present, very meagre, and is not, in our opinion, sufficient to warrant their being placed amongst any one of the large classes into which morbid growths are usually subdivided.

MARCUS BECK.
HENRY T. BUTLIN.
RICKMAN J. GODLEE.

---

3. *Recurrent mammary tumour; spindle-celled sarcoma (?); the sixth removal.*[1]

By JOHN GAY.

THE specimen exhibited was taken from the right mammary region of an unmarried woman, æt. 38, on the 26th of May, 1880.

It was the sixth removal of tissue, including tumours, that had been made from that neighbourhood. The first took place in May, 1865, the growth having been six years in the course of development; the second was in July, 1867; the third in May, 1869; the fourth in May, 1874; and the fifth in June, 1877.

The intervals between the acts of extirpation and time of apparent return of these several products varied on each occasion from three months to as many years. On the whole, their growth

[1] See 'Pathological Transactions,' vol. xvi, p. 240; vol, xx, p. 359; and vol. xxvii, p. 233.

was slow, but it was noticeable that the period of greatest activity was on the approach of the spring season. At no time has there been any discoverable disturbance of the axillary or other glands. At the second operation the mammary gland was also taken away, for it had wasted, was very closely attached to the tumour, and overlapped it.

The first commenced at the upper and inner edge of the breast, and took a curvilinear course downwards along its margin until it reached a point slightly below the inferior border; the second took the like course but along the outer side; whilst those which followed shifted their position, as I anticipated, gradually further in the direction of the axilla, until, as in the case of the last, it attained a position (for purposes of operation) in somewhat dangerous proximity to the large vessels.

The recoveries were uniformly satisfactory, and left a series of white glistening linear cicatrices, that have shown no tendency to become the seats of unhealthy deposit or change.

After the first the growths were multiple; on one occasion there were seven, in close apposition to, but not without some slight freedom of independent motion on, each other, whilst they severally moved freely together as one mass, and each gave evidence of being distinctly lobulated. To external observation they had the ordinary objective signs of what has been known as "adenoid," "recurring fibroid," or "spindle-celled sarcoma," but on closer, combined with histological, inspection, it seemed matter of doubt whether either of these terms is calculated to give a correct notion of their true nature and pathological import.

Moreover, up to the last, the tumours do not seem (with one exception) to have differed materially in their essential characteristics; and although in accordance with the difficulties which surround morbid histological investigations there have been in narration some minor points of discrepancy, at the same time, there are none that do not admit of reconciliation with the general view of their nature, suggested in the course of the reports that have been made of them.

From Dr. Hodgkin's and my own observations they seem to have been originally cystic or cystiform, and to have assumed their advanced and more concrete appearance by the packing, and especially the compression to which their histological constituents had been subjected; for on cutting them through the surfaces bulged

out as if in virtue of their release. They were found, too, exclusively within the meshes of the deep fibroid textures; their favourite habitat being the fibrous envelope of the mammary gland, its marginal fringe, and especially its prolongations in the direction of the axilla ('Trans.,' vol. xx, p. 359).

Thus, on the removal of these tumours, small cysts, some of exceeding minuteness, were found congregated in these particular expansions, diminishing in numbers and size according to their distance from the tumours. Dr. Goodhart, who was so good as to examine some ('Trans.,' vol. xxv, p. 233), reported them as "having the usual appearance of spindle-celled sarcoma. Each tumour, however, had," as in the case of those observed by Dr. Hodgkin and myself, "a margin of greyish-coloured new growth, without defined capsule." This was, it might be fairly assumed, due to an aggregation of such cysts around the sarcoma; and, it might be, that they had some embryonic relation to it. This helps us towards an explanation of the lobular character, as well as the recurrence of these products, the lobules being made up of the close aggregation of condensed tissue that were originally detached cysts. And this seems to be indicated by the fact that in some instances these cysts appeared to have been so closely impacted that, in the process of expansion or development, a cyst, failing to drive its neighbours before it, enfolded or invaginated them instead; for we found cysts, in apparently the interior of which two or more were hanging by a common pedicle, which were, however, on outer side, and each contained the same elementary products, viz. roundish and spindle-shaped cells, with granules interspersed amongst very delicate matrix tissue.

The specimen exhibited differs from the former specimens in that it contains two growths closely contiguous, but differing in most respects from each other. The first, the oldest, is strictly analogous in composition and appearance to those by which it had been preceded. It lay deep beneath the skin surface, and in a situation between the cicatrices of the former removals and the axillary vessels. It was a growth of several months, and had reached the size of a large walnut when, in January, I advised its removal.

Circumstances, however, occurred which precluded the patient from following my advice until the 18th of February, when she became alarmed by the presence and rapid development of a second tumour, close to, but above and on the inner side of the first, and

bordering on the clavicle. It had reached a considerable size, had raised itself rather abruptly above the level of the surrounding skin, was two inches in breadth at the crest, a little less at the base, and of a deep purple colour from intense capillary injection. An ulcer had formed in its centre, with thick pouting or everted lips, and a deep cavity, from which an ichorous fluid constantly poured. There was still no glandular complication.

The new growth, whatever it was, had involved the skin; and between this and the healthy integument there were no exactly defined limits. Still, there was healthy skin at no great distance; and after consultation I advised the free removal of the two growths, although this proceeding required the leaving of a large and deep gap, which would have to be filled up by the granulating process.

This was acceded to; the patient made a good recovery, and at this date (July) the cicatrix and adjoining tissues are free from any evidence of returning disease.

I made an examination of the growths, but as they were referred to the Morbid Growths Committee,[1] I shall be content to give its report of their nature. I will, however, just say that the second tumour appeared to be an advance towards malignancy, and to present an illustration of a transition class of structure, between the simple recurrent and the absolutely malign, in a person clearly predisposed to the latter form of growth, partly by heritage (her mother died of cancer) and in part by the modifying influence of advancing age.

If the recurrence of these tumours, which, as we all know are very common, is explained by the facts I have endeavoured to relate, it will be clear as a practical inference that, in order to deal with them successfully, they should be removed as soon as they are recognised, and with considerable freedom as to contiguous textures, taking care especially to spare but as little as possible of their marginal fibrous appendages, especially of those which lie in the direction of the axilla.

The patient in this case, from being a pale, scraggy-looking and weakly person at the time she was first overtaken with these growths twenty years ago, has improved in health, and is now fairly healthy, well nourished, and strong. *May* 18*th*, 1880.

[1] See Appendix.

4. *Recurrent tumour of the breast removed seven years after first operation.*

By T. W. Nunn.

The patient was a lady, æt. 50. The tumour was not larger than a filbert, and had formed to the axillary side of the cicatrix of the first operation, but was independent of the cicatrix. It was moveable and unconnected with the skin. On section, the fibrous matrix is seen to contain loculi lined with epithelium, the epithelial cells being piled up, so as to have a columnar appearance, the cells being more adherent to each other than to the wall of the loculus, have, in the process of preparation of the specimen, shrank, leaving a space between their parietal aspect and the actual wall of the loculus, at the same time they enclose a space, thus a cystic arrangement obtains. Through the kindness of Mr. Curling, who operated in the first instance, and who had a microscopic examination made for him by Dr. Goodhart, I am able to quote Dr. Goodhart's report as follows:—" The growth is a cancer. . . . It is, however, not an ordinary form of scirrhus, but has apparently been in its onset a cystic disease into these (in some cases very minute) cysts, very vascular tufts of new growth had sprouted, and the breaking down of these had caused the bloody contents of some of the cysts." In the sections of the second growth some of the cysts contained an amorphous material, probably altered blood. The question is, what tissue has undergone the change described, a lymphatic or an outlying fragment of the mammary gland?

March 15*th*, 1880.

Report of the Morbid Growths Committee on Mr. Nunn's case of recurrent tumour of the breast.

We have had submitted to us two microscopical sections, both exhibiting the same characters. The growth is made up of stroma and cells of the epithelial type. The stroma consists of fibrous tissue, between the bundles of which are numerous elongated cells, and in many parts contains longitudinal streaks of blood-crystals, probably marking the course of obliterated vessels. Large vessels are seen running through the stroma, especially near the epithelial-covered surface.

The stroma encloses circular or irregular spaces of considerable size, lined sometimes by columnar, sometimes by more cubical epithelium, and for the most part filled with blood, or else showing evidence of having only lost their sanguineous contents during the process of mounting the specimen. In some of these spaces small villous projections are seen, covered with an epithelium similar to that before described. The structure of the growth thus corresponds clearly with that of the original tumour. It must be classed amongst the cancers, as it is obviously a modification of gland tissue, probably both of duct and excreting elements, which has a tendency to infiltrate surrounding structures and to recur after removal. At the same time it differs widely from any of the ordinary forms of scirrhus.

This variety of cancer is rare. A description of it will be found in Cornil and Ranvier's 'Manuel d'Histologie Pathologique,' p. 1166. Two similar cases have been recorded in the 'Transactions' of the Society during late years (*vide* vol. xxv, p. 224, and vol. xxvii, p. 270), both of which specimens came under our immediate notice. Though differing somewhat in various particulars these three tumours present the following characters in common:

1. A coarse stroma of well-formed fibrous tissue.
2. Large spaces lined with epithelium and often filled with blood.
3. The projection of villous growth into these spaces.
4. A tendency to infiltrate surrounding tissues.

MARCUS BECK.

May 10*th*, 1880. RICKMAN J. GODLEE.

---

5. *Myeloid sarcomata of lower jaw and rib; mollities ossium.*

By HENRY T. BUTLIN.

[With Plate XVII.]

J. L—, æt. 50, was admitted into St. Bartholomew's Hospital in June, 1877, with two tumours of the lower jaw, one of which had existed seven years, the other four years. Both were of small size and caused him but little inconvenience, and as he appeared to be in delicate health no operation was performed.

On the 27th of September he was again admitted, on account of a fracture through the neck of the left femur, the result of very slight violence, for it had occurred from the rolling over of a chair on which his foot was resting while he tied the laces of his boot. Almost from the time of the accident he gradually sank, and died at length with symptoms of an indefinite nature, for which we found it difficult to account.

At the *post-mortem* examination, two tumours, each about the size of a walnut, were found in the body of the lower jaw, one on either side, but not quite symmetrical. Both were of central origin, for a thin layer of bone covered a portion of the surface of each. Both were red and fleshy in appearance, firm and elastic in consistence, succulent, but not allowing juice to be scraped from the cut surface. The right sixth rib contained a tumour bearing precisely similar characters. Examined with the microscope all these tumours presented the characteristic appearance of myeloid sarcoma; around and between the giant-cells were spindle-cells (fig. 1). In the left side of the thorax, lying close to the spine, and attached to the fibrous tissue covering the vertebræ and bodies of the second, third, and fourth ribs, was an oval tumour, about two inches in diameter, perfectly encapsuled, white and fibrous in appearance. Its microscopic structure corresponded with its general appearance (fig. 2). No other tumours were discovered.

The femur was broken through its neck, and at the seat of fracture existed a cavity as large as a walnut, smooth-walled, and filled with partly clotted, partly fluid and diluted blood. The whole base was softer than normal, so that it could almost be cut with a knife, and was sawn vertically down the centre with a few strokes of the saw. Its cortex was less compact and more fatty than that of a healthy bone, while its medullary cavity was filled, partly with yellow fat, but chiefly with a red firm substance resembling that which formed the myeloid growths. The right femur presented similar characters, save that the red substance was more abundant; and in its head and neck was a cavity like that in the broken bone, but filled with thin clear fluid. The right humerus was in the same condition, and its head contained an elongated cavity filled with clear fluid. The calvaria was softened so that it could be easily bent between the thumb and fingers of one hand, but retained its elasticity, for it immediately regained its shape when the pressure was relaxed. Other bones examined were similarly

DESCRIPTION OF PLATE XVII.

This Plate illustrates Mr. Butlin's Case of Myeloid Tumours and Mollities Ossium. From drawings by himself. (Page 277.)

FIG. 1.—From tumour of lower jaw. × 240. [Hartnack, oc. 3, obj. 7, tube drawn out.]

FIG. 2.—From fibrous tumour of thorax. × 240.

FIG. 3.—Transverse section of humerus, showing Haversian canals filled with new growth and enlarged (with low power).

FIG. 4.—From red-coloured material in medulla of humerus. × 240.

FIGS. 5 and 6.—From medulla of femur. × about 240.



Fig I



Fig II

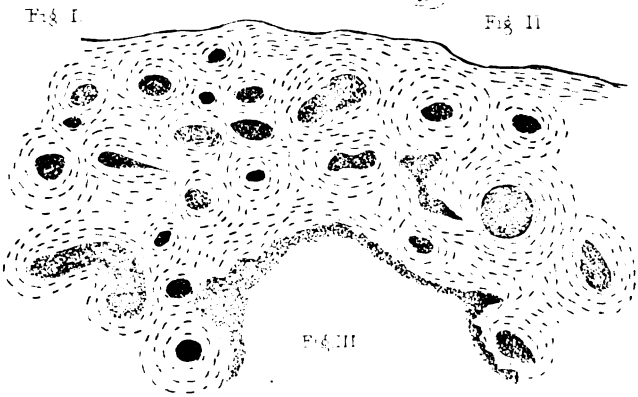

Fig III

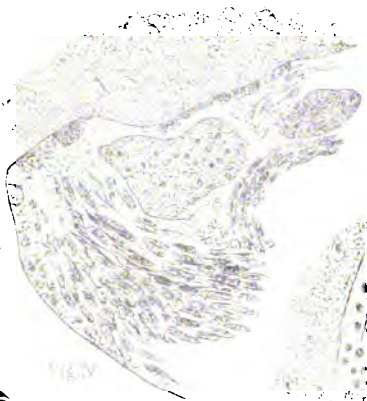

Fig IV

Fig VI

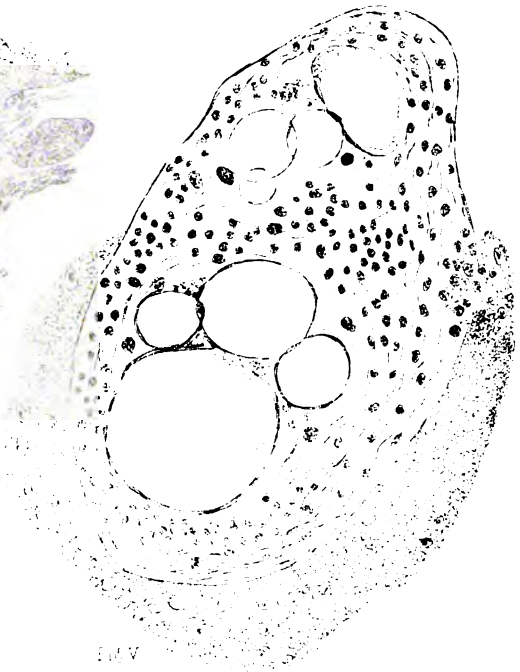

Fig V

soft and altered, except that they contained no cavities. Sections were examined of the humerus and femora. All presented characters essentially alike. The Haversian canals were widened out, the cancellous spaces were enlarged (fig. 3), and all parts were filled with a tissue composed of round cells like leucocytes, with which were mingled fat cells (figs. 5, 8, 6), or with a tissue composed of spindle and giant-cells like those of the myeloid tumours, but scarcely so well defined (fig. 4). This condition of the bones is singularly interesting on account of the presence of myeloid tumours in the jaw and rib. It may be explained on one of three hypotheses, first, as a fragility such as that which is sometimes recorded in cases of carcinoma, a condition of which I have no experience unless when the bones are actually filled with cancer. Second, as a general sarcomatous disease of many bones, producing tumours only in certain of them, but producing a myeloid material from which tumours might easily have been developed in many of them, a hypothesis favoured by the characters of the tissue in the bones, but negatived, I think, by the fact that this myeloid material was not everywhere coincident with the softening and alteration of the bones. Third, as due to mollities ossium, probably not connected with the myeloid disease. To this theory I incline, for the affection of the bones was very general, their characters both to the naked eye and with the microscope were such as are described in cases of mollities, even to the colour and firm consistence of the dark red substance, and the cavities in certain of the bones resemble those described and figured in a case of mollities ossium by Mr. Solly in the 'Medico-Chirurgical Transactions' for 1844 (vol. xxvii, p. 435). *October* 21*st*, 1879.

---

6. *Lympho-sarcoma (lymphadenoma) of the mediastinum involving the pericardium.*

By Frederic S. Eve.

Walter S—, æt. 20, was admitted to St. Bartholomew's Hospital, April 12th, 1878, under the care of Dr. Andrew, with the following history:

At Christmas he was attacked by pains in the stomach, sickness after food, and palpitation. For the last few months he had suffered from pain in the upper part of the chest, increased on exertion. There was dulness over the upper portion of the sternum, extending also outwards on either side nearly as far as the junction of the cartilages with the ribs, but further on the left than on the right side.

There was general pulsation over the præcordium and over the first and second spaces on the left side, close to the sternum.

May 2nd.—An attack of phlebitis of the left leg came on.

July 16th.—He was discharged at his own request. No marked change had taken place in the symptoms.

He was re-admitted October 1st. Some prominence of the upper part of the chest, to the left of the sternum, was noticed. There was fulness at the root of the neck on both sides. The physical signs were not materially altered.

He suffered from dyspnœa, with nocturnal exacerbations, and had a laryngeal cough. The right radial pulse was stronger than the left.

The symptoms of intra-thoracic pressure increased, and he died December 1st.

I am indebted to the house physician, Dr. Kidd, for the clinical notes.

Post-mortem.—A soft, brain-like tumour was found filling the mediastina and bulging forward from the base of the heart. The pericardium was infiltrated by the growth, and over an inch in thickness at the base, but gradually became thinner towards the apex. The inner surface of the thickened membrane was rugous and papillated; the sac of the pericardium contained sanious serum. The visceral layer of pericardium was not thickened. The heart was small but normal. From the base of the heart the growth extended along the large vessels, surrounding, and to some extent compressing, the arch of the aorta. The vagi were seen entering the mass of tumour, but the trachea, bronchi, and œsophagus did not appear to be compressed.

The mediastinal lymphatic glands and those at the root of the neck were much enlarged, soft, and conglomerated into masses.

With the exception of a small tumour connected with the xiphoid cartilage there were no secondary deposits.

Microscopic characters.—The growth in the pericardium was

composed of round (lymphoid) cells, resembling those in the diseased lymphatic glands but slightly larger. There was an abundant matrix of homogeneous connective tissue, and in places the growth was traversed by fine bands of delicate fibres.

In the enlarged lymphatic glands all distinction between the cortical and medullary portion was lost, and there was no trace of reticular tissue. The cells were embedded in a large quantity of gelatinous connective tissue. No multi-nuclear cells could be found.

Remarks.—The only remarkable feature in the specimen is the infiltration and great thickening of the pericardium. It is impossible to determine from an examination of the specimen itself, whether the disease commenced in the lymphatic glands or in the pericardium; but, from the nature of the disease and the tendency—shown in other cases reported—for the morbid growth either to extend directly to, or to implicate secondarily the serous membranes, there appears little reason to doubt that it originated in the lymphatic glands. The extension of the disease from the lymphatic glands to the serous membranes is not surprising when the intimate relation which the serous sacs bear to the lymphatic system is borne in mind.

These lymphadenoid growths appear to be an example of what is originally a simple hyperplasia, taking on all the features, clinically known as malignancy. In the simplest form—simple lymphoma—the growth is limited to the gland, or set of glands, in which it originated; in other cases it passes beyond the capsules of the gland, and infiltrates the surrounding tissues, extends along the lymphatic sheaths of the vessels, or invades the neighbouring serous membranes; while finally secondary growths at times occur in far distant organs.

November 14th, 1880.

7. *Lymphadenoma of the lymphatic glands, liver, spleen, lungs, and pleuræ.*

By Frederick Taylor, M.D.

Alfred M—, æt. 9, was admitted under my care into the Evelina Hospital in May, 1879. His mother is a delicate woman, aged thirty-four, but suffering from no special illness; his father has had rheumatic fever several times. As a baby he was suckled and partly fed until twelve months of age, and then fed with his parents. He is the eldest of the family. At the age of four or five he had whooping-cough, and measles six months later. This was followed by a discharge from the right ear.

The present trouble commenced six months before admission. Small lumps were noticed on the right side of the neck; these increased in size, and others were soon noticed in the right axilla, and one in the left axilla. He complained of some pain in the abdomen, which swelled. The bowels were rather confined, the appetite variable, and he had occasional nausea. On admission, he was a well-formed boy, with dark complexion, dark eyes, and brown hair. The glands on the right side of the neck, above the clavicle, and between the sterno-mastoid and trapezius muscles, formed a considerable prominence; they were soft, rather tender on examination, freely moveable under the skin and upon one another. There were none felt under this clavicle, nor in the suboccipital region; but there were similar masses in the right axilla, in the left axilla, and above the left clavicle, of which that in the former situation was the largest. The veins over the right pectoral region were conspicuous. The liver was not felt, but the spleen reached just below the left ribs, and on deep inspiration projected about three quarters of an inch; the edge was hard, but not rounded or apparently thickened. Examination of the chest showed slight dulness of the right apex posteriorly, feeble respiratory murmur generally over the right chest, and some crepitation in the right axillary line. The heart presented no abnormal sounds. The urine was clear, of a pale straw colour, of specific gravity 1012, acid, free from albumen, but with a slight excess of phosphates.

Towards the end of June the glands on the right side of the neck were somewhat larger; individually they felt harder, and were tender,

There was much fulness below the clavicle, and the veins in this neighbourhood were large, and the sternal end of the clavicle was distinctly pushed forward. The mass in the right axilla was somewhat larger, that in the left axilla seemed unaltered; nothing was perceptible in the groins. The right side of the chest was now somewhat dull in front under the clavicle; the heart was normal in position and sounds.

On July 10th it appeared that the glands on the right side of the neck were larger, extending under the sterno-mastoid to its anterior border; the individual glands seemed to be of the size of Spanish nuts. On the left side there was one gland in front of the sterno-mastoid, others above the clavicle, and another at the posterior border of the muscle higher up. Below the clavicle the pectoral muscle was apparently pushed forward by something behind it, and the left axillary glands had increased in size. The right axillary mass had also increased, and appeared to be composed of one or more large glands. All the glands were tender. The physical signs of the chest had considerably altered. There were now, right front, from clavicle to hepatic region, dulness, with rather faint bronchial breathing and bronchophony; right back, crepitation at the apex. Left front, dulness from above the clavicle to the second space, and along the left border of the sternum, with crepitation over this area; below this, short high-pitched resonance, with supplementary breathing. Left back, bronchial breathing and crepitation at apex. The spleen and liver were felt lower in the abdomen than formerly. The finger tips were thickened, the skin tense and shining, the nails very convex.

At the end of August he was getting thinner; all the glands appeared somewhat smaller and not so tender. He had had occasional epistaxis, was anæmic and sallow. He had, however, a good appetite, slept well, and was free from cough or undue perspiration.

In September the condition of the right chest became more serious, as it obviously contained fluid by which his breathing was much hampered.

On September 16th the physical signs were as follows:—Right front, complete dulness from clavicle to hepatic region, with bronchial breathing over the whole area, and deficient tactile vibration, most markedly below; right back, dulness to angle of scapula, resonance impaired above this, breathing faint and imperfectly bronchial, with absence of tactile vibration over the dull

area: above, deficient vesicular murmur, mixed with crackling râles. Ægophony at the angle of the ninth rib. Left front, dulness under the clavicle and along the sternum, continuous with the dulness of the right side; the breathing was bronchial near the clavicle, supplementary below the outer half of the clavicle and towards the axilla. Left back, resonance slightly impaired, breathing supplementary. The liver was much displaced downwards.

On the 18th the right chest was punctured posteriorly, and eight ounces of clear fluid were withdrawn. The relief was but slight. He continued restless at night, with hurried respiration, and occasional slight cough. He lay mostly on the right side, and had now œdema of the right eyelids, right arm, and chest and scrotum.

On the 26th the feet also were œdematous, and he was more distressed. He had cough, without expectoration, occasional slight epistaxis, and dry, hot skin. The physical signs of the chest were much the same, with the addition of sibilant and crackling bronchitic sounds. The heart sounds were regular, but distant. The glands in the axilla were somewhat tender, and the skin over them was reddened. All the other glands appeared larger, and the pectoral veins were more prominent. The abdomen was distended, and the spleen reached the level of the umbilicus. Three days later (September 29th) he died.

The temperature during his illness fluctuated considerably. On May 7th (two days after admission) it rose nearly to 104°, continued about 103° till the 10th, and then fell during four days to 98°; continued normal till the end of May; rose suddenly in the first days of June to 103°, and fell remittingly till the 10th, continuing to be 98° in the morning, and 100° in the evening, until the 20th. From this date till July 18th it formed a curve, reaching 103° at its summit, June 29th to July 8th, with but little difference between morning and evening records. For a few days the temperature was normal, then formed another curve, beginning July 24th, reaching 102°—103·5° between July 28th and August 9th, and falling to 100° on August 15th. From this until the 30th it was scarcely above the normal; it then again rose, reaching its highest, 103·6°, on September 18th, and gradually fell till death. A certain amount of correspondence was observed between the condition of the glands and the variations of the temperature. Thus the glands were painful

on admission when the temperature was high, and less painful during the remission of May. They were noticed to be larger during the elevation of June 20th to July 18th. They were again noticed to be "not so large" and to seem smaller on August 27th, after twelve days normal temperature; and they were swollen and tender after ten days, during which the temperature had been rising. There was no leucocythæmia. The quantity of hæmoglobin was from 65 to 80 per cent. of the normal on May 19th, and 75 per cent. on July 25th.

The *post-mortem* examination was made nine hours after death, and the following conditions were found:—Enlargement of the cervical, axillary, mediastinal, and mesenteric glands; extensive effusion in the right chest, with compression of the lung; effusion in the pericardium; new growths of adenoid structure on the pleura, on the pleural surface of the lung, in the liver, and in the spleen.

Lymphatic glands.—Externally, the most prominent were those of the right axilla, and the right side of the neck. The glands in the right axilla formed a mass four or five inches in diameter, which extended deeply into the axilla between the subscapularis and serratus muscles, and also turned over the axillary border of the scapula to overlie the infra-spinatus. These glands were more or less continuous with those of the neck by a chain of glands under the clavicle and pectoralis; and the same condition existed on the left side. The glands in all these situations were of different sizes, from that of a bean to that of a hen's egg, one in the right axilla measuring two inches in diameter. They were united together by connective tissue, and were freely moveable upon one another. On section they were white, semitranslucent, with some more opaque spots, moderately firm to the touch, but not cheesy.

On opening the chest, it was seen that the glands about the trachea were continuous with an enormous mass, which surrounded the base of the heart, the great vessels, and the root of each lung. All the glands in this neighbourhood were involved, and many reached a great size. Posteriorly the œsophagus was pushed to the left by two large glands measuring each two inches in diameter; in front the veins and arteries were entirely concealed, but though their walls were no doubt pressed upon, they were not invaded by any new growth. In the abdomen the mesenteric glands were generally enlarged, the largest being about the size of a hazel nut.

Lungs and pleura.—The right chest contained a considerable quantity of fluid; it was not measured, but was probably a pint or more. The right lung was compressed against the mediastinum, but was connected to the pleura in the axillary line by a band of adhesions an inch and a half in length and one inch in vertical height. In this band of adhesions were numerous (twelve or more) small spherical growths of a white colour, the largest the size of a pea. Growths of the same size and characters were scattered over the surface of the lung, and were partly scattered, partly arranged in groups, over the parietal pleura under both ribs and sternum. On the left side the pleural cavity was normal. Both lungs were healthy in structure, and presented no gland-like growths in their substance.

Heart.—The pericardium contained from eight to ten ounces of fluid. There was no pericarditis, but at the base, at the point of exit of the aorta and pulmonary artery, were a few masses of new growth. The heart was healthy, and free from vegetations or other valvular disease.

Abdominal organs.—The liver was large, and mostly normal on section, but presented a few small white nodules, about a line in diameter; and in the centre one lobulated spherical white mass two thirds of an inch in diameter. The spleen was large, measuring five inches by three inches, and was irregular on its surface from the presence in its substance of numerous small nodules, which shone white through the capsule. A section showed that the nodules, which averaged one fifth of an inch in diameter, were scattered uniformly through the organ and formed about half its bulk. The kidneys were healthy, weighing nine and a half ounces. Microscopically, the hypertrophied glands, and the growths in the liver and spleen, showed the structure characteristic of lymphadenoma.

Remarks.—The above is a typical case of lymphadenoma or Hodgkin's disease. It presents two points worthy of note: clinically, the connection between enlargement of the glands and increase of temperature; pathologically, the growth of nodules of new growth in the bands of adhesion between the two pleural surfaces. It was obvious that old adhesions had existed between the lung and the chest wall, that these had become stretched by the effusion of fluid, and that subsequent to this, the nodules of lymphadenoma had formed in the fibrous bands. *Nov. 4th,* 1879.

DESCRIPTION OF PLATE XVIII.

FIGS. 1 and 2 illustrate Mr. W. H. Cripp's Case of Cartilaginous Tumour of Arm. (Page 287.)

FIG. 3 illustrates Mr. Eve's Case of (so-called) Aneurysm by Anastomosis of the Ear. (Page 88.)

FIG. 1.—Section of a loose nodule of a cartilaginous tumour, showing masses of homogeneous material thickly studded with cartilage cells, enclosed in well-formed fibrous trabeculæ.

FIG. 2.—A portion of the same under a higher power.

FIG. 3 represents a Section of the Injected Pinna in Mr. Eve's Case, figured in Plate III. It shows the capillary anastomosis.

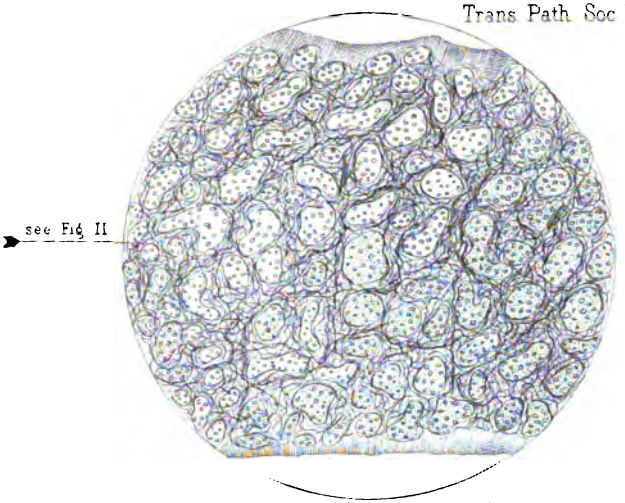

Fig. I. (Hartnack No. IV.)

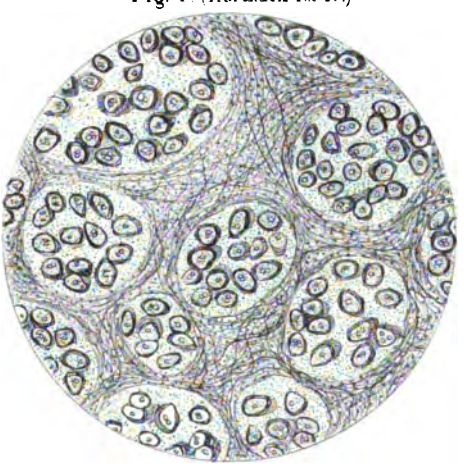

Fig. II. (Hartnack No. IX.)

B.H.Cripps del

Sections of Cartilaginous tumor.

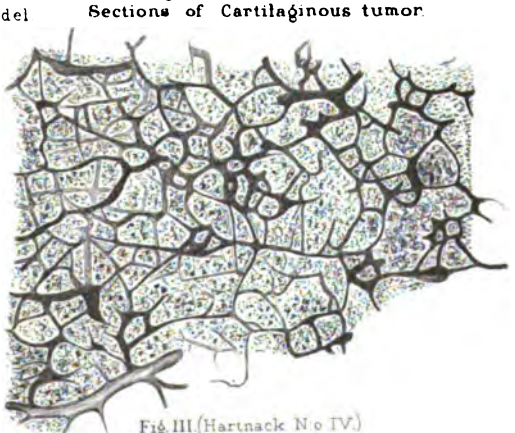

Fig. III. (Hartnack No. IV.)

Aneurism by Anastomosis. (See Pl. III.)

8. *Cartilaginous tumour of arm.*

By W. HARRISON CRIPPS.

[With Plate XVIII, Figures 1 and 2.]

THE patient from whom this tumour was removed was a healthy young woman, æt. 28. The growth had been noticed for six years, during the last two of which it had not increased in size. It was situated in the upper third of the right arm immediately beneath the skin, which was healthy and moved freely over the tumour. The tumour itself, which was exceedingly hard, was fairly moveable in the deeper structures. It was pyriform in shape, the thin end being towards the axilla. It was three and a half inches in length and two in diameter in its thickest part. In the axilla were three or four hard nodules the size of small nuts. The tumour, which was removed by Mr. Smith, consisted of a nodular mass of cartilage enclosed in a capsule. Besides the main tumour were a dozen or more completely detached lobulated bits of cartilage from a quarter to half an inch in diameter. These portions were contained within the capsule, but fell out when the capsule was opened. They fitted most accurately like a Chinese puzzle, the one against the other. The detached nodules in the axilla proved to be similar detached portions of cartilage. These detached portions were of a beautiful glistening white. Fig. 1 represents a section cut from one of these loose nodules. It consists of a fairly marked fibrous trabeculæ, which enclose a number of spaces filled by a dusky granular matrix in which cartilage cells are clustered (see fig. 2). In the centre of some of these nodules was some hard calcareous matter. *Dec. 2nd*, 1879.

---

9. *Fatty tumour of abdomen, showing fibrous and osseous changes.*

By J. DRESCHFELD, M.D.

THE specimens exhibited were three tumours removed from a female, æt. 49. The history of the case is briefly as follows: The patient, a married lady, who had always been in the enjoy-

ment of very good health, first consulted Mr. F. A. Heath, senior surgeon to the Manchester Infirmary, in the year 1876, for a swelling in the left lumbar region. On examination, a hard globular swelling was found, evidently intra-abdominal, freely moveable and painless, the exact connections of which with the neighbouring organs could not be made out. As the tumour gave rise to no troubles, nothing further was done. In 1878 the patient again consulted Mr. Heath, and now a second tumour was detected, situated in the right lumbar region, painless on pressure, moveable, and again seemingly not in connection with any of the abdominal viscera. Soon after the patient began to suffer from abdominal tenderness, loss of flesh, and anorexia. It was then considered advisable that the removal of these tumours should be attempted, and accordingly on October 18th, 1879, Mr. Heath proceeded to operate. After having opened the abdominal cavity a small osseous tumour was found in the left lumbar region, it seemed enclosed in a dense fibrous capsule, but as no connections with any of the neighbouring organs could be made out, the capsule was partly stripped off the tumour, then tied, and was returned as a sort of pedicle into the abdominal cavity. The tumour on the left side was got at with some difficulty; it was found to be a firm fibrous mass, surrounded by a thin capsule, and seemed connected with a large fatty mass at the back of the abdomen by some fibrous tissue. As the patient had now been under chloroform for a considerable length of time, and as the extent and size of the fatty mass made its removal a matter of great difficulty, Mr. Heath, after having tied the fibrous connection between the fibrous tumour and the mass of fat, removed the fibrous tumour only, and abstained from any further operative interference. The patient did well the first few days, but died from shock and peritonitis on the fifth day after the operation; and *post-mortem* there was taken out an enormous fatty tumour, weighing twelve pounds, attached to the back of the abdomen, stretching across from left to right, filling up the hollow along the spinal column on the right, and extending down into the pelvis on the left side; the left kidney was pushed to the right and lay on the right border of the tumour. On the anterior surface of the tumour the ligatures were found which had been tied round the quasi-pedicles of the smaller tumours, showing that the two smaller tumours were connected originally with the large fatty tumour. As a further evidence of their common origin a number

of small bony masses were found near the point of attachment of the bony tumour to the fatty mass, and the second or fibrous tumour was found on section to be partly fatty and partly fibrous in structure. Microscopically, the large fatty tumour showed the structure common to all lipomata; the small osseous masses embedded in it showed no Haversian canals, but large, irregularly arranged bone corpuscles, and a bony matrix. The osseous mass, twelve ounces in weight, was globular in shape and of ivory hardness; it was still partly covered with a dense fibrous membrane, in which a number of blood-vessels ramified, which were seen to pass into the substance of the bony tumour; the lowest layer of this fibrous membrane was made up of several layers of osteoblasts. On section the tumour was seen to be exceedingly dense and to be made up of bony matrix and bone corpuscles, arranged in lamellæ. Blood-vessels were found in the peripheric part of the tumour, where they seemed to lie in spaces, not unlike Haversian canals, whilst the greater part of the mass showed no vestige of vascularity. The fibrous tumour, found on the left side, weighed fourteen ounces; it was distinctly lobulated and surrounded by a fibrous capsule, which, passing in between the several lobules, formed fibrous septa. Microscopically, this tumour was found to be of mixed character; some parts were composed of tissue corpuscles, nuclei, fibres, and fully formed blood-vessels; in other parts the fibrous tissue was more of the embryonic type, the cellular elements predominating, while other parts again were composed of large fat cells enclosed in fibrous septa, with but a sparing supply of blood-vessels, and but few tissue corpuscles; it was evidently a lipoma undergoing a fibrous change.

Remarks.—The tumour is interesting in several ways. Large fatty tumours in the abdominal cavity are, in themselves, very rare, and in the 'Path. Transactions' only two such tumours are reported ('Path. Trans.,' vol. xix, pp. 243 and 246). Again, while fatty tumours often undergo calcareous degeneration, true ossification in a fatty tumour is a very rare event, and still more rarely is it found that one part undergoes fibrous change and the other part osseous change, and that the parts so changed should become so detached from the original mass as to form separate tumours. The tumour itself had probably originally sprung from the serous membrane.

10. *Diffuse (?) sarcoma of liver, probably congenital.*

By Robert William Parker.

The specimen was removed from the body of an infant, aged five weeks. When the child was three weeks old Mr. Meredith Townsend, of Kensington, was asked to see it on account of a swelling and hardness of the abdomen. Nothing unusual had been noticed since the birth except that every now and then "it drew itself up and cried out." I saw the child a few days later. There was no jaundice, nor had there been any. The child was rather a small one and it was thin and wasted. A satisfactory history of syphilis could not be obtained.

The child's abdomen was distended and hard, and in the region of the liver, uneven on its surface: a few large veins were seen ramifying over it. On palpation, a hard substance could be distinctly felt, it began in the liver region, and reached quite over to the opposite side of the body, and down as low as the iliac crests. Below the umbilicus there was a very small area of resonance, but elsewhere the whole abdomen was dull on percussion. This dulness did not vary with change of position. Fluctuation was not detected. There was a slight œdema in the lower extremities, as well as, though to a less extent, in the abdominal walls. Mercurial inunctions were tried on the chance of its being a syphilitic new growth. The child died, when aged five weeks.

A partial autopsy was made seventy-two hours after death. The body was much wasted, the subcutaneous fat was all gone. The bones all appeared to be normal. The liver filled the abdominal cavity almost entirely; it weighed 32 oz. When first removed, it was of a dark plum colour, mottled over with patches of yellowish tint, corresponding, when cut into, to a new growth, which was largely diffused through the whole liver. This dark colour quickly changed to a bright scarlet after removal of the liver from the body. It was obviously due to the presence of blood, with which the organ was distended, and which gradually drained away from it after it had been cut into. The new growth was scattered throughout the entire gland as nodules, varying in size from a millet seed to a walnut. It looked not unlike caseous material, but it could not be shelled out from the liver substance. The upper

surface of the organ was irregularly, though slightly nodulated; its capsule was shiny, and did not appear to be thickened. The left lobe was quite as large as the right, and both of them were almost circular in outline. The under surface was peculiar, in that the usual subdivisions were less well marked than is common, and there were several nodules of new growth projecting from it. The gall bladder was rudimentary, it did not appear even to have contained bile. The vessels were normal.

The intestines were very bloodless, they were empty.

The right kidney was normal.

The spleen was normal as to appearance and position.

The left kidney was small; this organ and the preceding one were connected together by a mass of new growth as large as a Tangerine orange, which, however, nowhere invaded their substance. This mass was the only bit of secondary growth which was found; in general structure it corresponded with that in the liver, being very vascular and soft. The lungs were pale; there were, along the borders of the lobes, patches of (? congenital) atelectasis.

Heart.—The foramen ovale was quite patent, but otherwise normal.

Uterus and ovaries appeared healthy.

A microscopic examination shows it to consist of round cells held together by a delicate connective tissue; the cells are considerably larger than blood corpuscles, and are granular for the most part. The intercellular substance varies a little in quantity, but it is nowhere very abundant. The proper gland cells of the liver cannot be made out in any of the many sections I have examined. Even in places where there is no obvious naked eye change, the liver substance is infiltrated with a dense small cell deposit, which quite obscures the liver cells even if they are present. There are numerous patches of blood extravasations, around which, in many places, there does not appear to be any containing membrane; elsewhere, however, the vessels appear distended with blood, and hence I conclude that the extravasations are all distended vessels. Towards the peripheral portions of the liver the growth is divided into spaces by strands of connective tissue, which is sometimes nucleated. In these places there is an abortive appearance of portal zones (lobules), but it is very indefinite.

I have called this growth a round-celled sarcoma. But it is open

to members to suggest that it may be a syphilitic new growth. It is, however, not usual for syphilis to manifest itself in this form, and it must further be remarked that a history of syphilis in the parents could not be obtained, and that the infant did not manifest any other symptoms of congenital disease but this; if syphilitic, it would I think be remarkable that the disease should have been strictly confined to one organ of the body, for the spleen and kidney have been examined without presenting any traces of a similar new growth. It is unusual also for syphilis to be accompanied by a secondary deposit in the retro-peritoneal glands similar to the one I have described. I would also add that it was in no way affected by the mercurial treatment which was ordered on the chance of its being syphilis. This I consider important as regards diagnosis, for if there be one point more remarkable than another in congenital syphilis, it is the readiness with which it is influenced by a mercurial treatment. The size of the cells too is rather unlike what is found in syphilis, and the great vascularity of the growth is, I venture to believe, unlike the generality of syphilitic neoplasms. In no place is there any trace of retrogression, or of those changes which usher in cirrhosis. On the whole, therefore, I am inclined to regard it as a sarcoma; for it (sarcoma) is well known to occur congenitally as well as during early infancy.

Contrary to syphilis, sarcoma commonly does affect a single organ; it is accompanied by secondary deposits not infrequently, and it is in no way (as in the present instance) under the control of treatment. Further, considering how largely mesoblastic elements enter into the formation of the original liver, there will be no histological difficulty in accepting this view.

I have ventured to say congenital sarcoma, not only on account of its extent and general distribution throughout the entire gland, but also on account of the youth of the patient. When attention was first drawn to it it was only three weeks old, and the liver was then of considerable size, seeming to fill the entire abdomen, and the child was rather less than five weeks old when it died. One can scarcely conjecture how early during intra-uterine life this morbid tendency began to manifest itself; but, in view of the entire absence of liver cells and of liver function, as largely evidenced by the undeveloped gall bladder, and also by the absence of bile, which is normally present during the seventh month, I should regard it as of a very early date. This view, it seems to me, is strengthened by

the circular shape and equal size of the right and left lobes, which during their earliest periods are almost identical in these respects.

Under these circumstances we shall have to regard the disease less as *a reversion* to the embryonic type, than as a *persistence* of that type into extra-uterine life. *May 4th*, 1880.

---

11. *On some of the appearances observed in a case of cancer of the liver.*

By George Thin, M.D.

[With Plate XX.]

It is my intention to illustrate by the drawings which accompany this paper the changes which were observed in the liver cells in a case of cancer of the liver. The specimens from which they have been drawn were prepared from the large cancerous liver of a woman who died in the Middlesex Hospital. The cancer of the liver was secondary to a cancer of the breast, which had been operated on by Mr. Henry Morris. It is a feature of interest in the case that before a tumour was felt in the breast there had been long standing disease of the skin of the nipple and areola, the disease to which Sir James Paget has drawn attention, as being associated with the development of cancer in the mamma.

The liver was a large one and very thickly infiltrated with cancerous deposit. The parts examined were chosen from the borders of these cancerous masses, and the sections were made through the margin, including therefore the cancerous and the contiguous non-cancerous elements.

The cancerous infiltration consisted of epithelial cells arranged in columns, and was seen in section to be composed of circular or elongated cell-groups (figs. 5 and 8). The cells were rounded or polygonal, and were none of them large. They were usually seen so welded together that the outlines of the individual cells were obscured, but those that were sufficiently isolated to be distinctly seen had the shape I have mentioned. A line of demarcation between the cancer cells and the liver cells was observed in all the sections examined.

Usually the liver cells near the cancerous deposit were filled with vacuoles, from which probably fat had been removed by the hardening fluids, and many of them were broken down and disintegrated to such an extent as to be with difficulty recognised. The fatty degeneration of the liver cells was found at a comparatively considerable distance from the cancer, and no perfectly healthy liver cells were seen. Sometimes a column of cancer cells touched a row of liver cells, and appeared continuous with it, but this apparent continuity depended on the connective tissue not being disturbed, the column of cancer cells advancing on a delicate band of connective tissue from which the liver cells had disappeared. It was always possible in preparations doubly stained with eosin and logwood to observe where the last liver cell ended and the first cancer cell began. The cancer elements were specially stained by the logwood. There was no division of nuclei amongst the liver cells, and no appearances indicative of any other change than that of disintegration. The nuclei of the cancer cells were larger than those of the liver cells.

The result of an examination of the specimen has shown that in this case the cancer development took place without any implication of the liver cells. *May* 18*th*, 1880.

---

12. *On the histology of a cancerous tumour of the mamma.*

By George Thin, M.D.

[With Plate XIX.]

Rebecca S—, æt. 28, the mother of five children, was admitted into King's College Hospital, under the care of Professor Lister. A note furnished me by Mr. Davidson, the house surgeon, states that:

"Three years before admission the patient first noticed shooting pains in the left breast, emanating from a small lump about the size of a hazel nut. On admission, she had a tumour about the size of a small orange on the inner side, and one about the size of a nut somewhat below and two inches nearer the middle. There was much pain in the smaller tumour. The skin over the larger lump was adherent, and the tumour was moveable over the subjacent

DESCRIPTION OF PLATE XIX.

Illustrating Dr. Thin's paper on the Histology of a Cancerous Tumour of the Mamma. (Page 294.)

FIG. 1.—Early changes in the gland structures of a lobule. × 95.

FIG. 2.—Part of the border of a cavity, from which a cell-mass has fallen out. × 240.

FIG. 3.—The cavity referred to in the description of Fig. 2.

FIG. 4.—The cell-growth in a lobule, in a more advanced stage than is seen in Fig. 1. × 70.

FIG. 5.—Showing, as seen under a low magnifying power, the distribution of isolated cell-masses and cavities. × 14.

Fig. 1.

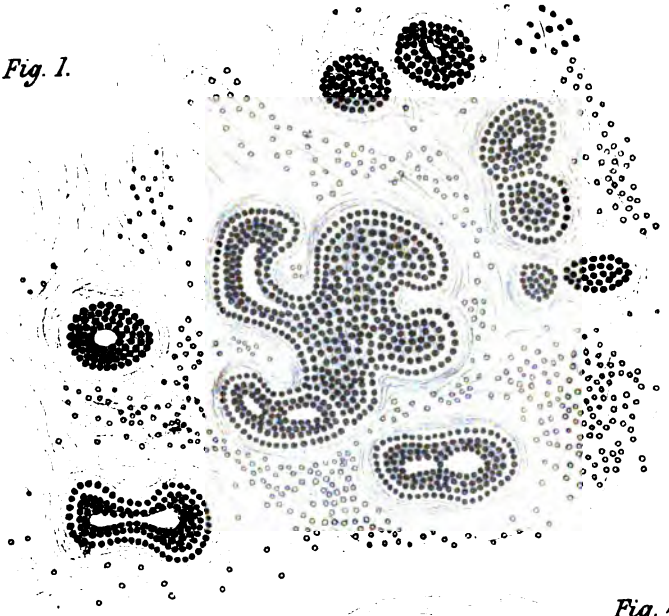

Fig. 4.

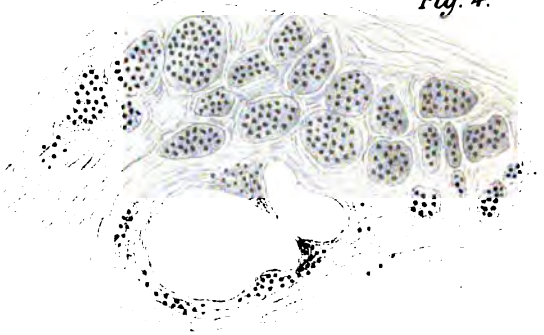

Fig. 2.

Fig. 5.

Fig. 3.

G. Thin, del.

F Huth, Lith.r Edin.r

DESCRIPTION OF PLATE XX.

Figures 1, 2, 3, and 4 illustrate Dr. Thin's paper on the Pathological Histology of Elephantiasis. (Page 337.)

Figures 5, 6, 7, 8, and 9 illustrate Dr. Thin's paper on some of the appearances observed in a Case of Cancer of the Liver. (Page 293.)

ELEPHANTIASIS:

FIG. 1.—Cells seen scattered through different parts of the elephantiasis tissue. × 500.

FIG. 2.—A cell lying on a loosely connected bundle of fibrous tissue. × 500.

FIG. 3.—Cells in the midst of the elephantiasis tissue, having an endothelial-like arrangement. × 500.

FIG. 4.—(To illustrate the nature of connective-tissue cells in the normal tissues.) Cells in the subcutaneous tissue of the mouse, fixed by interstitial injection of solution of nitrate of silver before the tissues had cooled. × 250.

CANCER OF THE LIVER:

FIG. 5.—Section through the cancerous growth. × 45.

FIG. 6.—*a* and *b*. Isolated degenerating liver-cells. *c*. Several degenerating liver-cells in continuity. × 250.

FIG. 7.—Illustrating further the degeneration of the liver-cells. × 250.

FIG. 8.—*a* and *b*. The columns of cancer-cells, seen lengthways. *c*. Columns cut transversely. × 250.

FIG. 9.—Illustrating the relations of the cancer growth (*a*) to the liver-cells (*b*). × about 150.

Fig. 1.



Fig. 4.

Fig. 2.

Fig. 3.

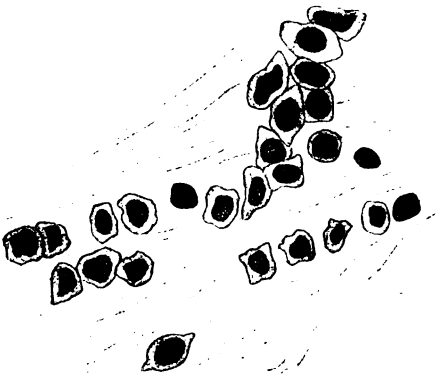

Fig. 6.

Fig. 5.

Fig. 7.



Fig. 8.

Fig. 9.

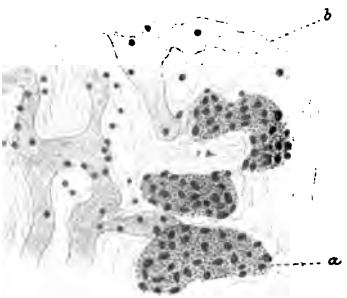

G. Thin, del.

F. Huth, Lith^r Edin^r

structures. The nipple, from which there had been a slight discharge, was retracted.

"The glands in the axilla were enlarged, but not those above the clavicle.

"The breast was removed on March 10th, and the patient discharged on April 1st."

I examined a portion of the larger tumour, the part examined being on the border of the growth and surrounded by healthy tissue.

This part of the tumour was composed of a number of small nodules about the size of a pea and less.

The nodules were composed of an epithelial growth which had the following characteristics :

The epithelial elements were grouped in columns, which were mostly solid but sometimes had a central lumen. A group was sometimes formed by only a few large round masses, and sometimes a single large round cell-mass was found isolated. The cells from the larger masses had frequently fallen out, leaving either an empty space in the connective tissue or a round hole lined with a single layer of cells.

The cells were small and rounded. The nuclei were round and of uniform size.

The epithelial clusters had formed in the region of a lobule. The following different appearances observed in different lobule-areas form, I consider, so many transition stages. Lobules were observed in which the cells of the terminal vesicles of the acini were more or less broken down; in others, instead of the normal vesicles, round solid columns of cells, with sometimes a central lumen, were found ; in a still more advanced stage a few large solid columns of cells filled the area. In all these stages a considerable amount of cell infiltration was present. Occasionally one large circular or oval cell mass was found, equal in area to a small lobule. In the large cell masses the central cells were sometimes found to have degenerated to an extent that made them only recognisable by a comparison of transition stages. The cells in this change become agglutinated and form an amorphous granular mass, which stains differently from the less altered cells.

Several solitary round cell masses were observed, of a smaller size than the large masses last mentioned, a single line of cells bounding a centrally situated mass of cells which had undergone the peculiar form of degeneration to which I have just alluded.

These were evidently enlarged galactophorous ducts blocked with cell *débris*.[1]

The sections examined did not suffice to determine whether new cell growth in a lobule took place from the columnar epithelium of the ducts or from the secreting cells, but the tumour is similar to a tumour I have examined and described in a paper read before the Royal Medical and Chirurgical Society, in which the origin from the columnar cells of the ducts was observed.

The structure of this tumour differs from that which distinguishes cancers which take their origin from the secreting cells of the acini, and of which a large proportion of the cancers diagnosed as scirrhous are composed, in the following negative features. The circular cell-masses, when they are once formed, show little disposition to extend into the surrounding connective tissue. The soft intralobular connective tissue soon yields and breaks down, but the strong interlobular tissue resists the epithelial growth so successfully that for a considerable time the morbid changes are limited to the lobule areas.

All the growths tend to assume a circular form (as seen in section), the coalescence of several smaller columns not much modifying this tendency.

There is a tendency to the disposition and form of a columnar epithelium in the outermost layer of cells, with in some places well-marked sub-columnar cells.

In some of the new cell growths sections of rounded columns of cells show a central lumen, producing the appearance that is supposed to be characteristic of the tumour described as adenoma or chronic mammary tumour.

There is a greater uniformity in the size of the nuclei and a feebler power of resistance in the cell substance than is the case in the commoner form of scirrhous tumour. This quality gives rise to a distinctive appearance, produced by agglutination, granular degeneration, and a chemical change in the central cells of the masses.

The most distinctive feature in these tumours, and that which separates them specifically from the common cancer, which takes

[1] This peculiar product of cell degeneration stains deeply with eosin. I have found it in several breast tumours which belonged to the same class as the one I am now describing.

origin from the parenchymatous cells, is the disposition to form columnar epithelium.

Whilst they differ specifically from the parenchymatous or ordinary scirrhous cancer, they differ only in extent and rapidity of development from the tumours known as adenomas or adenoid tumours.

I have thought the present case worthy of being recorded as an illustration of these points. Leaving out of consideration the age of the patient, the history and symptoms are those which surgeons consider to be characteristic of scirrhus. The histology of the growth shows it to belong to the group of tumours to which I have alluded, and which I designate duct cancers, whilst in some parts the structure was identical with typical forms of so-called adenoma. The term scirrhus would clinically be applicable to the tumour, as I am informed it would have been to the naked eye appearances of the centre of the growth, which I had not an opportunity of seeing. Histologically it would, I believe, be generally called an adenoma or adenoid tumour. Cases like this show, in my opinion, that the terms scirrhus and adenoma are apt to lead to confusion. The great majority of tumours which are called scirrhus differ histologically from this one, and if this tumour could be called a scirrhous tumour, the term would be made to cover two kinds of epithelial growth in the mamma which are distinct from each other.

The term adenoma is used to designate a kind of tumour in the breast which is usually benign in its nature and which does not infect the lymphatic glands. But, although this tumour had the anatomical structure which characterises the majority of these non-malignant tumours, it was growing rapidly, was painful, infected the axillary glands, and clinically would, I presume, be called by most surgeons a cancer. If the use of the term adenoma, as expressing the idea of a definite epithelial growth, is retained, it will have to cover not only chronic non-infecting growths, but tumours that grow rapidly, and infect the lymphatics.

The commoner form of malignant cancers of the breast have been found by Waldeyer and others to originate in the parenchymatous epithelium; the cancer, of which I have just described an example, has been found by Waldeyer and myself[1] to originate in the lactiferous ducts. I am not aware that observers who have described the structure of so-called adenomatous growths from

[1] And I believe other observers whom I am unable to cite.

examples taken from chronic non-infecting tumours (the adenoma *par excellence* of most English pathologists), have traced the first departure from the normal epithelium, but if I am correct in thinking that the tumour I have just described is of the same species histologically as these adenomas, then I believe it to be a matter of fair inference that they all take their origin in the duct epithelium.

In substituting another name for that of adenoma, which, I think, on grounds already stated, to be open to objection, expression may be given to two available features. One is, the tendency to the formation of columnar epithelium, and the other is the origin from the ducts. The reproduction of columnar epithelium of a marked type would not appear to be constant, whilst the origin from the columnar epithelium of the ducts, thus ascertained to occur in a certain number of instances, may be legitimately inferred to be constant. The terms parenchymatous cancer and duct cancer would, I believe, give expression to conditions that are invariable, and would designate the source from which each of the two varieties of new epithelial growths in the mamma take their origin. *May* 18*th*, 1880.

---

13. *Epithelioma of the penis.*

By T. W. Nunn.

The specimen was removed from a gentleman, æt. 70. The section shows a luxuriant cell growth developing on the surface into papillæ, and deeper in the substance of the growth into loculi filled with cells as in scirrhus, but without the fibrous matrix proper to that form of cancer. The disease had commenced six months previously as a small wart, which gradually covered the greater part of the glans penis and the prepuce. The prepuce had been habitually retained forwards, covering the glans.

March 15*th*, 1880.

---

14. *Melanosis of the little finger.*

By T. W. Nunn.

The specimen was a section from a melanotic growth on the little finger of a lady, æt. (about) 50, the finger having been removed by operation. For many months before the operation there had existed on the inner side of the finger a patch of discoloration like an ecchymosis, the size of a fourpenny piece, which, however, remained quiescent. Towards the autumn of 1879 this began to discharge, and as the winter came on, rapidly grew in thickness. The patient, it may be mentioned, was a person of unsound mind.

The section shows what was an active cell-growth *interspersed with the obsolete pigmented cells of the original* discoloration, as though a sudden stimulus having arisen in the structures the distinctly cancerous character rapidly developed itself.

There were no enlarged glands either at the bend of the elbow or in the axilla. *March 15th*, 1880.

---

15. *Myxo-sarcoma of the spermatic cord removed from a child thirteen months old.*

[With Plate XXI, Fig. 2.]

By W. J. Walsham.

This specimen was sent to me by my friend Mr. Anderson, of Nottingham, accompanied by the following history:

"W. R.—, thirteen months old, came under treatment May 7th, 1879, with a tumour, situated partly in the groin and partly in the scrotum.

"The mother said she first noticed it six months ago; that it had been getting steadily larger, and for the last four weeks had grown very rapidly. The tumour (see woodcut), which was about the size of an orange, was found to occupy the inner part of the

fold of the groin, and to reach to the upper part of the scrotum. It was smooth, globular, circumscribed, elastic, non-translucent, and had the feeling of a very tense cyst. The veins over it were

WOODCUT 3.

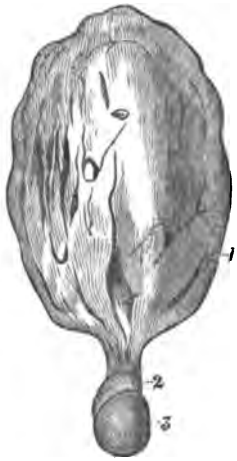

1. The tumour. 2. The epididymis. 3. The testicle.

dilated. The child's general health was good, and he did not appear to suffer pain.

"On May 10th an exploratory puncture was made with a small trochar, but without obtaining fluid.

"On May 13th a single incision was made over the front of the tumour, which was then easily dissected from the tissues of the scrotum, but was found connected posteriorly with the spermatic cord. This latter was divided, and the growth, together with the testicle, readily shelled out. The wound was dressed antiseptically, and the child discharged a few weeks afterwards apparently in perfect health. It is now a year since the removal of the growth and there are no signs of its return."

The tumour, which had the testicle attached by the spermatic cord to its lower end, was of an oval form, and measured in its longitudinal axis two inches, and in its transverse an inch and a half. A capsule of connective tissue surrounded it, and could be traced over the portion of the spermatic cord between the tumour and the testicle to the latter structure, which it also

enclosed. This capsule was apparently the infundibuliform fascia. The portion of cord between the tumour and the epididymis measured half an inch. The growth was smooth on the surface, of a firm consistence, and of a creamy-white colour, presenting on section a somewhat homogeneous, and in places indistinctly fibrillated, structure. Longitudinal sections, of which the accompanying is a drawing (Plate XXI, fig. 2), were made through a part of the lower end of the tumour, the contiguous portions of the cord, and the testicle, in order to better show the relation of the tumour to the cord; which latter, to the naked eye, appeared to pass uninterruptedly into the mass of the growth. By holding these sections up to the light, the vas deferens could be distinctly traced round the back of the growth; and, under a low power, the intimate connection of the hinder portion of the tumour with the cord could be seen. Under a high power the tumour was seen to consist in great part of mucous tissue intermixed with small, round, and spindle cells, and in places with tracts of ill-defined fibrous tissue.

Solid growths, other than fatty, in the spermatic cord appear to be exceedingly rare. Fibrous, and fibro-cellular (myxomatous) growths in the scrotum, however, appear to be much less so. Mr. Curling, in his work on the testicle, refers to several of the latter, and states that when they attain some size they become adherent to the spermatic cord, and in several of the cases he mentions, could not be separated from it, so that the testicle had to be removed with the growth.

It seems probable that some of the growths, that had been regarded as scrotal, adhering to the cord, had more likely their origin in the cord itself. Indeed, Mr. Curling himself is of this opinion with regard to one of the tumours he alludes to. Although it is possible that the present specimen might have originated in the tissues of the scrotum, I do not think that this is the case; for the fibrous capsule, which I think was the infundibuliform fascia, can be traced over the tumour uninterruptedly on to the testicle, and the connection between portions of the tumour and the ducts and vessels appear to be too intimate for the tumour to have merely become secondarily adherent to the cord. So close was the relation that at first sight it seemed probable that the growth had had its origin in some of the ducts of the epididymis. It had not, however, the papillary appearance common in intra-cystic growths; nor am I aware that in any cases of cysts in the cord have growths

been observed in their interior. The same objection holds good to the view that it might have been developed from the organ of Giraldès, or other remains of the Wolffian body, or from the Müllerian ducts. Besides, the growth was too far removed from the epididymis for it to have originated in any of these ways. On the whole I regard it as having been developed in the loose connective tissue of the cord.

In the Hunterian Museum there are three somewhat similar growths; two of these are said to be medullary carcinoma, and one a myxoma. The last seems to have grown from the epididymis. Of the two former, one, which occurred in a patient between forty and fifty, terminated fatally within two years of its first appearance; the omentum and lumbar glands being found at the *post mortem* examination infiltrated with medullary cancer. No operation was attempted. There is no history of the second case given. In both the testicle was healthy. In Guy's Hospital Museum there is a specimen of a growth in the cord called in the catalogue a melanotic cancer. Mr. Curling, in the work above mentioned, alludes to three cases. Two of these have already been referred to as contained in the Hunterian Museum, and the third occurred in the practice of Mr. Spence, of Edinburgh. The only specimen shown at the Society at all resembling this, was one which recurred after the third removal of a fatty growth of the cord. It consisted of a mixture of fat with large quantities of embryonic tissue, and was regarded as of the nature of a sarcoma. Volckmann describes a somewhat similar specimen which was called a "lipo-myxoma."

Since this communication was written, a very interesting tumour of the cord has been removed from a child, five months old, at St. Bartholomew's Hospital, by Mr. Willett. This growth almost surrounded the testicle, which appeared embedded in its lower and anterior part, and so much so that the growth was thought before removal to be of the testicle itself. Its structure was that of a mixed sarcoma. *February 17th*, 1880.

DESCRIPTION OF PLATE XXI.

Illustrating Mr. Walsham's specimen of Tumour of the Spermatic Cord. (Page 303.) From drawings by himself. See also Plate XXII, Figs. 3 and 4.

FIG. 1.—Longitudinal section.

a. Tumour.
b. Epididymis.
c. Testis.
d. Tunica vaginalis.

FIG. 2.—Section through the lower part of the tumour, the cord, and the testicle, to show the relation of the tumour to the cord. (Natural size.)

a. Tumour.
b. Epididymis.
c. Testis.

FIG. 3.—Segment from one of the tubular systems of cells, showing the three zones.

a. Outer zone.
b. Middle zone.
c. Inner zone.
d. Central space.

Fig 1.

Fig. 2.

Fig 3.



DESCRIPTION OF PLATE XXII.

Figures 1 and 2 illustrate Mr. Walsham's specimen of Horny Growth from the Eyelid. (Page 306.)

Figures 3 and 4 illustrate his specimen of Tumour of the Spermatic Cord. (Page 303.) All from drawings by himself.

FIG. 1.—Vertical section.

a. Horny layer.

b. Epithelial column.

c. Transverse section of epithelial column.

d. Base. ⅛ inch object.

FIG. 2.—Transverse section. ⅛ inch object.

FIG. 3.—Tumour of the spermatic cord. To show the tubular appearance of a thin section of the growth seen through a hand lens.

FIG. 4.—To show the tubular systems of cells as seen under a high power.

a. Outer zone.

b. Middle zone.

c. Inner zone.

d. Central space. ⅛ inch obj.

Fig. 1

Fig. 4

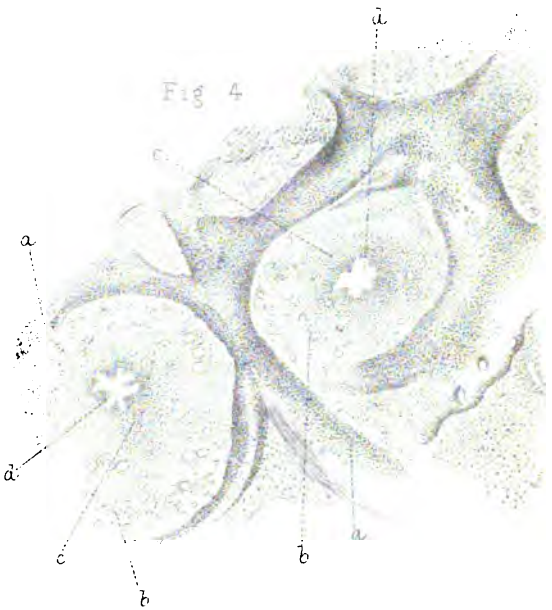

Fig. 2

Fig. 3.

16. *Tumour of the spermatic cord from a child four years of age.*

By W. J. Walsham.

[With Plate XXI, Figs. 1 and 3; Plate XXII, Figs. 3 and 4.]

For this specimen I am indebted to my friend Dr. Marshall. It was removed by him from the scrotum of a child, æt. 4, who was under his care at the Children's Hospital at Nottingham. I received the following brief history of the case from Dr. Marshall. "The child was first brought to the hospital two years ago, suffering from a congenital hydrocele. A truss was ordered to be worn, but it could not be used for long, on account of the pain it produced. Subsequently a fluctuating globular swelling appeared just outside the external abdominal ring, and was thought to be an encysted hydrocele of the cord. This swelling suddenly disappeared in September last, and was followed, two months later, by another swelling, just above the testicle, and verging upon the globus major of the epididymis. This second tumour rapidly increased in size, so that the fluid in the sac of the congenital hydrocele could not at last be returned into the abdomen."

On the 31st of January, 1880, Dr. Marshall removed the growth, together with the testicle, and the edges of the divided portion of the hydrocele sac were accurately stitched together. The wound healed favorably, and the child was discharged well. There was no history of syphilis, neither did the child show any trace of it.

The tumour is situated immediately above the testicle, and is intimately connected at its lower part with the globus minor of the epididymis. The testicle and the anterior third of the tumour are surrounded by the thickened tunica vaginalis, which has been laid open from the front. A loose capsule of connective tissue, and a few scattered bundles of muscular fibres, probably the infundibuliform fascia, and part of the cremaster muscle, can be traced over the sac of the tunica vaginalis, and those portions of the growth which are not surrounded by that tunic. The vas deferens appears to enter the lower and back part of the tumour; but it cannot be traced through it with the naked eye, although microscopic sections of the posterior part of the tumour show, in places, transverse and longitudinal sections of a duct, probably the vas, intimately surrounded by the elements of the growth.

The tumour, which measures about one inch and a half in its long

axis, and about one inch in the widest part of its transverse axis, is irregularly oval in shape, smooth on the surface, of a pale pinkish-white colour, and of a firm and slightly elastic consistence.

On section the cut surface appears irregularly nodular, and when examined by a hand lens gives one the idea that the section had been carried through a number of coils of one or more thick-walled ducts (Plate XXII, fig. 3). Thin sections, mounted on a glass slide and held to the light, present the same tubular appearance, and when examined by the microscope are extremely suggestive of an intratubular origin of the growth. Under the half-inch objective the appearance of ducts is seen to be due to the presence of a number of tubular systems of cells (Plate XXII, fig. 4). On transverse section each tubular system consists, for the most part, of an irregular and generally centrally placed space or channel, surrounded by several tolerably distinct zones of cells. The central space, when present, shows no trace of limiting membrane. In the zone immediately surrounding it the cells are closely aggregated, and no blood-channels are seen amongst them. In the next zone the cells are much less densely packed, and numerous large blood-vessels with distinct walls abound. In the outermost zone the cells are supported by a very delicate, concentrically arranged, reticulum of fibres; but this is better seen under a higher power (Plate XXI, fig. 3). Under the quarter and eighth the cellular elements, which vary slightly in shape, consist, for the most part, of small round nuclei, embedded in varying amount of homogeneous or very indistinctly fibrillated protoplasm.

The exact nature of the growth seems doubtful. I have shown sections of it to several friends accustomed to the microscopical examination of tumours. They differ in their estimation of its characters. In many respects it resembles a gummatous growth, but the child had no signs whatever of congenital syphilis, and there was no parental history of this disease, a point concerning which Dr. Marshall made careful inquiries. It has been thought a round-cell sarcoma, or as having affinities to the somewhat indefinite form of tumours called by Virchow granulomata. For my own part, although I am unwilling to give it a name, I believe, from the microscopical appearances I have described, that it had an intratubular origin, and I cannot help thinking that it may possibly have arisen in some of the tubular remains of the Wolffian body (as the organ of Giraldès), so abundant at the commencement of the cord. Granting an intra-

tubular origin, it is possible that it might have arisen in some of the tubes of the epididymis, or in the vas.

The situation of the growth, then, at a spot where the remains of fœtal ducts normally occur, its tubular character, and the apparent freedom of other ducts in which it might have originated, seem to be points in favour of its formation from fœtal remains; and although, as far as I know, there is no record of any solid growths in this situation having had such an origin, still, looking to the facts that cysts are not unfrequently developed from these remains, and that fœtal structures in other parts of the body are believed to be occasionally the starting-points of solid growths, it does not seem to me unreasonable to attribute the growth in this situation to a like cause.

From the history of the case it would appear not improbable that the pressure of the truss, which the child had been ordered to wear for the cure of the congenital hydrocele, had been the cause of the intratubular proliferation. Although, if this were the case, it would rather point to the ducts of the epididymis as being those affected, it does not, I think, altogether militate against the view that I have taken, *i. e.* that the growth had been produced in the tubular remains of the Wolffian bodies. It would, of course, have been necessary for the Wolffian tubules to have kept their connection with the vas deferens, *i.e.* the Wolffian duct; and there is no reason why they should not have done so, seeing that in encysted hydrocele of the testis, which is believed to originate in these remains, a communication has been shown by Luschka to exist between the interior of the cyst and the vas.

Another point of interest in the history of this case is the sudden disappearance of the swelling, which occurred just external to the abdominal ring, and was thought to be an encysted hydrocele of the cord. It seems just possible that this might have been a growth similar to the one subsequently removed, and that its disappearance might be accounted for in the same way as the disappearance of the growths described by Dr. Gairdner ('Path. Soc. Trans.,' vol. xxx, p. 387). In that case the growths, which had a structure somewhat similar to that of the present specimen, had disappeared several times spontaneously. As remarked by Dr. Goodhart, "This was probably due to the tubular arrangement of the cells, which had allowed part of the morbid growth to be carried away piecemeal along the tubes which formed part of the tumour."

The tumour of the spermatic cord, described in a previous communication (see p. 299), had a myxo-sarcomatous structure, and appeared to originate in the loose connective tissue of the cord. A reference to other growths in the cord will likewise be found in that communication. *April 20th*, 1880.

---

17. *Horny growth from the lower eyelid of an old woman.* By W. J. Walsham.

[With Plate XXII, figs. 1 and 2.]

The growth was removed by my friend Dr. Marshall from the left lower eyelid of a woman, æt. 87, in whom it had been growing only two months. It is said to have had its origin in a wart, or small sebaceous tumour, which had existed for many years. The growth, in external appearance something like a limpet shell, measures 1¼ inches in length, and 1⅛ inches in diameter at its base. It has a horny consistency externally, whilst internally it appears to be composed of a white, soft, sebaceous-looking material. The specimen is shown for two reasons, 1st, because of the rapidity of its growth; and 2nd, because hardly any mention of the microscopical structure of the few similar specimens shown before the Society has been made in the 'Transactions.'

Microscopically, it is seen to consist chiefly of epithelial cells. The cells near the surface are compressed and flattened laterally so as to form the cornuous layer. Columns or club-like processes of epithelium (see fig. 1) are noticed at intervals extending longitudinally through the general mass of cells. On transverse section (see fig. 2) the cells composing these columns are seen to be arranged concentrically, the internal cells being of a somewhat irregular shape, the more external, however, being flattened and laterally compressed. The cross section presents much the appearance of the epithelial nests characteristic of epithelioma (figs. 1 and 2). A central space is noticed in the cross section of some of these columns, which may be either due to a hollowness of the column or to the falling out of the central cells. In some fat-cells are seen.

On tracing some of these columns upwards (see fig. 1) from the base of the growth they are noticed, after proceeding a variable distance, in its long axis, to be slightly deflected outwards to the circumference, where the cells composing them blend with the cells forming the horny layer. This outward deflection would appear in many instances to be due to the presence of other and more internal columns, which, as they grow upwards, press the outer ones aside, whilst these more internal columns are in their turn pressed outwards by others still more centrally placed.

Some difference of opinion exists concerning the nature of these growths. In Drs. Jones and Sieveking's 'Pathology,' edited by Dr. Payne, they are said to originate in the sebaceous follicles, whose epithelium, thrown off in unnatural and excessive quantities, and mixed with the fatty secretion, forms a conical mass which protrudes from the orifice in the skin, and is pushed onwards continually by fresh accretions to its base. The exact connection of this growth with the parts from which it sprung could not be determined, as it was twisted off at its base, no portion of skin being removed with it. From the small amount of oily matter, however, which it contained, the large preponderance of the epithelial elements, and the microscopical arrangement above described, it appears probable that it originated as an epithelial proliferation rather than as a sebaceous outgrowth. Specimens similar to this have been shown at this Society by Mr. Holmes, in 1865, and by Mr. Wagstaffe, and by Mr. Bellamy in 1870.

April 6th, 1880.

---

18. *Dermoid tumour from the rectum.*

By Heinrich Port, M.D.

[With Plate XXIII.]

The specimen exhibited is a dermoid tumour showing an abundant growth of hair, and chiefly of interest on account of its situation. It was taken from the rectum of a young woman, and was attached by two pedicles to the posterior wall of the intestine, about three inches above the external orifice. The following is the history:

A. K—, æt. 16, was taken into the German Hospital, in October last, complaining of intestinal obstruction, and a forcing pain on any attempt to relieve the bowels. These symptoms were only of a recent date, about three months. Some days after her admission it was observed that a polypoid tumour, of large size, came partly out of the anus when the patient wanted to pass a motion. A mass of long hair repeatedly made its appearance, and could only with difficulty be replaced. The patient was brought under the influence of chloroform, the round tumour was drawn down as much as possible, and its attachment, somewhat to the right from the median line and about three inches above the anal orifice, was ascertained. As the two pedicles were very short, my colleague, Dr. Burger, who kindly saw the case with me, was of opinion that interference should be postponed until the pedicles had become stretched to a greater length by the frequent straining downwards. This proved to be the right course. About three weeks after the patient's admission, one day the tumour came out to its whole length so that the sister in charge could not replace it. It soon became gangrenous, and was easily removed with the help of two ligatures. The patient was in a day or two quite well again, and has not since shown signs of any recurrence.

The tumour, as it is seen now—it has much shrunk through the action of alcohol—is 2½ inches long, and measures 2 inches across in one direction and 1½ inch in the other. As regards its composition, the bulk of it is made up of fibrous tissue with numerous fat-cells. Embedded are two masses of bony substance, the one of hard, the other of spongy consistence. The integument of the tumour shows all the characteristics of ordinary skin; epidermis, papillæ, hair follicles, sebaceous glands. The microscopical examination proved also the existence of numerous bundles of muscular fibres below the cutis. I may add that a well-formed canine tooth was observed to be growing from the tumour not far from the pedicles. Unfortunately, no trace of it was left when the growth was finally removed.

Dermoid cysts are met with in many parts of the body, but I could not find anything in literature corresponding to the case which I have brought before you, until my attention was directed to an article in 'Langenbeck's Archiv,' 1874, in which Dr. Danzel reports a very similar case. A woman, of 25, complained to him of hairs which protruded from the anus, and which she pulled out

DESCRIPTION OF PLATE XXIII.

Illustrating Dr. Port's Case of Dermoid Tumour from the Rectum. (Page 307.)

The *upper* figure shows the appearance of the tumour after it had been in spirit for some time. At the upper part a mass of hair is seen escaping, and to the left are the two pedicles by which the tumour was attached.

The *lower* figure shows the tumour in section. Near the upper part is a portion of bone.

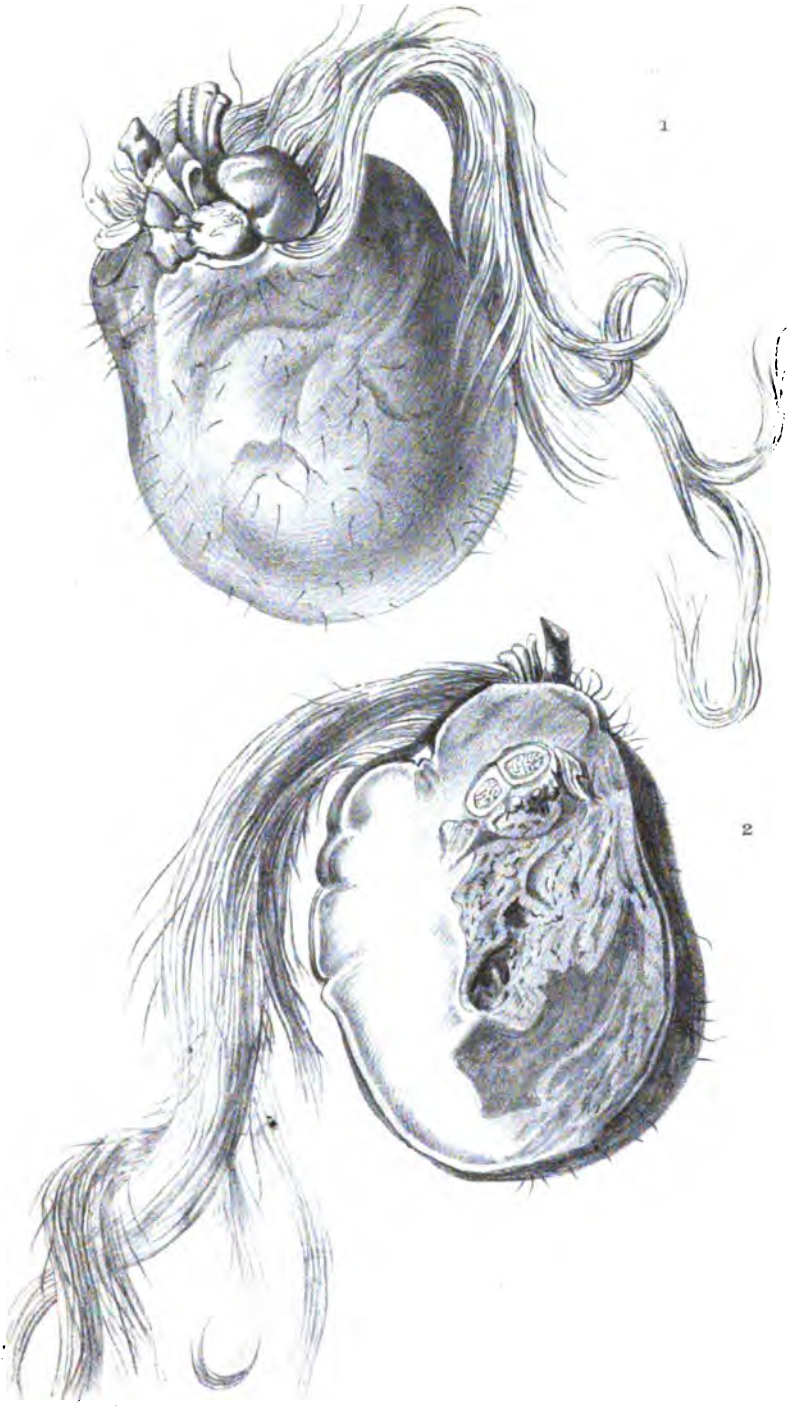
1
2

when they became too long. It was found that they were growing from a polypoid tumour, the size of an apple, and attached to the wall of the rectum 2½ inches above the sphincter externus. The tumour was removed, and showed, besides the hairs, a tooth at its outside. The microscope proved that brain substance enclosed in a bony capsule was part of the tumour. *May 18th*, 1880.

---

19. *Lymphoma of mediastinum pressing upon the right bronchus and invading the lung.* (*Card specimen.*)

Exhibited by HENRY A. LEDIARD, M.D.

THIS specimen was taken from a woman, aged 69, who died in the Cleveland Street Sick Asylum on July 18th, 1879.

The chief symptoms were emaciation and great weakness, cough, scanty bronchitic sputa, and lastly, dyspnœa with evidence of fluid in the right pleura; but the right chest was retracted.

The lung is small, solidified, and compressed by fluid, and shows general recent pleurisy with adhesion of lobes.

A mass of lymphoma is seen pressing on the right bronchus and almost occluding it.

The growth has invaded the lung, and there is a dilated condition of the terminal portions of the bronchi, which were stuffed with secretion when first examined; here and there is destructive pneumonia, but no emphysema. There were numerous secondary deposits in the liver as well as in the cervical lymphatic glands.

Microscopic examination of the growth showed the usual lymphoid tissue met with in these cases. *November 4th*, 1879.

20. *Myxo-sarcoma of the head of the tibia.* (*Card specimen.*)

Exhibited by W. J. WALSHAM for MR. ANDERSON.

THIS specimen was removed from a woman, aged 30. Eighteen years ago she noticed pain and slight swelling of the outer tuberosity of the tibia. The swelling increased gradually to within five months of the operation for its removal, and then began to grow rapidly and with severe pain. It appeared as a distinctly circumscribed, smooth, slightly undulating, firm, immoveable growth, about the size of the fist, on the outer side of the tibia just below the knee joint. There was an egg-shell-like crackling around its circumference, but none over its central part. The skin over it was healthy, and there was no glandular enlargement.

The tumour apparently springs from the interior of the outer tuberosity of the head of the tibia. It presents the ordinary appearance of a spindle-celled sarcoma, and contains a large cyst.

Under the microscope it is seen to consist of spindle-celled tissue intermixed with mucous tissue. *December 2nd*, 1879.

21. *Pedunculated fatty tumour, which grew over the anterior superior spine of the ilium.* (*Card specimen.*)

Exhibited by W. J. WALSHAM.

THE only points of interest in this specimen are its peculiar form, and the unusual situation in which it occurred. It appeared as a globular, distinctly pedunculated growth, hanging from the anterior-superior spine of the left ilium. Both macro- and micro-scopically it has the structure of an ordinary fatty tumour.

The tumour was removed from the body of a woman brought to St. Bartholomew's Hospital for dissection.

No history was obtained. *March 1st*, 1880.

22. *Myxo-fibroma of epididymis and cord.* (*Card specimen.*)

Exhibited by JAMES F. GOODHART for Mr. JOHN GAY.

THE tumour shows as an elongated nodular swelling, covered by a tough capsule like the tunica albuginea. Behind, the vas deferens terminates in a swollen portion, apparently the commencement of the *epididymis*. The *testicle* occupies the lowest part, and in front of it is part of the tunica vaginalis full of blood-clot.

The section of the growth is firm; it has allowed of a minute injection of its capillaries, except where, in its central part, it has undergone caseation.

Microscopically, its structure is that of a delicate hyaline fibroid tissue, containing spindle-cell elements in it. From its flickering, immature structure, it corresponds more to the myxomata than to fibrous or sarcomatous tumours.

From a healthy married man, aged 45, under the care of Mr. Gay. It had been observed for three months only. There was no glandular enlargement. *February 17th*, 1880.

23. *Tumour found loose in abdominal cavity.* (*Card specimen.*)

Exhibited by FREDERIC S. EVE.

AN oval tumour, found loose in the abdominal cavity of an old woman, brought to St. Bartholomew's Hospital for dissection.

It is composed almost entirely of calcareous matter, lying within a scanty, soft, fleshy material, and is so hard that it was necessary to make the section with a saw.

Microscopic examination.—The fleshy part of the tumour consists of fibrous tissue, containing a considerable quantity of involuntary muscular fibre in bands and detached patches.

Remarks.—The microscopic examination suggests that this tumour was a pedunculated subperitoneal fibroid of the uterus, which became detached. *March* 16*th*, 1880.

24. SERIES OF FIFTEEN DRAWINGS OF CANCER.

Exhibited by Mr. HULKE.

(1.) *Scirrhus of female breast.* (*Card specimen.*)

A PROMINENT glossy knot in a scar; an ill-defined mass in breast; infected glands in armpit. Removal in July, 1879; now recurrence in armpit, and infection of glands in root of neck. The primary tumour, thought to be adenoma, was excised in a country infirmary in 1877. A small knot, midway between breast and armpit, was excised by myself in 1878. It had the clinical and rough character, on section, of a fibroma. 17*th December*, 1879.

(2.) *Cancer of female breast.* (*Card specimen.*)

ULCERATED cancer of breast, of about six years' duration, during the last three of which it was ulcerated. Secondary masses in the liver. No infection of the lymphatics, and no outlying secondary knots around the primary tumour. Death from exhaustion. All the viscera excepting liver were healthy.

December 2*nd*, 1879.

(3.) *Scirrhus of female breasts.* (*Card specimen.*)

PRIMARY cancer of the left breast. Secondary infiltration of the right breast and front of chest. *December* 18*th*, 1879.

(4.) *Scirrhus of female breast.* (*Card specimen.*)

VERY chronic cancer; atrophic. Slightly ulcerated; few secondary knots in an aged woman. *December* 18*th*, 1879.

(5.) *Scirrhus of breast.* (*Card specimen.*)

EXTENSIVELY ulcerated, the margin a narrow raised hard wall. Large portions of the ulcer more than once cicatrised by islands springing up within its area, not running in from the edge. *December* 18*th*, 1879.

(6.) *Drawing of cancer of lower lip.* (*Card specimen.*)

PATIENT, an old man, æt. 70, had for about four years a wart on lip, which gave no trouble until about ten months before he came under my notice, when he chanced to cut it off in shaving. The little wound never healed but festered and enlarged, and some time later it was pronounced a cancer by a medicus, who excised it. The incisions never perfectly healed, the lower angle swelled, and he put himself under a quack who burned it, June 12th, 1876. The whole of the infiltrated parts were freely cut away, and a new lip raised from the chin. The greater part of the lines of incision healed immediately, and he went home in a fortnight. Six months later he returned with recurrence under the chin and in scars. No further operation was deemed proper.

(7.) *Cancer of lower lip, and mole on cheek.* (*Card specimen.*)

A CARPENTER, æt. 56. Finely warty raised sore with sharp, slightly everted edges.
Duration twelve months.
Excision January 24th, 1877.
Further course not known. *January* 6*th*, 1880.

(8.) *Cancer of lower lip.* (*Card specimen.*)

THE patient, a woman, æt. 51, had had during twenty years a little wart on the lip, which did not occasion her any concern until six months before I saw her, when she had a scabbed warty ulcer of size of silver sixpence, on a hard base, on the lip and near angle of jaw an enlarged indurated gland.
The ulcer and the gland were excised. *January* 6*th*, 1880.

(9.) *Cancer beginning in lower lip.* (*Card specimen.*)

A LABOURER, æt. 54. Extensive infiltration of lip, cheek, and neck, with ulcerative infections of lymphatic glands, after excision of a primary epithelioma of lower lip two years previously.

The patient lived forty-six months after first noticing the disease.

6th January, 1880.

(10.) *Cancer of lower lip and ichthyosis of tongue.* (*Card specimen.*)

AN old man. No clear history of duration could be obtained. The ichthyotic patches on tongue radiated from an indentation opposite the lower incisors.

The epithelioma was excised; the teeth removed. Removal of tongue was declined by the patient. *6th January*, 1880.

(11.) *Cancer of womb, invading vagina and rectum; colotomy.* (*Card specimen.*)

CANCER of womb, largely ulcerated; in the posterior wall of vagina a large opening, by which the rectum and vagina freely communicate. The infiltration of the walls of the rectum had also offered much obstruction to the passage of fæces, and when stools were procured by aperients defecation was attended with great suffering; for this colotomy was done. The woman, æt. 74, quickly rallied from the operation, and her life was prolonged under conditions of relative ease. She survived rather more than two months.

2nd December, 1879.

(12.) *Cancer of anus.* (*Card specimen.*)

A WARTY ulcerated cancer, which, beginning at anus, has invaded the labia and vagina, extending too far along the latter to allow excision.

Colotomy was therefore done which gave much relief.

16th March, 1880.

(13.) *Chimney-sweep's cancer.* (*Card specimen.*)

THE patient, æt. 52, a sweep. The disease was known to have been present about seven months. The glands in both groins were already involved. *March 16th*, 1880.

(14.) *Chimney-sweep's cancer.* (*Card specimen.*)

THE man was about 40 years old, a sweep. His brother, also a sweep, had had a similar cancer in the thigh.

March 16*th*, 1880.

(15.) *Cancer of penis and inguinal glands.* (*Card specimen.*)

THE penis, to the level of the scrotum, has been destroyed by cancerous ulceration. The lymphatic glands in both groins are extensively involved. The man was 56 years old. The known duration of the disease at the time this drawing was taken was about twelve months. *March* 16*th*, 1880.

IX. DISEASES OF THE SKIN.

1. *The histology and pathology of morphœa and its relation to scleroderma adultorum.*

By H. Radcliffe Crocker, M.D.

Hitherto there has been no microscopical examination made of the disease formerly known as Addison's keloid, but now more generally called morphœa; as a consequence, its pathology has not been thoroughly understood, and some authors, as the late Dr. Tilbury Fox, class it with the hypertrophies of the skin, while others, as Dr. Duhring, of Philadelphia, place it among the atrophies. To some extent, as I shall presently show, they are both right. Again, lardaceous deposit is spoken of by some writers, a term for which, if used in the ordinary pathological acceptation, I can find no warrant.

In 'Guy's Hospital Reports' for 1867, and again in the volume for 1869, Dr. Hilton Fagge drew attention to the frequent association of this disease with scleroderma adultorum, and argued that morphœa was only a circumscribed form of it. With few exceptions this view has met with general acceptance, and Mr. Hutchinson, in the second part of the first volume of his 'Lectures on Clinical Surgery,' proposes to call both the general and local disease by the one name morphœa, at the same time the superficial clinical characters and course present several points of difference, and it will be more convenient, in this paper, to speak of the general disease as scleroderma, and reserve morphœa for the local one.

The observations have been made upon skin removed from two women, with their concurrence, one at the East London Hospital for Women and Children, who was kindly transferred to me by my colleague, Dr. Donkin, the other a patient attending at University College Hospital; both are here to-night, and they have both

been under my care for over two years. I have examined sections of the disease in its earliest stage, when there were only small pearly-white spots, about a line in diameter, in the more advanced patches, where the skin was still thin and transparent, and where the disease was still older, ivory white, and opaque.

The results are as follows:

Microscopical appearance in the early stage:

Epidermis.—There is no perceptible alteration in the epidermis, though, of course, there would be in the pigmented cases. In some sections I have seen a few leucocytes in the Malpighian layer.

Corium.—The papillæ are less prominent than normal. In many of the vessels of the superficial longitudinal plexus and papillary branches there are found thrombi blocking the lumen; in some cases the thrombus extends into the minute branches going up to the papillæ, but more frequently the vessels lying horizontally are alone occluded. In one section a small dot, situated at the angle of bifurcation of the vessel, suggested an embolus.

Numerous irregularly branched masses of cells, about the size of leucocytes, staining deeply with carmine, but taking rather longer to do so than the surrounding tissues, are always found; and except when grouped round the sebaceous glands they mostly lie horizontally, corresponding to the superficial longitudinal vessels. Blood-vessels can frequently be seen going into and lost in the mass, and in some cases they are connected with the vessels that have a thrombus beyond the cell groups; sometimes the vessel appears to expand at these masses as if it were ruptured, and the cells were an effusion. In other cases vessels may be seen with cells round them.

Branching from the cell masses there is often a reticulum, consisting of fine fibrils with well-defined borders and cells at intervals upon them, like knots on a net. These cells are mainly, as I have said, round the superficial longitudinal vessels, the papillary branches being without them, except at their commencement sometimes. The process is rarely seen in the deep plexus, at least in the early stages, but the connecting branches of the two plexuses are more frequently involved; but this cell exudation may be seen occasionally, even in the upper layer of the fat.

Glands.—Round the sebaceous glands and hair-follicles the cell groups and reticulum are very abundant, chiefly, I think, because

there are more vessels in the neighbourhood of the glands. Cells occur round the sweat ducts, but the sweat glands, lying deeper, usually escape. In one of the sections, showing the cells round the duct, the gland below is normal, and just above it is a deep vessel of the corium, running into a mass of cells.

In the later stage the essential feature is the increase of the connective and elastic tissues from the fibrillation of the cells seen in the early stage. The papillæ are nearly flattened out. The dense bundles of connective tissue press upon and obliterate many vessels, cause atrophy of the sebaceous glands and of the sweat ducts, very few of which are seen in this stage. In one section, where the disease is of longer duration, there is, I think, distinct increase in the connective tissue between the acini of the sweat gland, and the lining cells appear to be pressed together; although this implication of the sweat glands is exceptional, yet the destruction of the ducts necessarily prevents the escape of the excretion, which I have proved by the injection of pilocarpine subcutaneously close to the patch, when while the skin around was quite wet with perspiration, the patch itself was quite dry, except in one very thin part, which lacked the smooth parchment-like feel of the denser parts, and gave a slight sense of resistance to the finger passed over the part. A zone, about half an inch wide, round the patch, was, though moist, decidedly less so than the parts beyond.

With anilin violet and iodine I cannot obtain evidence of lardaceous change in the vascular walls, though the cells stain deeper with both these reagents than the surrounding tissues; the cut ends of the muscular fibres in the walls of the vessels are quite discernible, though perhaps a little less so than in normal vessels. Osmic acid and nitrate of silver have also been used, with a view of ascertaining the condition of the nerves and lymphatics, but, it having been done in the dark days of winter, the staining was imperfect, and no additional facts were learned by their use.

To recapitulate; in the early stage:

Epidermis.—In some parts there are degenerative changes in the deepest layers, but it is for the most part unaltered, except in the pigmented cases, where the pigment would be seen in the deep layer.

Corium.—Atrophy of the papillæ, thrombosis of the longitudinal vessels of the superficial plexus, and sometimes of the papillary branches.

Cell masses staining with carmine especially abundant round the sebaceous glands and hair follicles, but not round the more deeply lying sweat glands, but may be round the sweat ducts; a fibro-cellular reticulum is seen between the cell groups. Vessels run into and terminate abruptly in the cell masses as if the vessel had ruptured, and cells are seen round the vessels.

The vessels of the deep plexus are usually unaffected in this stage, but the connecting vessels of the two plexuses not unfrequently. With methanilin-violet, and iodine, the walls of the vessels show no sign of lardaceous change, and the elements of the vascular walls are fairly discernible.

In the later stage:

There is great increase of the connective and elastic tissues of the corium; the process of the early stage described above spreads to the deep part of the corium, and even to the upper layers of the fat, and by the contraction of the new fibrous tissue:—(*a*) Vessels are obliterated, (*b*) the sebaceous glands are atrophied, (*c*) the sweat-ducts obstructed, (*d*) but the sweat-glands only rarely involved.

But how are the thromboses, cell groups, and layers of cells round some of the vessels to be explained? Some of the sections show vessels which, by the sudden expansion of the lumen as the vessel runs into the cell mass, point to rupture; these and the other cells stain deeply with carmine and other reagents, but, in the case of carmine, require some little time longer than the other tissues; the cells round the vessels are evidently not due to rupture, and these and the separate cells further away and connected by fibres into a reticulum, give warrant for the supposition that they are wandering cells. I would suggest, then, that owing to some either very chronic inflammatory or other trophic change in the vascular wall, probably of nervous origin, cell exudation occurs round the vessel, and by its pressure interferes with the circulation and leads to thrombosis, and in some cases to actual rupture and effusion. I only put forward this explanation tentatively, and shall be glad to hear further suggestions from the Society; but whatever may be the view with regard to the above, the other appearances are more obviously explicable, and the whole facts explain and are corroborated by the clinical characters and course of the disease, to which I would briefly allude.

The disease begins as pearly white spots, about a line in diameter,

slightly depressed below, and thinner than the surrounding skin, nearly smooth in the centre, and crenated at the margin; similar spots may be seen at the extending edge of an already formed patch. These atrophic spots are the base of the cone of which the blood supply is cut off below by the thromboses. The skin intervening between the pearly spots shows a slight mottled pinkiness, and round the fully formed patch a pinkish-violet zone of dilated vessels is a recognised clinical feature; these appearances are the result of the collateral hyperæmia one would expect to find round an anæmic area. Other results of the hyperæmia occasionally seen are pigmentation and small extravasations of blood in the affected skin.

In a case under the late Dr. Tilbury Fox's care that I saw some years ago, the patches, which were very numerous, ulcerated. This I take to have been caused by the blood supply having been so completely cut off as to occasion the death of the tissues. The patch is formed by the increase in the number and size of the spots and their subsequent coalescence, and at first the process is so superficial that the vessels seen through the semi-translucent affected area give it a pinkish-white tint; the skin is here slightly thickened, and the process going deeper, and fibrillation occurring, the centre and older parts get opaque, ivory white, or pigmented and thickened. When the newly-formed fibrous tissue contracts the skin is drawn into folds radiating from the centre of the patch, and the puckered part feels thicker. Involution very gradually occurs, as we may infer by the degeneration and absorption of the effused products, the skin gets more transparent and thinner, and slowly resumes its normal appearance. This involution is occurring in one of the cases shown to night, while the process of extension may be seen in the other. In the last the disease has been present about two and a half years, in the other the patch has been noticed two and a quarter years; but as it was then 3 inches long by 1½ broad, it must have been forming for a longer period than that. In both cases the disease recurred in the parts removed, at all events the site of the cicatrix is scarcely recognisable. If we now compare morphœa with general scleroderma, we shall notice many differences, but closer investigation will, I think, show that these are less than they appear at first sight. In scleroderma the opaque ivory whiteness of morphœa is absent, the skin appears pale or yellowish only, cannot be pinched up

into a fold, and seems too tight for its contents; moreover, the process implicates sometimes the deep tissues as the muscles and bones.[1]

In cases of long standing or so called atrophic stage, the skin seems thinned and stretched tightly over the subjacent parts, producing atrophy of the compressed tissues. There are, however, many points of resemblance. The two affections frequently occur in the same subject; pigmentation is seen occasionally in both, and on the border of scleroderma there is sometimes a line of dilated vessels like that round the morphœa patch. I have observed in the two cases of scleroderma that have come under my notice, one of which is shown at the Clinical Society to night and the other last year, lines of dilated vessels in the skin constituting a network, which contrasts with the pallor of the intermediate skin. This has not been generally recorded in the various cases that have been published, but I was interested to find it figured in a drawing of the skin in a case of Dr. Harley's, published in the 'Medico-Chirurgical Transactions' of last year, and in this case there was pigmentation between the vessels. Mr. Hutchinson has also noted it in the case of Mrs. M—, in his recent lectures on Clinical Surgery, where he states "the skin is everywhere streaked with little tufts and lines of dilated capillaries, giving a slightly ruddy appearance. This teleangectasis is clearly a part of the morbid process." Although this observation has only been recorded, as far as I can discover, in the four cases I have mentioned, it is confirmatory of the analogy of morphœa and scleroderma, and finds a similar explanation, and I believe will be found more or less in all cases if looked for. The microscopical appearances in scleroderma have been frequently described, there is the same increase of the fibrous and elastic tissues in the corium and destruction of vessels; in some cases the papillæ are flattened, and the glands, &c., atrophied, but the process goes deeper and the fat disappears wholly or partially with great increase of fibrous tissue, and "the distinction between the corium and subjacent cellular tissue is lost." No mention of thrombosis occurs in any of the descriptions, but this may be due to the observations having been made upon cases in which the disease has existed for some time, and where, therefore, the thrombi would have disappeared, and so we only hear that "many vessels are destroyed."

[1] Later in the session Mr. Streatfeild showed a case of exostosis in association with morphœa, limited to the distribution of the fifth nerve.

In short, the main difference is that the process is a deeper one at its commencement, but of precisely the same character, hence when the new fibrous tissue contracts in scleroderma the skin over it is tightened and thinned, owing to the adherence of the corium to the subjacent tissues; while in morphœa, the upper part of the corium containing the contractile tissue draws the skin into puckers and thickens it, as in one of the cases shown to-night. So too as regards the colour. In morphœa, the superficial vessels being occluded, the skin is quite white, almost bloodless, the increased connective tissue and cell-exudation making it opaque. In scleroderma, the deeper vessels being those mainly affected and occluded, the skin though pale is not so opaque, and many of the surface vessels are dilated to compensate for the diminished number of channels below.

But what is the primary cause of these conditions? In morphœa we frequently find the patches lying in the course of a nerve, especially the fifth, when one half of the head and face is affected. In such cases Mr. Hutchinson, comparing it with herpes zoster, strongly insists that we must seek the cause in the nervous system. Prolonged anxiety, and worry too, are frequently a part of the history of such patients; but symmetrical cases occur, and in the middle line, and where patches are not demonstrably limited to the course of a nerve; and here the nervous origin is not so apparent. Moreover, in some cases of scleroderma, the whole body is affected in the course of a few days. This, and the frequent association of scleroderma with acute rheumatism, and peri- and endo-carditis, without other rheumatic symptoms, and the history of cold and wet so commonly met with as immediately preceding the onset of the attack, suggests that some blood change is concerned in the production of the lesion; perhaps the increase of fibrin in the blood, which characterises acute rheumatism, may at least be a favouring condition. The symptoms and localisation of the process in the perivascular sheaths present, I think, a close analogy to phlegmasia dolens, where the thromboses in the veins, with concomitant inflammation of the lymphatics, leads to a similar hardness and whiteness of the limb; but here the deep trunk vessels, and therefore the whole limb, is affected, while in scleroderma with a similar tenseness, it is mostly limited to the deep parts of the skin and immediately adjacent tissues.

A general inflammation of the deep part of the corium, and

perhaps of the fat, with consequent lymphatic and vascular blocking, seems a feasible explanation, though it does not negative a possible nerve influence.

In conclusion, I would say, that the histology confirms Dr. Hilton Fagge's clinical deduction, that "morphœa is only a circumscribed form of scleroderma," except, I would add, that the process is more superficial; and where the two are associated, the diseased process has spread upwards to the surface instead of remaining deep as a scleroderma generally does. We can consequently well afford to relieve the over-loaded nomenclature of dermatology of one of these names, and since scleroderma expresses the characteristic hard condition of the skin, I would rather drop the meaningless term "morphœa" and speak only of diffused and circumscribed scleroderma. *November 4th*, 1879.

---

2. *A case of scleroderma adultorum, illustrating the circumscribed and the diffuse forms of the malady.*

By Dyce Duckworth, M.D.

Julia H—, æt. 24, single, a general servant, came under my care at St. Bartholomew's Hospital in April, 1880, suffering from well-marked scleroderma. She complained chiefly of rheumatic pains in her hands and arms. It was difficult to get from her a clear history of her ailments. The following account is the best I could elicit.

Till eight years ago she was in good health; at that time she perceived a hardened patch of skin the size of a penny piece, looking something like a bruise, on the inside of her left thigh. It was the seat of itching sensations. She sought advice in the country, and was treated for two or three months. The patch continued to grow till it enlarged to the size of her hand, and gradually hardness and tightness were observed to extend from this under the knee.

After some time she came to a situation at Balham, and believed that the patches were becoming smaller, as they certainly seemed paler and softer. After one year's service she found herself becoming gradually weaker in the legs, and suffered from pains in all the

joints of both upper and lower extremities. The jaw was also affected, and became stiff, and thus mastication was difficult. The ankles, wrists, and finger-joints swelled, and were painful on movement, but not otherwise. She then left her situation, and had advice at the West Kent General Hospital at Maidstone. During the whole of her life she has never been bedridden for a day. The swellings passed away from all the joints, except those of the hands and ankles. The patches on the left thigh seemed to be disappearing. After eighteen months she returned to her situation at Balham, where she now remains. About three years ago, a new patch was observed below the left knee, the size of a sixpenny piece, of brown colour and hardened. She thinks this patch slowly grew larger, but without causing any pain, itching, or discomfort, till April, 1879, when another attack of rheumatic trouble came on, and all the joints, except the jaw, again became hot, swollen, and painful. About this time the patches on the leg below the knee seemed to extend and become harder and darker. In September of that year she noticed that the left foot and leg generally were very hard and stiff, and since that time the right leg and both forearms and hands have become hard and stiff. No more patches have appeared up to the present time.

The affection is confined in this case to the extremities. The trunk is nowhere involved. The diffused form of the disease is best seen on the hands, forearms, and legs. There is a fair symmetry so far as the arms are concerned, but less about the legs. The right thigh is not affected. The hands are much crippled and stiffened, the fingers being flexed on the palms, especially in the right, and the joints are fixed. The skin of the hands and forearms is smooth and shining, somewhat reddened over the joints. The axes of the fingers are deflected to the ulnar side. The nails are natural. The metacarpo-phalangeal and the phalangeal joints are swollen. The third and fourth fingers are the most flexed in each hand.

The integuments cannot be freely pinched up anywhere on the hands or forearms, owing to loss of proper elasticity in the skin. On flexion of the forearms, it becomes possible to pick up more of the integument than in the extended position, and the suppleness increases as the elbows are approached. On passing up the arms the infiltration gradually becomes less marked, and the skin on the upper arms is unaffected. There are no ivory patches and no pigmentation on the upper limbs. The patient states she does not

perspire on the forearms. The palms of the hands and soles of the feet were, however, moist while under examination. The arms are said to feel, as she expresses it, "very stony" in cold weather. The forearm is fairly well flexed, but supination is performed with difficulty. The epidermis on the backs of the hands and forearms was cracked transversely in many parallel lines, and disposed to peel off in very thin flakes. Over the bones, such as the tibiæ, the integuments seemed to be fused and incorporated with the periosteum, and felt like enamelled leather.

On the lower extremities the affection is found to be fairly symmetrical below the knees. The integuments are hide-bound and glossy, of brownish (old ivory) tint, and streaked in places. The soles of the feet, like the palms, are unaffected, and moist. The tightness of the skin renders flexion of the knees slow and stiff. On the right leg the diffused hardness ceases at the lower level of the patella; in the left limb a streaky band of induration connects the affected part on the leg with the original patches on the inner and posterior aspect of the thigh, passing outwards as far as the biceps tendon. The hams are both free. On the front of the left leg are two patches of unaffected skin.

Common sensibility seems natural in all the affected parts.

The oldest patch has evidently undergone much involution, and is free and supple, though depressed in the centre. There is much pigmentation about it, especially at its margin. On both thighs are seen numerous dilated venules, but there is no varix. The epidermis is peeling off in flakes from the dorsum of the left foot. The pigmented portions are more marked on the inner aspect of the legs.

The patient is a slenderly built, fair-haired woman, 5 feet 4 inches in height, and weighs 7 stone 12½ pounds. She was born at Frittenden in Kent. Her complexion is rather pallid and yellow, but there is a little colour in the cheeks, and some pigmentation round the eyelids. The teeth are fairly good, tongue clean, mouth natural, mucous membranes rather anæmic. She has three brothers and one sister, all in good health, older than herself. Her parents are living, her father is healthy, her mother has "rheumatic hands." There is no history of any similar ailment in any of the relations, so far as is known.

There is no sign of any thoracic or abdominal derangement. She says she has been delicate for the last seven years, and has felt

poorly at times. During the past year she thinks she has become thinner.

Her appetite is fairly good, bowels regular, catamenia regular, The urine is sometimes muddy, probably with urates. Sleeps badly, disturbed by rheumatic pains.

Remarks.—This case illustrates most plainly the association in one patient of the two varieties of scleroderma. The disease manifestly began in the circumscribed form on the left thigh, and slowly spreading for a time, appears to have somewhat subsided in that region. After a time, there ensued some subacute rheumatoid affection, of wide articular range, and, whether on the passing away of this any general hardening of the integuments of the limbs occurred, it is not easy to determine.

It seems fairly certain that a second outbreak of localised scleroderma took place about five years after the first patch was discovered, also on the same limb, below the knee, and this likewise spread and became connected with the older indurated area.

It is, of course, possible, that this was not the real order of the phenomena, and that the sclerosing tendency has been all along progressive in varying degree, but most marked in the circumscribed form on the left lower extremity. In any case the contrast between the localised affection on the thigh, and that on the hands and forearm is most marked, and accords fully with some previously observed instances of the malady. The two varieties blend together on the left lower extremity.

The hands in this instance resemble very much those met with in many cases of chronic arthritis, in which the skin is contracted and tightly drawn over the joints. It is of interest to note that rheumatic affections appear to precede this disorder with some frequency, and also that the female sex suffer more than the male in the proportion of three to one.

The disease began and fell with most severity, especially in the circumscribed form, upon parts of the integument supplied by the internal cutaneous and long saphenous branches of the left anterior crural nerve. *May* 18*th*, 1880.

Postscript.—This patient has been in St. Bartholomew's Hospital for about one month, under treatment consisting of cod-liver oil internally, bathing, soaking of the arms in warm water, and frictions with liniment of iodide of potassium and soap. A considerable

amount of fine downy hair has made its appearance on the backs of the arms and hands. *July 9th*, 1880.

---

3. *Case of Sclerema.*

By W. E. STEAVENSON, M.B., introduced by Dr. BARLOW.

THE cause of death of the child whose body I exhibit this evening has been the subject of a coroner's inquiry; and as there were several interests involved, and a conflict of evidence, I was called upon by Dr. Hardwicke to make a *post-mortem* examination.

I did not see the child during life, but, as the history of the case has possibly some bearing on its pathology, I will shortly state the facts.

The child (a male) was born on December 10th, 1879, and had been brought up by hand, contrary to the wishes of the medical man who had been called in to attend it. The mother was in the habit of increasing her income by some daily occupation, which necessitated her absence from home. The child was therefore left each morning at a *crèche*, and fed upon condensed milk. The medical man above alluded to considered that he had reasons to believe that condensed milk acted in a deleterious manner on many young children, and had condemned its use.

On the death of the child the medical man gave a certificate, implying that it had been accelerated by neglect and starvation. This reflected unpleasantly upon the *crèche*, and the mother of the child brought a counter-charge of improper treatment against the medical man. To smooth down this unpleasant combination of recriminations my services were called in.

The child died on February 22nd, being then ten weeks old, and the *post-mortem* examination was made on the afternoon of the 28th, after the lapse of nearly a week. The weather was particularly mild for the time of year, but the first appearance of the body suggested that it had been frozen. The skin presented a firm, resisting, leathery condition—in places almost as hard as a

board. No indentation could be made by pressure. The hardness was particularly marked on the buttocks and cheeks. Those parts of the body which are destitute of fat, viz. the penis, scrotum, eyelids, alæ of nose, ears, and lips, had the ordinary flaccid feel, and were undergoing early *post-mortem* changes. The body weighed eight pounds. There were no marks of violence, no beading of the ribs, and no sign of rickets. The child appeared fairly nourished; there was no approach to emaciation. The subcutaneous adipose tissue resisted the progress of the knife as does suet. Even the fat in the omentum and around the kidneys had the same suety appearance and feel.

Larynx and *trachea* healthy.

Lungs everywhere healthy and crepitant, except a small portion of the left lung at its lower and most posterior part, which was collapsed, and contained some slightly puriform mucus. No mucus above.

Heart healthy; right ventricle distended with dark currant-jelly clot.

Stomach healthy; *spleen* small but natural.

Intestines natural; contained bile-stained, semi-fluid substance, evidently the remains of some food which had been swallowed. Large intestines contained fæces. Mesenteric glands natural.

Kidneys natural; capsules easily removed.

Brain in a very soft condition, most likely from length of time which had elapsed since death. An increased quantity of pale serosity was contained in the subarachnoid spaces. Sinuses of the dura mater contained firm, partly decolorised clot, especially in the lateral sinuses, but this did not extend into jugular veins.

This case illustrates, most forcibly, the desirability of having skilled pathologists attached to the coroners' courts. If the *post-mortem* examination had been made by an average general practitioner the chances are that great injustice would have been done to one party or the other. There is every excuse for the medical man for not having diagnosed the case; and not knowing what ailed the child, instead of inventing a disease, he attributed the death to neglect and improper feeding, and it is very possible that there was some neglect on the part of the mother, but not enough to cause the child's death. And, again, the newspaper press would have been only too glad to have got hold of a sensational story of starvation, which would have implicated the authorities of the *crèche*.

I do not intend to hint that I am a sufficiently skilled pathologist for medico-legal cases, for had I not had the assistance of Dr. Thomas Barlow, who has seen three other cases of sclerema, I should have been at a loss to account for the peculiar appearance the body exhibited in this case, having never seen one of the kind before.

Sclerema is a disease which is very rare, although it has well recognised features. Among the large number of children treated at the Hospital for Sick Children in Great Ormond Street only about four cases of sclerema have been seen in the last six years.

Dr. West calls it *induration of the cellular tissue*, and considers it may be due to an unexpanded condition of the lungs. But in the case before us the pulmonary collapse was certainly of itself not sufficient to account for death, nor could it have been sufficient to cause serious disease, and, above all, the pulmonary collapse was of recent date, but the disease must have been some time in progress.

It has occurred to me that the disease may be due to some derangement of the fat-forming functions of the body; that, instead of fat being formed, consisting of the proper proportions of olein, stearin, and palmitin, from some unexplained cause a substance is produced containing a larger proportion of stearin and palmatin, resulting in a compound which is solid at the ordinary temperature of the body. The fat, also, in this condition, cannot be readily decarbonised, and the animal heat, therefore, not properly maintained. In cases of sclerema the temperature of the body falls as low as in cholera, and is usually not above 70°; but in this case I could get no report that the temperature had ever been taken. In sclerema, therefore, the conditions react upon each other, the existing fat requiring a higher temperature for its liquefaction, and the condition of the fat being such that the animal heat cannot be maintained, even at its normal height.

Should this theory of improper formation of fat prove the true cause of the disease, the source from which the fat is derived would be a very important element in the question.

There is little doubt that the fat in infants is derived from the casein in the milk; and the undue amount of casein in condensed milk, or in simple cows' milk, as compared with human milk, may be the cause of the disease. Sclerema seldom or never occurs in children properly suckled, but is comparatively common in the foundling hospitals of France and Germany. *March 2nd*, 1880.

4. *Xanthelasma multiplex. Disappearance of the patches.*

By J. Wickham Legg.

It may be worth while to record the following case of spontaneous recovery from xanthelasma multiplex; the xanthelasma was well marked in the third year of jaundice, but had almost wholly disappeared in the sixth year of the patient's illness.

James P—, aged 32, was admitted into St. Bartholomew's Hospital as an out-patient, under my care, Sept. 24, 1873.

He says he is unmarried, but that he has never had syphilis or gonorrhœa. He has been a teetotaller since 1863. He has always enjoyed good health; in eighteen years he has only been away from business two hours owing to ill-health.

He has been jaundiced now for three months. He has been over anxious of late about business.

Present state.—The colour of the skin is a deep sallow, unlike ordinary jaundice; the conjunctivæ are blood-shot, and do not at first sight strike observer as being icteric. On close examination they are plainly so. The urine high coloured, but contains no albumen, and on being tested with nitric acid in Gmelin's way, there is no trace of a green colour, nothing but a red ring above the nitric acid is found. The stools are said to be now of a fawn colour; under the club doctor they were dark. Liver dulness (absolute) begins two fingers' breadth below nipple and reaches down to the level of the umbilicus. The liver can be felt below this; it does not cross middle line. It is slightly tender to feel; its surface smooth, save just below the junction of the ribs and cartilages, where a rounded smooth swelling, the size of a small apple may be felt. The belly somewhat retracted; not tender generally. The pulse is 18 in 15″, intermittent about 1 in 18.

There is much itching, especially about the thighs at night. He does not complain of any pain. His chief trouble is his weakness and loss of flesh.

To take the nitro-muriatic acid draught.

Oct. 8. Liver dulness as before. Epigastrium slightly tender. The splenic dulness is enlarged and the tip can be distinctly felt under ribs. Pulse 22 in 15″, not intermittent but very small.

There is no murmur at heart; second sound at base reduplicated. Weight remains about the same.

11th. The edge of the liver is rounded to feel; motions of a light yellow colour. The conjunctivæ are now markedly jaundiced; the urine bilious, but contains no albumen. A beautiful green reaction is given with Gmelin's test.

15th. He ate two pears yesterday and has been much purged; does not feel so well in consequence. Jaundice the same. There is no xanthelasma palpebrarum.

29th. Epigastrium still tender. Liver dulness as before; edge as before; the rounded swelling as before Jaundice somewhat less. Pulse 18 or 19 in 15″. The urine shows no albumen, but a slight green reaction with nitric acid. There is no xanthelasma to be seen anywhere. The man says he feels stronger. Tongue very red, cracked across. To-morrow he goes to St. Ives to live.

Dec. 3. He came up to-day from St. Ives, where he has been for the last six weeks. He says he has gained two or three pounds in weight, but he still complains of itching; the jaundice is now only slightly marked; the urine on the other hand very highly coloured; on boiling and adding nitric acid a faint cloud appears; there is deep green reaction with nitric acid. There is a general bulging of the lower ribs on the right side. The deep liver dulness begins at nipple, but is not absolute for two fingers' breadth below. The dulness now extends below ribs for three fingers' breadth. Tympanitic sound to the left of the middle line. The liver can be felt almost to level of umbilicus. Tip of spleen also distinctly felt. Pulse 20 in 15″, not intermittent. Stools now light drab.

He has noticed no changes in perception of colours during illness. The conjunctivæ are much injected. A few yellow spots the size of pin's point around inner canthus of eyes.

To continue the draught of nitro-muriatic acid.

Aug. 12, 1876. He came to see me again. For several months past he has been living in North Staffordshire, working at the pottery business. He is in London for a day.

He has now well-marked xanthelasma multiplex. There are large symmetrical patches on the inner aspect of both eyelids of the plane variety. On the upper right eyelid is a tuberose patch the size of a pea. There is none on the face or head, if a doubtful spot on the lower lip be excepted. None on front or back of trunk, until

the cleft of the nates be reached; on each side of the upper part of this cleft is an abundant crop of prominent tuberose xanthelasma. In the middle line of the sacrum there is an oblong patch of xanthelasma planum. On the arms there is none, save about both elbows; the olecranal surface is studded with the tuberose form; the flexure with the plane. There is one small tuberosity on back of right hand; the flexures of both palms and of the fingers are marked by broadish lines of linear xanthelasma.

There is a patch of plane xanthelasma at base of penis and another in middle line of perinæum. There is none on the thighs and legs. But on the left sole, just where the great toe joins the foot, is a streak of linear xanthelasma.

There is no xanthelasma on tongue; nor as far as can be judged on gums. He wears false teeth.

He has been slightly jaundiced since his last visit. He scratches his thighs much, but says this is due more to habit than real sense of itching. Conjunctivæ still coloured yellow; but the complexion is very peculiar, not jaundiced, but very dark; in a healthy person it would suggest an infusion of black blood. He has black hair. The urine is high coloured and looks bilious. It does not stain yellow white paper, nor does it give a green colour with nitric acid. After being boiled nitric acid causes an opalescence.

He says he first began to notice the xanthelasma in his hands the spring of this year; he does not remember in what month. He thought the patches were due to the cold weather. He has been jaundiced continuously for three years.

The liver dulness now begins two fingers' breadth below nipple, and reaches to a finger's breadth above border of chest. In axillary line it reaches to border of chest. It cannot be felt, neither can spleen. The tongue is red and fissured. The appetite is bad. He, however, considers himself stronger and better than he was three years ago.

He was heard from on Jan. 4, 1877; he said, "The white marks upon my hands are less plain, but I have such a habit of rubbing myself and rubbing off any little scar or head which are (*sic*) felt moist when warm."

Oct. 18, 1879. He again reported himself to-day. He is still slightly jaundiced and looks thin. He is able to do some slight work, such as that of a clerk or book-keeper.

The patches of xanthelasma have everywhere, save on the eyelids,

disappeared. The palms of the hands, the elbows, the nates and sacrum, penis and perinæum, and the left toe, are free from all traces of the disease. The skin is quite smooth and supple, and it is hard to believe that it has been the seat of so extensive a pathological change. Over the elbow there is some roughness, but it is doubtful whether it be more than is common; and there are one or two scars, caused, he says, by his tearing the tubercles out with his nails, which then bled plentifully.

He cannot remember the exact time at which the patches began to go away, but thinks it was about the beginning of 1877. No treatment was adopted with a view to their removal.

There is still the same marked bulging of the lower right ribs, and the liver's thin edge can be felt just under the margin of the ribs; the spleen can also be distinctly felt. The liver dulness begins three fingers' breadth below nipple line, and at the same distance in parasternal line, but very quickly is succeeded by a tympanitic sound.

The urine is still bilious to the eye, but gives no distinct Gmelin's reaction.

In June, 1880, he came to see me again. He was very weak. There was no change as to the xanthelasma, save that the patches on the eyelids were somewhat smaller.

Recovery from xanthelasma has not been often seen. Mr. Hutchinson was of opinion that in the palpebral form of the disease, the patches either increased or remained stationary.[1] The only well authenticated case that I have heard of in which the patches became smaller, is that of Dr. Frank Smith, which was brought before this Society some few years ago by Dr. Pye-Smith.[2] In this case there seems to be good evidence that the linear xanthelasma on the palms of the hands had entirely disappeared, and that the nodules on the hands, knees, and feet were daily decreasing. It appears, too, that mercury had been given during this decrease in size, but it was asserted that the decrease was noted before the course of mercury was begun. In the case now published no treatment was adopted.

The spontaneous disappearance of the disorder seems to me to throw some light on its pathology. If the patches can so completely disappear and leave behind perfectly natural skin, it would

[1] Jonathan Hutchinson, 'Med.-Chir. Trans.,' 1871, vol. liv, p. 180.

[2] W. Frank Smith, 'Trans.,' of this Society, 1877, vol. xxviii, p. 236.

seem to destroy the theory that they are due to a fatty degeneration, a process akin to that of atheroma. The view which this case favours is that the patch is due to a fatty infiltration of the subcutaneous connective-tissue corpuscles; and that, with the absorption of the fat, the skin returns to its natural state. With a true degeneration this could hardly take place. *October 21st*, 1879.

---

5. *A case of varicella gangrænosa.*

By JOHN ABERCROMBIE, M.D.

I HAVE brought this body here to night as an example of an unusual form of ulcerating lesion of the skin, similar in many respects to one that was exhibited a few months ago by our President before another society.

The point of especial interest in this case is that the starting point was undoubtedly varicella. I have to thank Dr. Dickinson for his permission to bring the case forward.

The following are the notes :

George W—, aged fourteen months, was admitted into the hospital for Sick Children, Great Ormond Street, on January 27th, 1880. A fortnight ago his mother noticed an eruption of small spots with watery heads, these continued to come out for about three days, since then some of them, especially those about the head, have not healed, but have gone on to form holes and spread. He has a troublesome cough, but takes his food well. He was weaned a month ago.

Never a strong child; no symptoms of syphilitic taint. He has not been subject to intestinal trouble.

There are two other children alive, none have died.

Parents healthy.

One of these children and three others living in the house had varicella at the time when this child's eruption came out.

State on admission.—An ill-nourished, wretched-looking baby. Over the left parietal region is an oval ulcer an inch and a half long by half an inch wide, with somewhat sharply cut edges; the slough has separated leaving a base formed by the tendinous aponeurosis. There are two similar but smaller ulcers, one just in

front of this, the other over the right frontal region; the sloughs have not yet separated from these.

On the left side of the forehead and left cheek are two small, circular, punched-out sores, each about the size of a threepenny piece.

Similar, but smaller and more superficial, sores are present beneath right clavicle and on buttocks.

The eruption is not symmetrical.

Some sharp moist râles can be heard over both backs and at right anterior base.

Nothing occurred worthy of note after his admission. He took his food very badly and gradually became weaker; the ulcers increased in size a little.

He died on February 1st.

On examination of the body, thirty-two hours after death, there was found some pneumonia of both lungs, with recent pleuritis on right side.

There was one small ulcer just above the ileo-cæcal valve, and in the mesentery opposite the cæcum there was a caseous mesenteric gland about the size of a marble; there were also a few smaller caseous glands here.

It is worth mentioning that after this child came into the hospital the remaining child developed varicella at home.

February 3rd, 1880.

---

6. *A case of lichen ruber* (?)

By W. Morrant Baker.

The case brought before the Society is that of a woman, æt. 53, who is suffering from a disease of the skin, which began two years and a half ago.

The disease affects both the trunk and extremities, but more particularly the extensor aspects of the upper and lower limbs. Here it appears in the form of large raised patches of thickened skin, of a dark colour, and dry, rough, almost warty surface, like sand-paper, with here and there a tendency to desquamate slightly in

very fine scales, but nowhere weeping or scabbed, excepting parts at which, from intense pruritus, the tops of some of the smaller tubercles and papules have been scratched off, and present a pruriginous, blood-scabbed appearance. The disease has been probably lichenoid or at least papular, and the large patches are formed apparently by the coalescence of papules and tubercles, which, in other parts, remain still individualized. The outline of the large patches is irregular, suggesting a coalescence of papules rather than an extension by increase from a centre.

The skin, not only in the situation of the rough raised patches, but in the intervals, is darkly pigmented, as in a very old case of phthiriasis, and this pigmentation is present to some extent in every part of the body. The dark colour, it is stated by the patient, has been present for two years.

The palms and dorsal aspect of the hands are both free from the disease. The soles of the feet are also free, but the dorsal aspects are affected. The scalp is also free from the disease, and the face almost entirely so; although the complexion is very dark, and is stated by the patient to have become so only within the last year or two.

On the outer aspect of the forearms, near the elbow, are a few dark red patches, less raised and warty than the others, and looking, as to texture, like those of a mild case of lichen ruber.

One might say that in one part the disease looks like an exaggerated prurigo, in another like a psoriasis—papillary not scaly or scabbed—and in another like lichen ruber.

The general health of the patient is good; but her rest has been much broken by the almost intolerable itching which she suffers on account of the eruption, and which is but slightly amenable to local or constitutional remedies.

It seems to me not at all easy to decide with certainty as to the nature of the disease, but, on the whole, I am disposed to regard it as lichen ruber, and to consider that its exaggerated features are due to its unusual development and long continuence; its typical aspect being materially interfered with by the mechanical irritation to which it has been subject.

The distribution of the diseased patches of skin resembles closely that which is more often seen in common psoriasis or lepra; and the term "papillary psoriasis" seems at first sight very applicable. But, essentially, true psoriasis is not a papillary disease, even in

its most exaggerated forms; and it appears to me best, therefore, not to include under this head a disease in which the papillary outgrowths of skin are so well marked, especially in the earlier stages of its progress, and in parts where its true characters have been less obscured by the secondary effects of long-continued irritation. *April 20th*, 1880.

---

7. *Melanosis of finger.*

By Rickman J. Godlee.

The patient from whom this specimen was removed was a girl, æt. 9, of a fair complexion, and otherwise quite healthy. Four years ago the last joint of one of her fingers became swollen; it was of a pale colour, and the swelling was attributed to a habit of sucking the finger. A year afterwards, *i. e.* three years ago, a small black spot made its appearance; it was pricked several times, and is said to have disappeared, and then to have recurred. Other spots began to form about a year ago; all at first were very small, but gradually increased in size, the original one, however, always remaining the largest. At one time sensation is supposed to have disappeared from the finger, but this is not certain, as, at all events, it was present when the patient was examined.

Poultices were applied before the spot appeared, and, with the occasional use of a water dressing, were the only form of treatment tried.

She was born in England, of English parents, and has lived in England all her life.

When Mr. Heath saw her the last joint of the finger was swollen, of a pale colour, not tender, and marked by about a dozen small black spots, the largest of which was not more than one sixteenth of an inch in diameter. The last phalanx was at once amputated.

I fully expected to find that the microscopical appearance of the growths would be that of melanotic sarcoma of the papillæ, but the appearance was quite different. Each black spot extended only as far as the deepest part of the papillary layer of the skin, and

less deeply at the circumference of the tumours. Each was composed of a number of flattened trabecular spaces, placed one above the other, the trabeculæ being formed by epidermic cells.

In the spaces was contained a brown-red material, which, on section, appeared amorphous, but which, on tearing out, seemed as if it might be made up of altered epidermic cells. The colour suggested the idea of altered blood, and in some of the spaces, from which the pigment had escaped, altered red blood-corpuscles were seen in abundance adhering to the trabeculæ.

Round the margin were found epidermic cells filled with brownish, apparently oily, material. I am at a loss to know in what category to place these little growths; the structure suggested the possibility of their having been formed by a succession of minute vesicles, into which hæmorrhage had taken place. *April 6th*, 1880.

---

8. *On the histology of elephantiasis arabum and its relations to normal connective tissue.*

By George Thin, M.D.

[With Plate XX, figs. 1—4.]

At a recent meeting of the Society, the President showed a specimen of elephantiasis of the prepuce, and invited the members to take portions of the growth for examination. I prepared and examined a part of the elephantiasis tissue, with the object of studying the nature of any cellular elements I might observe, hoping that the demonstration of the connective-tissue cells in the comparatively soft tissue would prove easier than it is found to be in ordinary normal fully developed fibrous tissue. This expectation has been verified. In a portion of the tissue, which was hardened in bichromate of potash, many cells were preserved, and in sections made from it they were conspicuous objects after eosin and logwood staining. The growth consists of an incompletely developed fibrous tissue. The bundles, in parts where they have been formed, are smaller than those in normal skin, and have less uniformity in thickness than they have in ordinary cutaneous or subcutaneous tissue. In some parts the stage of bundle-formation has not been

reached, the gelatinous element being found in the condition of fibrils of varying thickness.

Numerous cells are found scattered singly throughout the fibrous tissue (fig. 1), and at some parts they are arranged in groups which have an endothelial (or epithelioid) appearance (fig. 3). The endothelial arrangement is found in the tracts of fibrous tissue which surround the larger blood-vessels, and in this position has a resemblance to that of the cells which lie on the bundles of young tendon. Whether they are solitary or in groups, these cells have clearly-bounded contours, and in no instance have I observed a trace of a cell process. The smallest cells consist of a round nucleus with a mere trace of cell-substance, and are indistinguishable from ordinary lymph corpuscles. The larger cells resemble typical endothelium. In a very few instances, in small cells, instead of the ordinary nucleus, two small round nuclear elements were seen, their combined area, however, not exceeding that of an ordinary nucleus.

There were no appearances indicative of any process which could be described as a multiplication of cells by division, and as all transition stages were found between the cell resembling a lymph corpuscle and the largest of the endothelial cells, I infer that the whole of the cells present are derived from the white corpuscles of the blood.

The appearances observed do not support the statement of Rindfleisch that the cells multiply by division, nor the remarks in Hebra and Kaposi's text-book in this connection. These authors remark that stellate cells, with one or more nuclei, and with processes which are continued as fibres, are found in elephantiasis tissue. That I have not seen appearances which could be so described in my preparations I attribute to successful hardening, which has preserved both the cell and the nucleus entire, permitting the contour of the cell to be preserved as an element distinct from the tissue on which it lies.

Scattered through the tissue are many groups of smooth muscular fibres of new growth.

(Cornil and Ranvier remark that groups of smooth muscle have been described by some authors in elephantiasis growth, but I have not found any allusion to the fact in the works of Rindfleisch or Hebra.)

The nature of the cells found in elephantiasis has a bearing on the important question of the nature of connective-tissue cells in

the normal tissues and their relation to the substantia propria or ground substance. Histologists are not agreed as to what constitutes the connective-tissue cell, which is variously described as a branched element with anastomosing processes (Virchow, Stricker, Spina), as an element compounded of a central plate with fringes or wings (Waldeyer), as a flat cell with and without processes (Ranvier and his school), and as a flat somewhat rounded cell (Key and Retzius). In the 'Proceedings of the Royal Society' (No. 155, 1874) I described the connective-tissue cell of the subcutaneous tissue as a rounded or somewhat oblong, flat, endothelial cell, without processes, and arranged cell to cell like an endothelium. The cells in elephantiasis tissue are analogous to the cells described in that paper, being flat, unbranched, and applied to the surface of the bundles of tissue, but not incorporated with the fibrillary substance. In order to make this clear, I have drawn a cluster of cells from the subcutaneous tissue of the mouse for comparison with the elephantiasis cells (fig. 4). The preparation from which they are taken was obtained by the interstitial injection of nitrate of silver whilst the body of the newly-killed animal was still warm, and is the same preparation that supplied material for the drawing (Pl. IX, fig. 8) in the paper in the 'Proceedings of the Royal Society,' to which I have referred. *April 6th*, 1880.

---

9. *On the fungus of tinea imbricata* (*Manson*).[1]

By George Thin, M.D.

The disease described by Dr. Manson, of Amoy, China, as tinea imbricata, is the affection which has been termed eczema marginatum by Hebra, lichen marginatus by Wilson, being popularly known in Eastern countries as Burmese ringworm, washerman's itch, &c. Of late years the opinion has been held, almost unani-

[1] The appearances described in this paper represent some of the results of an investigation into the nature of the parasitic diseases of the skin, undertaken with the assistance of the Scientific Grants Committee of the British Medical Association.

mously by dermatologists, that the disease in question is nothing more than ordinary tinea corporis, and that the fungus found in the epidermic scales of the affected surface is the ordinary trichophyton.

Dr. Manson has published in the 'Chinese Imperial Customs Gazette,' for 1879, a report of a series of investigations which in his opinion show that this view is not correct. He inoculated the same individuals with scales from an undoubted ordinary body ringworm on one arm, and from the variety which he terms tinea imbricata on the other, and he found that they both bred true, and that two distinguishable parasitic skin diseases were produced on the same person. He has further described the fungus of each variety as being distinguishable under the microscope.

Dr. Manson sent me epidermic scales from one of the cases of tinea imbricata, closely packed in lead foil, and a drawing shown to the Society represented some of the mycelium and spores found in them under the microscope. The quantity of fungus found in the scales was very great, and, as has been described by Dr. Manson, the mycelium observed varied very much in size. When seen under a magnifying power of 500 diameters the finest threads were seen as delicate lines. The largest mycelium I observed was about one half broader than the mycelium of ordinary ringworm. There was a considerable amount of mycelium of the same breadth as the mycelium of the trichophyton tonsurans, and not differing from it in appearance.

In estimating the importance to be attached to these appearances, the probability of an admixture of other fungi than those specific to ringworm in scales exposed on the warm moist human body in hot climates, must be taken into account, but in view of the apparently crucial inoculation experiments made by Dr. Manson the results of microscopic examination have a certain value.

March 2nd, 1880.

10. *Case of molluscum contagiosum. Illustrated by a drawing and microscopical sections.*

By James Startin.

The case was that of a male child, A. S—, æt. 18 months, who was brought to me in July, 1878, with an eruption of these warts over the right eye. The mother states the child contracted them from the sister, and had them about a fortnight, and that they were now increasing in size and beginning to ulcerate.

I expressed the contents out of one or two of the tumours, and examined them under the microscope. They appeared to be composed chiefly of these mollusc bodies and clear cellular bodies, very refractile, containing granular matter very similar in character to those cells seen in the expressed contents of a comedo, and seemed to me to be cast off sebaceous cuticular cells.

A vertical section was made through one of the tumours, and in those cells seen nearest the centre of the tumour these mollusc bodies are observed somewhat crowded into the substance of the acini; vacuolation is seen to be complete in some instances, in others in process of formation, and the mollusc body is filled with an oily granular substance. There is also noticed considerable hyperactivity of the gland substance; for it is a gland, or, as I firmly believe, an abortive attempt at gland formation. The acini are increased in size and distended by the mollusc bodies, and so the tumours are quickly formed. The increase of the ordinary gland cells is very active, and those of the next cells in order, those connected in their formation from the perverted sebum. Vacuolation of the protoplasm probably takes place, and the vacuoli become rapidly filled and distended.

I am led to think that these tumours, after careful microscopical examination, containing the mollusc body, are an independent perverted or abortive gland growth, not taking origin in the already formed "sebaceous" gland (Tilbury Fox), or in the rete-Malpighian layer of the skin (Sangster, Thin, and others), but think they are essentially glandular in their origin, and are formed in the same way as the sebaceous gland, only wanting perfection, and that all three layers of the skin enter into their formation, in an abortive,

perverted, inactive gland; and I form my conclusions for the following reasons:

1st. That these tumours are always seen in those parts of the skin usually occupied by sebaceous glands.

2nd. That the mollusc body is never seen wandering outside the septa of its glandular body.

3rd. That the nature of the contents of the tumour is essentially similar to that of the sebaceous gland, only that it has in addition the mollusc body.

4th. That it contains the ordinary but perverted characters of the sebaceous gland, viz. (1) the numerous acini, but increased in size. (2) Increased endogenous growth of the ordinary gland cells. The cells become vacuolated, and the mollusc body is quickly formed and filled with perverted sebum, an oily granular matter, no doubt the principal source of contagion.

5th. That all three layers of the epidermis enter into the formation of this abortive gland and its contained mollusc bodies.

These characteristics seem all to show that the tumour is essentially glandular, of a *perverted or abortive sebaceous nature*, which is a strong evidence in the favour of their origin from this source, and that they are generally to be met with on the skins of those patients who show various other signs of perverted nutrition; and like other formations of an abortive nature, are very prone to contagion when they meet with a suitable soil, by reason of their degenerate and rapidly cell-forming power never arriving at their proper maturity. *March 16th*, 1880.

---

11. *On a peculiar papulo-vesicular eruption (lupus lymphaticus).*

By JONATHAN HUTCHINSON.

With microscopic examination by ALFRED SANGSTER, M.B.

[With Plates XXIV and XXV].

I AM indebted to the kindness of medical friends for the opportunity of recording together the particulars of two examples of a very rare and probably hitherto undescribed malady. The two cases were, as the portraits will prove, exactly alike. The subject of the first was sent to me by my colleague, Mr. Waren Tay; that

DESCRIPTION OF PLATE XXIV.

Illustrating Mr. Hutchinson's Cases of Papulo-vesicular Eruption on skin or *Lupus lymphaticus.* (Page 342.)

The upper figure represents the eruption on the shoulder in Case 2.

The lower figure the eruption on the chin in Case 1.

See also Plate XXV.

of the second was a lad under the care of Dr. Hayes, at the Evelina Hospital, to whom I owe my best thanks for their courtesy in permitting me to study and publish them.

In each of the two cases the subject of the eruption was a young boy; in each the eruption occurred in one single group; in both it had been of long persistence, and showed no tendency to change; in both the characters were precisely similar. In one the chin was the region affected, in the other the left shoulder. I will give a few particulars regarding each separately, and then add some remarks on the nature of the eruption, which will be applicableto both.

Case 1.—Frank G— was ten years old when he came under my observation as a patient at the Hospital for Skin Diseases, in January, 1878. There was nothing special to be noticed as to his constitution or state; he appeared to be in good average health. The group of spots had begun by what his mother said looked like a little wart on the middle of his chin, almost a year before I saw him. It had spread very slowly, and for some time had appeared to be stationary. He had no warts or other eruption elsewhere, and had never had any, with the exception of a single wart on one little finger some time ago.

Description of the eruption.—The middle of the boy's chin was occupied by a patch as large as a penny and made up of coalesced clusters of small papules. At first sight these looked like low warts, but on minute inspection no proof of papillary outgrowth was obtained. On the other hand, many of the little eminences were translucent, and clearly contained fluid. On several different occasions I pricked many of these microscopic cysts and obtained clear fluid. After emptying they always filled with blood.

The apices of the little papules were speckled over with tufts of vessels. These tufts were most of them bright in colour and varied in depth, some being purple. They gave a decided character of bright mottling, almost strawberry-like, to the whole patch. Examined by magnifying power they are seen to consist of minute tufts of capillaries, many of them too small to be visible to the naked eye, and the largest little bigger than a pin's point.

From this case portions of skin were excised for microscopic examination. These are the subject of Dr. Sangster's report, which is appended.

I shall not enter on questions of treatment further than they concern pathology. In this instance, in addition to the excision of

portions, we destroyed others by cauterisation, at one time with nitric acid, at another with the actual cautery. The disease showed remarkable resistance, and wherever portions were left not wholly destroyed the original conditions were soon reproduced. Although much better, the case is not yet cured.

CASE 2.—Patrick H—, æt. 7, came under the care of Dr. Hayes, at the Evelina Hospital for Children, in the spring of 1877. The portrait, which is copied in Plate XXIV, was taken in June of that year. He had a large patch of eruption on his left shoulder, just where his braces rubbed him.[1] His mother said that it had been present three or four years, and had not altered much. It was not sore, and caused no inconvenience. At the age of three years he had a fever, and this patch was seen soon afterwards. He had no skin disease elsewhere. After the portrait was taken (1877) the boy remained under my occasional observation for two years, and during this time no material change took place. He had no regular treatment. I showed him to the Society in December, 1879, and on comparing his condition then with the former state as shown in the portrait, it was found that the *status quo* had been maintained most exactly. The only observable difference was that some of the smaller patches, where his clothes pressed, had ceased to look granular or to show vesicles, and become flat, solid, and somewhat polished.

Description of the eruption.—The patch consisted of a group as large as the palm, made up of clusters of spots, some isolated, others aggregated and confluent. These clusters were some of them roundish, others very irregular, and all consisted of pale spots about as big as pins' heads, which were slightly raised, and many of which looked translucent, whilst a few were blood stained. The skin between the clusters was pale. That many of the spots were really vesicular, or, at any rate, contained fluid, was easily proved by examining them with a lens, or by pricking them. When pricked a clear fluid was easily obtained, which, under the microscope, showed cells like those of lymph. There were no papillary outgrowths. In many of the spots minute ecchymoses had occurred, and in some tufts of vessels were seen, in most of which, however, the blood appeared to be coagulated. The skin around and between the papules was healthy, and only a little congested close to the

[1] The portrait, sufficiently faithful in other respects, is not so as to the exact position. The patch looks lower down on the deltoid than it really was.

bases of the spots. The character of the eruption was remarkably the same at all parts, varying chiefly in the presence or absence of capillary tufts and of vesicles.

General remarks.—It is not very easy to assign with confidence the clinical relationship of these cases. The history in each of long duration and no change, would imply probability that they were due to some local influence, that they belong to the class of local maladies. No doubt some slight predisposing influences in respect to age and other unassignable peculiarities must be recognised, but still, in the main, a morbid change which persists for years and does not spread must rank as local. Should they be considered as warts, as a form of lupus, or a variety of nævus? The alliterate designation vascular-vesicular-verrucæ was at first suggested as appropriate, but on closer inspection it seemed doubtful whether they could claim any real alliance with warts, there being no proof of papillary overgrowth. Nor perhaps is it certain that they are vascular, the presence of thrombotic tufts being possibly due solely to local injury. Lastly, after microscopic examination the applicability of the epithet vesicular, in its strict dermatological sense, might perhaps be disputed. That they are not of the nature of nævus or mole is rendered almost certain by the fact that in neither case were they observed till some years after birth. On the whole their alliance with the various affections which we group together as lupus appears the most close. The age of the patients, long local persistence, incurability, and above all their mode of spreading by the appearance of fresh spots near to the parent one, all fit well with what occurs in lupus. It would appear that the process once commenced was infective as regards adjacent points, and could spread not only by continuity of tissue, but by proximity. This is the mode of spreading which we constantly observe in the various forms of lupus. Possibly this disease has the same relation to the lymph-system of the skin which lupus erythematosus has to the blood-vessels. The facts established by Dr. Sangster's observations would, I believe, agree with this hypothesis, and the name of lupus lymphaticus or *lymph-lupus* might thus not be inappropriate; at any rate, it may be useful until further researches enable us to speak more confidently as to its precise nature.

I am not sure that I have ever seen any other cases exactly like these. A very beautiful young girl, of eleven, was brought to me this summer with a group of spots on her nose which were causing great

anxiety, and which exactly resembled those in these children, excepting that after careful search I failed to prove that any of them contained fluid. They had been present a few months only, and they disappeared entirely, and to my surprise, under the inunction of a weak oleate of mercury ointment. I much suspect that hers was an example of the disease in its earliest stage. During the last session of this Society, the late Dr. Tilbury Fox[1] exhibited a living patient who had on his thigh a large patch which somewhat resembled those in my cases. The resemblance struck me so much at the time that I took the opportunity of mentioning my cases. There was the difference, however, as to history, that in Dr. Fox's case some congenital peculiarity of the skin of the nature of nævus had been present. On the hypothesis that the disease is of the nature of lupus, however, there is nothing improbable in the suggestion that it might attack a nævus. I have myself recorded cases[2] in which the conditions of nævus and lupus erythematosus were mixed, or respecting which, perhaps, we ought rather to say that lupus erythematosus had attacked nævoid patches. It is also to be borne in mind that in Dr. Fox's case, the vesicular patches did not, as the lad's mother stated, commence until he was two years old, and they were, although in close proximity, apparently not connected with the nævus.

I had the pleasure of showing one of my patients privately to Dr. Tilbury Fox, and I saw his at the Society's meeting. It did not at the time impress either of us strongly that our cases were examples of the same disease. On carefully reading his paper, however, I cannot feel much doubt that they really are so, and such I know is the opinion of his brother Dr. Collcott Fox. The changes in his case were on a much larger and coarser scale than in mine, a fact, perhaps, explained by their association with congenital vascular disease and their longer duration.

December 16*th*, 1879.

Report of microscopical appearances of Mr. Hutchinson's case of vesicular wart-like growth on chin. By A. Sangster, M.B.

On examining vertical sections, the Malpighian layer was seen to

[1] See 'Pathological Transactions,' vol. xxx, p. 470, "On a case of Lymphangiectodes."

[2] See 'Clinical Lectures,' vol. i, "Rare Disease of Skin," p. 284.

DESCRIPTION OF PLATE XXV.

Illustrating Mr. A. Sangster's report on Mr. Hutchinson's Case of Papulo-vesicular Growth on Chin. (Page 346.)

FIG. 1.—From a vertical section:

(*a*) (*a'*) Flask-shaped spaces in papillary layer of conium. (*a'*) is bounded on one side by the vitreous layer of the hair follicle, and on the other by an elongated interpapillary prolongation.

(*b*) Hair follicles, longitudinally divided.

(*c*) Dilated hair follicle, containing hairs, débris, and

(*d*) Acari (Demodex).

(*e*) Spaces, deeper in substance of skin. (?) Dilated lymphatics.

(*f*) Interpapillary prolongation from the rete.

[Hartnack, oc. 3, obj. 4.]

FIG. 2.—From a horizontal section, showing:

(*a*) Lacunar spaces, separated by fibro-cellular septa.

(*b*) Transverse sections of hair follicles.

[Hartnack, oc. 3, obj. 4.]

Above is the outline of an acarus, with (*a*) granular matter in its interior.

Fig. 1.

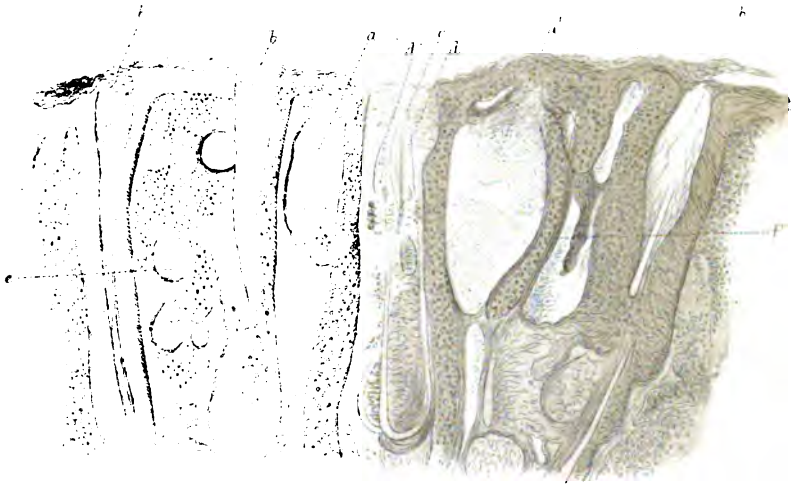

Fig. 2.

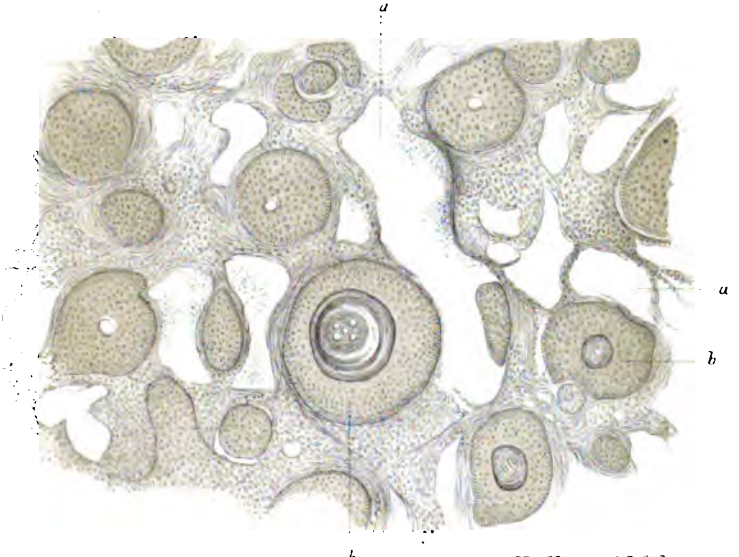

A. Forrester del.

West Newman & Co. lith. et imp.

be hypertrophied, extending downwards in elongated interpapillary prolongations (fig. 1 *f.*). There was no hypertrophy of the corneous layer, such as accompanies true warty conditions. The hair follicles showed various states of disturbed nutrition; in some the root-sheaths were irregular, presenting saccular dilatations; in others the spaces inclosed by the root-sheaths were dilated and filled with *débris* (fig. 1 *c.*). Many contained two, three, and even as many as five hairs (this condition was better seen in horizontal sections (fig. 2 *b.*). More striking changes occurred in the corium; large lacunar spaces occupied its most superficial portion, the largest of them replacing the papillæ. These spaces were variously shaped; for the most part elongated, with the long diameter vertical to the surface, Some were flask-shaped or funnel-shaped, with the small end pointing downwards (fig. 1 *a.*). Interpapillary prolongations from the rete could be traced running alongside of the spaces, the prolongations being evidently pushed aside and distorted by the expansion of the spaces. Some of the spaces were empty; most were filled, or partially filled, with an amorphous granular material, scattered, in which were a few round cells deeply stained, answering in size and appearance to white blood-cells. In a very few instances red blood-corpuscles could be traced in the lacunæ. The walls of the largest spaces were generally uneven, formed by a more or less consolidated layer of fibro-cellular tissue. In extreme conditions the space appeared a mere ragged cavity in fibro-cellular tissue.

There were many smaller spaces, and deeper in the substance of the skin; their outlines tended to become more regular and round, the walls presenting much more the appearance of the adventitia of a vessel (fig. 1 *e.*).

Whilst looking through the specimens an acarus folliculorum was detected, lying free; this led to the careful examination of the mouths of the follicles, in many of which two or more acari were seen; they became readily discernible by the deeply-stained granular matter in their interior.

In this condition of skin it seems that the appearance of vesicles was not due to a simple upheaval of the epidermis by fluid accumulated between the superficial and deeper layers, but that it was caused by collections of fluid in the substance of the true skin.

As to the nature of the spaces containing this fluid, although the specimen did not admit of its demonstration, it may be conjectured

that the deeper ones were dilated natural channels (lymphatics ?), while the superficial flask-shaped cavities seemed to be truly lacunar, perhaps caused by distension and rupture of the lymph spaces in the papillary layer. In some spaces absorption of tissue appeared to have taken place, for their walls were formed by the limiting membranes of the true skin (vitreous layer of the follicle and basement membrane of papillæ). (Fig. 1 *a'*.)

The appearance of the contents of the spaces was also in favour of their having contained lymph.

The occasional presence of red blood-corpuscles answered to the clinical fact of the tendency of the vesicles to become hæmorrhagic.

No significance will probably be attached to the presence of the acari; but it is well to remind ourselves that a serious disease occurs in the dog from the acarus folliculorum. Dr. Sparkes has well described this disease in the 'Transactions of the Med. Chir. Soc.' for 1874.

For information as to microscopical appearances similar to those detailed above, compare

'A Case of Pachydermia Lymphorrhagica' by Odenius ('Nordiskt. Medikinst. Arkiv.,' t. vi, 1874). This case is referred to at length in Busey's work on occlusion and dilatation of lymph channels, pp. 95, 96.

See also, 'Report, by C. Stewart, of Microscopical Appearances in a case of Lymphangeioma,' recorded by Sydney Jones in the 'Path. Soc. Trans.,' 1874—5, p. 233.

Also a case of 'Lymphangiectodes, Account of Histology of,' by Drs. T. and T. C. Fox, 'Path. Soc. Trans.,' 1879, p. 474.

---

12. *A pigmented mole, with elephantoid hypertrophy of the mons and labium; growth after excision and second operation.* (*Card specimen.*)

Exhibited by JONATHAN HUTCHINSON.

A YOUNG lady, æt. 18, is speckled over on face, shoulders, chest, and arms, with many hundreds of small pigment moles. Around the genitals, and on the inner side of left thigh and buttock, was an immense black hair-growing mole. The mons and left external labium were greatly hypertrophied and hung in heavy

pendulous masses. Five years ago I excised a large part of the mass. The wound was closed with sutures and healed immediately. Increase of the adjacent cellular tissue, however, soon recommenced, and the parts became bigger and more pendulous than ever. The skin was black, coarse, tuberculated, and covered with thick bristly hairs. Beneath the skin ill-defined, large masses of dense fibrous tissue could be felt. There was no œdema, and in this the case differed from ordinary elephantiasis. The specimen shown was excised a fortnight before by means of a cautery knife, and the wound left to granulate. The case is of interest as an example of growth of a mole long after the period of infancy. The growth took place chiefly in the subcutaneous cellular tissue, and consisted in fibroid hypertrophy, probably of a kind closely allied to elephantiasis. It is to be noticed that the parts involved in growth are those which often suffer in elephantiasis, and that probably their partly pendulous condition has had much to do with inducing their overgrowth. No tendency to growth has been observed in the other moles, many of which have been destroyed by the cautery. *November, 4th* 1879.

13. *Photograph of a case of molluscum fibrosum, one of the tumours of very large size and pendulous.* (*Card specimen.*)

Exhibited by JONATHAN HUTCHINSON.

THE patient is a Turk. Several small tumours are seen in the back in the ordinary condition of molluscum fibrosum, that is, not bigger than cherries. Three tumours on the left side of the back have, however, grown to a large size, and the lowest of these has become pendulous and attained very unusual dimensions. It is nearly as big as the man's head, and has become ulcerated on its lowest part.

The case is of interest as demonstrating the identity of these huge pendulous masses with the ordinary form of fibrous molluscum. *December 2nd,* 1879.

14. *A peculiar form of mole, "the cock's-comb mole."* (*Card specimen.*)

Exhibited by JONATHAN HUTCHINSON.

THE portrait shows a large congenital mole just above an infant's ear. The mole consists of hypertrophied skin tissues, which are arranged in rugæ or folds with deep sulci between them. These are quite solid and free from nævoid tissue. At its thickest part the mole-structure is a third of an inch, but it becomes lower and lower upwards from the ear until it is finally not distinguishable from the skin.

XI. DISEASES ETC., OF SUPRA-RENAL CAPSULES.

1. *Case of disease of supra-renal capsules.*

By NORMAN MOORE, M.D.

IN the present state of knowledge as to diseases of the substance and of the parts surrounding the supra-renal capsules, every case in which the history and morbid appearances after death can be placed side by side seems worthy of record.

J. W. H—, æt. 25, died in St. Bartholomew's Hospital on September 17th, 1879, and was examined by me thirty-six hours after death.

Supra-renal bodies.—The right was greatly enlarged and very hard. The left was enlarged to a less extent, and, on section, showed a deposit of caseous matter of several degrees of firmness in every part.

The semilunar ganglia were of normal size.

There were no patches of pigmentation either on the skin or within the lips; the darkest place was around the right nipple, but neither nipple was as dark as that of a dark-complexioned person. The skin was sallowish in relation to the general complexion. The hair was brown, with a slight degree of lustre. The body was lean. There was some recent tubercle in the right lung, and some old scar tissue with puckering at the left apex. There was a partial strangulation of a piece of ileum, caused by the adhesion of an omphalo mesaraic diverticulum.

Dr. Southey, under whose care the patient was, has kindly given me the following account of the case during life:

J. W. H—, æt. 26, pipe maker.

Previous health.—Good, with exception of some illness for which he was admitted into Mark in 1876. Not acute apparently, but its nature not to be guessed from his account.

Present illness.—Began gradually. Thought himself well up to

August 1st this year (1879); about then he first experienced pains in his abdomen, general weakness, and shortness of breath; his sight became feeble, and he lost flesh. On August 23rd he took some kind of pill, which purged him several times, and led to his passing blood with each motion on 24th; but from that date up to 27th, on which he was admitted, his bowels acted no further.

Condition on admission.—Abdomen flat and empty, tongue clean and moist. Nothing remarkable about skin. Some tenderness in epigastrium and over colon generally, which felt contracted and rope-like, and contained some scybala. Liver and spleen seemed of natural size; heart normal. Lungs; apex of left seemed less resonant than right, and was tender when percussed.

Bladder normal; urine sp. gr. 1025, no albumen. Fattiness and anæmia were the prominent features of his illness. His pulse was 92; temperature only 97·4°.

I asked had he had dysentery; there was no history appointing it. I examined but found no piles. There was increased pulsation in epigastrium from aorta or cœliac axis.

On 31st he passed a few scybala. A fluid-nourishing diet was ordered, with warm poultices to abdomen.

Course and progress.—Temperature, always remarkably low; on September 6th 96·2°. He complained only of weakness, headache, pressure over eyes, dull aching pains all over him. Vomits occasionally. Ordered on 8th half an ounce of castor oil, with Tr. Opii ♏x; this acted twice, bringing natural stools away.

15th. I was informed that he had vomited always at night, but not during day; but on this day I saw a potful of greenish-coloured vomit he had ejected. I ordered brandy, lime water, and milk, with a small opiate every four hours. He was manifestly sinking; pulse hardly to be felt. His answers to me were clear and natural, but I was told he had been delirious.

Early on morning of 16th, after getting out of bed, he fainted and died quite suddenly, giving little warning.

October 21st, 1879.

2. *Fibrous and calcareous changes in both supra-renal capsules, perhaps of syphilitic origin.* (*Card specimen.*)

Exhibited by Wm. Ewart, M.D.

The patient, a governess, æt. 37, was in a state of considerable prostration when admitted into St. George's Hospital, in the latter half of November, 1879, and unable to give any account of herself. The symptoms of scarlet fever were soon developed, and she died of exhaustion on December 15th, shortly after a recurrence of the rigor, the tonsillitis, and the cutaneous rash, with incipient desquamation. A slight degree of tubular nephritis was found after death, but the other organs were free from disease with the exception of the supra-renal bodies. These were altered in shape and consistence and were partly calcified. The left capsule was broken up into numerous islands of apparently healthy tissue, after the fashion of a syphilitic liver. The calcareous infiltration was most marked in the right supra-renal body, which was but slightly lobulated; its seat was mainly in the cortical matter. The semilunar ganglia were normal. Of the existence of syphilis there was no clear evidence; but a depression of the inner table of the skull was noticed in the left frontal region somewhat resembling the late results of a node.

The skin presented no abnormal pigmentation; it was very pallid. The body was somewhat emaciated.

January 20th, 1880.

XII.—MISCELLANEOUS SPECIMENS.

1. *On a peculiar, circular, wandering rash on the tongue.*

By Arthur E. J. Barker.

This paper is an attempt to group together, for the benefit of those who may meet with similar cases, some facts in regard to a peculiar, circular, wandering rash on the tongue, of which I can find no description so far in the medical literature of this country. It appears to be sufficiently interesting, not only from the fact of its novelty, but from some points about its natural history to be alluded to presently, and also from the discomfort to the patient with which it was accompanied.

The observations are based on two cases, in both of which I had a good opportunity of studying the condition, but especially in the second. For this reason it may be better to take the latter as the basis of this description, premising that as regards appearance, duration, habit, &c., the rash in Case 1 was similar down to the smallest detail, though the family history and the conditions of life under which the two patients lived were entirely different.

Case 2 was brought to me a good many times, and I was thus enabled to make a close and more extended study of it with microscopic examination than of Case 1, though here too, the microscope gave much assistance. I was also able to make a drawing of the condition (shown). Besides this the mother was kind enough to continue to make for me (as she had been voluntarily doing before I saw her first) diagrams showing the extent of the rash at different times. It must be distinctly understood, however, that though these give an excellent idea of the shape, extent, and mode of appearance and disappearance of the latter, they are only to be considered as diagrammatic. But as they were prepared in the first instance, voluntarily by the mother without any suggestion

from me, they possess a certain independent value. This I thought later might be enhanced if they were made at several set times in the day, and I therefore suggested this to the lady, who readily accepted my suggestion. I may say that these diagrams, although more distinctly defined than the rash, are excellent.

The drawing made by myself shows, perhaps, a little more accurately the general appearance of the affection when of about medium intensity. It gave the mother but little difficulty to make these diagrams, as the child willingly held out his tongue for her, seeming thus to seek relief from the intolerable itching with which he was tormented, and which gentle rubbing relieved. Besides this the mother kept me *au courant* with the child's condition during the intervals between his visits to me, which extended over several months. Owing to this, and the intelligent way in which this lady (the widow of a professional man) gave me all the necessary details as to family history, &c., and carried out instructions, the history of the case is a much more complete one than it is often possible to make under similar circumstances.

Case 2.—Male, æt. 2 years 4 months, when I first saw him, will be three years old next month, November, 1879. The boy was pale and pasty-looking but had plenty of flesh. He was quite healthy when born, but soon developed bad eczema capitis. This eczema he has had since on different parts of the body, and has still lichenoid patches here and there, especially on the thighs. He had not walked for some time, disliking apparently even to stand. Slight bowing of the legs was to be noticed, and slight epiphysary enlargements. He was extremely fretful and constantly kept something in his mouth (usually a feeding-bottle mouth piece) against which to rub the tongue. He would also hold the latter out of the mouth to be scratched, as this seemed to give relief, to what there was every reason to believe was intense itching. When most troubled in this way the saliva dribbled in very large quantity from his mouth. This condition of the tongue was first noticed when the boy was six months old.

The family history was essentially bad. The parents were first cousins once removed. There was phthisis on both sides of the family, the father's death being in the main due to it, though the mother herself appeared fairly healthy. Her mother, however, was pronounced consumptive by medical men, though she has reached the age of about fifty-six. Phthisis is in her family besides, however.

The father of the patient had had syphilis three years before marriage or eight years before the birth of the latter. This was evidently very intractable as the prescriptions for his treatment show. There were no miscarriages, however. Seven children were born in six years; the first died of tabes mesenterica; the second, whom I saw, was very healthy; also the third, still alive; the fourth and fifth were twins, of which one was still-born; the other, anencephalous, but very healthy looking otherwise, lived for eight months; one other child had enlargement of the epiphyses too; the sixth is the patient in question, and the seventh is a baby nearly two years old, not a healthy child, but showing no trace of any ailment distinctly specific. None of these children, except patient, ever had anything the matter with the tongue. The father had on more than one occasion explained to the mother that she might possibly be infected from him, and that their children would probably show evidences of syphilis. But on very careful inquiry from the mother I cannot find any direct evidence that either she or her children had at any time shown the slightest signs of distinct specific taint. The fact that the two eldest children are robust may be given some weight here. Since the death of the father, about two years ago, the circumstances of the family have been very bad indeed, and the mother voluntarily attributed many of the ailments of her children to the want of sufficient nourishment, to say nothing of the ordinary strengthening medicines, cod-liver oil, &c.

As regards the rash itself, which has been present on and off ever since the child was six months old, the first point about it

WOODCUT 4.

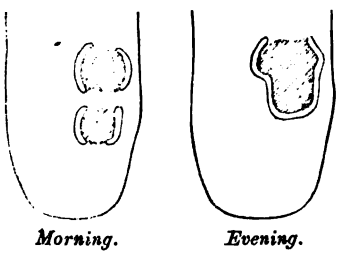

Morning. *Evening.*

Seen by Mr. Heath, March 7th.

which has struck every one who has seen it is its prevailing circular

form and resemblance to ringworm, both in appearance and mode of growth. This struck the mother, Mr. Heath (who kindly sent me Case 2), myself, and others. The bands of eruption are in almost every case either circular or form parts of circles (see Woodcut 4). They start from a single spot, of a slightly paler hue than the rest of the epithelium of the tongue. Such a spot was present yesterday when I last saw the child. This then rapidly developes into either a small ring or a crescentic band, almost forming a circle in many cases, but open at one side or other. These rings or crescents appear in every part of the dorsum of the tongue with equal frequency, but occasionally creep over its borders or tip for some distance. Though looked for on the floor and other parts of the cavity of the mouth they were never found. From their commencement they travel with varying degrees of rapidity, sometimes remaining stationary for a considerable time, but usually advancing very quickly, a small circle developing into a wide ring in the course of a few hours. Within the concave margin the surface appears somewhat livid, but not inflamed; it is simply smooth and glazed, as though denuded of its epithelium. The bands of eruption themselves are not of the same colour as the normal tongue, but a little lighter, and have a chafed, roughened surface, somewhat raised and sharply marked at the border of advance. The difference of colour, however, between the part already traversed and that not yet invaded by the disease is very marked, the livid tint of the first contrasting with the normal pale shade of the otherwise perfectly healthy tongue. Some of the spots referred to made their appearance on these smooth dark areas, already traversed by

WOODCUT 5.

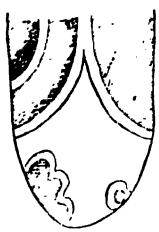

May 12*th.*

Seen by Mr. Hutchinson.

the disease, and spread over them again in rings or bands a second

time in precisely the same way as during the previous invasion (*vide* Woodcut 5). There was neither vesiculation, ulceration, or exudation, as far as one could determine with the naked eye or hand-glass; in fact, there was nothing in the appearance of the rash which suggested anything of the nature of an inflammation proper. The change, as before remarked, resembled very closely that produced on the skin by tinea tonsurans, a line of irritation with slight elevation and desquamation. Examination with an ordinary hand-glass revealed nothing further than that the epithelium had really been more or less cast off over the surface already traversed, while chafed and roughened along the border of advance. It was this appearance which led me to suspect some parasitic growth at the root of the condition, and to make a careful microscopic examination of scrapings taken from the roughened border. These were removed with the edge of a new silver spoon in the first case, and subjected to a very careful search by myself, several scrapings being taken from different spots. The only matters found were the usual epithelial cells and corpuscles of the saliva, but no parasitic growths. In Case 2 I made, if anything, a more careful examination in a private ward at University College Hospital with the help of two assistants. Here, after a short search, we found numerous cryptogamic organisms under all three microscopes. Of these I made some drawings (shown). I took the opportunity of showing these the next morning under the microscope to Mr. Hutchinson, who agreed with me at once that they were cryptogams, and exceedingly like the trichophyton tonsurans. I have placed drawings of the latter made under the same microscope side by side with those organisms from the tongue for the sake of comparison. They appeared specially abundant on one particular spot on the tongue, and yielded many microscopical slides. A very careful comparison of them with the trichophyton, with which I am quite familiar, having cultivated it on my own finger for the sake of study, showed, as far as I could judge, a perfect identity between them. But this was the only occasion on which anything of the kind was found. An equally careful search on another occasion in my own study sometime later failed to detect a trace of parasites. It is unnecessary further to describe those found, than to say that in every respect, so far as I could see under a high microscopic power, they resemble the trichophyton. As to their significance here, I am inclined to believe

that they are not in any way the cause of the disease. If they were they ought to have been found on other occasions. Again, the rash has been present in Case 2 for two and a half years, and all this time no trace of ringworm has appeared on any other part of the body, or on any other of the children. They were only present on one occasion, and then probably accidentally, as I believe such cryptogams often are in the mouths of unhealthy children.

The rash is wholly unlike "thrush." There is no trace of false membrane, the circles and bands only appearing a little chafed. Again, it does not appear on the cheeks, lips, or gums, unlike thrush, but is entirely limited to the tongue, any part of which may be invaded from root to tip, but the under surface never primarily. There were no curdy patches ever associated with it. Again, unlike the disease alluded to, it gives no pain or difficulty on sucking, but is rather relieved by this; this is due to the constant and severe itching which torments the patient while the ailment is at its height. There is constant and abundant dribbling of saliva at the same time, probably due to the same cause, and sufficient, as the mother expresses it, "to wet his clothes through." She also says that the itching was so severe lately that on one occasion the child in his annoyance threw his india-rubber mouthpiece into the fire, and got hold of the scissors "to cut his tongue out," as he said.

Next to its constant tendency to assume a circular form and intense itching, the rapidity of its advance is most remarkable. This is described by the mother as very striking. Not having the child close at hand, I am unable to speak of this from personal observation; but, for example, on occasions when I have seen the tongue in the afternoon showing large circles, I have been assured by the mother that the latter were only commencing to form that morning. The diagrams now shown give a very good idea of this, comparing afternoon and morning. The fact of its having invaded any portion of the tongue did not seem to give immunity from re-invasion almost immediately after, as may be seen from Woodcut 5.

The chief points of interest about this rash may be briefly summed up as follows:

It occurred in children before the commencement of the third year.

It was very chronic.

It tended to assume a circular form.

It was accompanied by intense itching and extreme flow of saliva.

It was wholly confined to the tongue, and chiefly its upper surface, but was found on the latter anywhere from root to tip.

It occurred in weakly children with tendency to eczematous eruptions.

Cryptogamic organisms, identical with the trichophyton tonsurans, were found on one occasion in Case 2, but were absent in the other, as also on a second and third search of Case 2.

The rash resisted local remedies, and only yielded sluggishly to constitutional treatment.

I ought to say that in Case 1, though pathologically identical with the other, the family history was good; the child lived under very healthy conditions, and had every care that wealth could provide and intelligence suggest.

I have expressed a belief that such an affection of the tongue has not been described in this country hitherto, and I think I am correct in this. In Mr. Fairlie Clarke's work on the tongue he alludes in a few lines to a communication (apparently verbal) made to him by Sir J. Paget regarding a case of ring-worm of the tongue. The allusion is so brief that it is impossible to be certain whether this was a case of the same affection; it appears probable, although it occurred in an adult, that Sir J. Paget believed it to be true tinea circinata.

Mr. Hutchinson has kindly told me that since he saw Case 2 he had an opportunity of speaking with some French surgeons on the point, and learned that an apparently similar condition had recently been described and figured in France. I regret that the reference which he kindly gave me was not accessible to me. It was there called "lichenoid of the tongue," a name which would appear to me very inappropriate for the disease now before us. If parasitic, plainly so; but even if not, the circular band-like form and rapidity of production in the other characters described, would show it to be something quite different. If a name must be found for it, I would venture to suggest, in view of the little that we know about it as yet, some one which would involve no theory as to its causation or nature, such as *Circulus* or *Annulus migrans*, or simply *Prurigo linguæ*.

As to its real nature, it would be premature to hazard a decided opinion; but from what I have seen of the rash I should feel inclined to regard it as more likely to be the result of reflex nerve-irritation than anything else.

I may add that the French Dictionary of Medicine, since the beginning of the century, contains no reference to anything of the kind; neither does Canstatt's Jahresbericht since its commencement twenty-four years ago, or any of the standard English works of reference, all of which I have carefully consulted. For this reason I should feel obliged to any member who could throw any light on the matter, for the disease appears to me sufficiently remarkable, having caused much very real discomfort to the patients and a good deal of anxiety to the parents as regards prognosis.

Since writing the above I have seen the patient to-day (November 18th, 1879), and have made a very careful examination of the tongue at my leisure. There is now hardly the slightest evidence that the tongue had ever been the seat of any disease except a slight trace of pitting, which was only quite certain on very close inspection, and which would not be recognised, probably, by one who had not seen the disease before. At one spot there was a suspicion of a semi-lunar mark. Four days ago, the mother tells me, it was at its very worst; it had hardly ever been so bad, the tongue being covered with the characteristic patches. During the development of these he had suffered much. The lichenous rash on his limbs, however, was quite gone, probably as the effect of arsenic, which I had given him for about a month. This fact seems to point to some difference in the etiology of the tongue-rash and that on the limbs; for while the latter had quite disappeared from the arsenical treatment, that on the tongue was at its worst. I made two deep scrapings of the tongue, and have just finished examining them very carefully with the microscope. With the exception of one or two bodies, doubtfully like spores, there is nothing in the mucus and epithelium which I should regard as abnormal. Great rounded masses, apparently of aggregated micrococci, would hardly be taken as such. *Nov.* 18*th*, 1879.

Note.—June 11th, 1880. Since this paper was read I have had a courteous letter from Dr. Gunn (Senior House Surgeon at Moorfields Ophthalmic Hospital), enclosing me some notes and drawings of the case to which Mr. Hutchinson alluded in the discussion arising on it. I have no doubt that this case, seen a little before

my own first, was quite identical with the latter as far as observed. It may also be added that, since the discussion on this paper, an article upon the same subject has been published by M. Vanlair in the 'Rév. Mens. de Méd. et de Chir.,' January 10th, 1880, entitled "Lichénoide Lingual." This author, in his observation of three cases, has come to the same conclusion as myself as to the *non-parasitic* origin of the affection, though he mentions the same rounded masses which I have alluded to as probably aggregations of micrococci. His description will be found full and accurate. He gives the reference to the short article I was also directed to but could not find. It is one by Gubler in the 'Dict. Encylop. des Sciences Méd.,' t. X, 1re partie, p. 234. This very brief notice now before me, in which Gubler speaks of the affection under "the provisional denomination of lichenoid of the tongue," is apparently the first ever published on the subject. I find that his description corresponds almost exactly with mine; but, in spite of negative results in his own case, he seems to suspect the cause of the disease to be the presence of some parasite.

November 18*th*, 1879.

---

2. *Enlargement of the temporal and masseter muscles on both sides.*

By J. Wickham Legg.

Lousia E—, aged 10, was admitted into Mary Ward, of St. Bartholomew's Hospital, under my care, on February 14th, 1880. For the following notes I am indebted to Mr. W. Payne, the clinical clerk.

Mother's account.—Three weeks ago the child began to feel faint and sick, and vomited, but her appetite continued good.

Shortly afterwards, the mother noticed a swellings at the angles of her jaw, which afterwards extended to her temples. She did not notice the temples before, but was probably prevented doing so by the girl wearing a fringe. She says that the swellings at the angles of the jaw have subsided considerably, which they have done before, but have recurred again.

She also states that the girl's appetite for some time has been ravenous, combined with great thirst.

The girl has not been getting thinner; often suffers from a frontal headache.

Mother states the swelling came on suddenly.

Previous history.—Child had whooping cough, scarlatina, and measles before she was two years old, and has always been a delicate child. Five years ago she had abscesses under her jaw and in both axillæ. Twelve months ago she felt sick, but at the same time was hungry and vomited a worm (like an earthworm) through her mouth. Attended as an out-patient for it at St. Bartholomew's Hospital.

Family history.—Has a sister two years older than herself, who is healthier, and a brother two years younger who is now healthy; they both have had whooping cough and scarlatina; the boy also had "consumption of the bowels" a year ago, and was admitted into Mark Ward. These children were seen and no enlargement of the calves was noticed in them. The mother has had two miscarriages. The mother had four brothers and four sisters, four of whom are dead (died in fits). The mother knew of no disease among them like Duchenne's disease.

Present state.—A well-nourished child with light brown hair and blue eyes, with rather a dry skin, though of natural temperature. Eyes, nose, and mouth normal. There is a little spot on corner of mouth, but it is not herpetic. Some of the milk teeth still remaining, but the permanent incisors are of peculiar shape, resembling mother's, and also the mother's sisters. Tongue clean. Fauces normal.

There are tumours at angles of jaw and on temples; also a scar extending round nearly the whole length of the jaw-bone from angle to angle. The cervical glands are enlarged, especially on the left side. There is a scar over the left clavicle of an inch from its angle.

Both angles of the jaw seem to be especially prominent, there seeming to be a distinct bony enlargement corresponding to the insertion of the masseter; these tumours were also thrown into greater prominence by a scar running along the line of the jaw, commencing on each side at the point where the insertion of the masseter ceases in front; the depression of the scar making the masseter have a more definite outline.

The actual measurement from one bony point to another, of the distance between the angles of the jaw, being taken under the chin, is four inches, whilst the measurement antero-posteriorly, *i. e.* from the line between the angles to the symphysis, is only 2⅝ inches.

When acted on by the induced current from a magneto-electrical machine these muscles contracted, causing the jaw to move up. They did not contract with galvanism, but only a weak current was used.

No other muscles in the body seemed to be abnormally large; the calves swelled out perhaps rather suddenly below the knees, but did not appear large.

Measurements: circumference, 8¾ inches, taken 3 inches below the patella; whilst 3½ inches below patella they were 9⅛.

Description of tumours.—Temples.—On each temple there is a tumour of ill-defined outline rising more suddenly in front but gradually subsiding towards the back, the one on the left side being rather more marked than that on the right. It extends upwards as far as the temporal ridge, backwards to the distance of an inch behind the auricle, downwards it would seem to be bounded by the zygoma.

To the feel they are both firm, giving no trace of fluctuation; they also move. When she sets her teeth they become hard and rise up. The width of the skull in the line of the auricles, however, appears broad, though the tumour on each side projects considerably beyond the external angular process of the frontal bone.

There is also a tumour at each angle of the jaw, that on the left side being, perhaps, slightly more marked. They possess the same characters as those on the temples, giving no sense of fluctuation, and becoming hard when she shuts her jaw.

They extend upwards to the zygoma, being conterminous with the tumours on the temples; below they are bounded by the jaw-bone.

The muscles of the jaw, when tested as to strength by biting a pen-holder, appeared to have rather more power than usual.

There was no weakness of any other muscle. The child could readily kneel down and get up, sit down on a low stool and get up, climb up on the bed, and run upstairs. In fact, she showed rather more activity and agility than is common at her age. Temp. 98°·3; pulse 100, soft and regular.

Chest well shaped, and heart and lungs in every way normal.

Liver dulness extends upwards to the fourth rib.

Abdomen in every way normal.

Urine rather high coloured, sp. gr. 1035, clear; no abnormal contents.

Bowels were opened five times yesterday, but it is the first time she has had diarrhœa.

Says she sleeps well.

February 18th.—Feels well, no thirst or abnormally large appetite. Pulse 104, regular. Tongue clean. Slept well.

20th.—Complains of a little frontal headache; says herself that she slept well, but was noticed to be restless, and to talk in her sleep. Tongue clean. Bowels open. Pulse 100.

24th.—Headache still continues, otherwise well.

Just before she was discharged, the tumours on the temples appeared to have acquired a darker hue (dusky blue), and some veins could be seen. She does not complain of any pain in them. The tumours appeared to grow a little, and to have become more symmetrical, *i.e.* both sides the same.

March 10th, 1880. — Discharged; to attend as an out-patient.

There might be some doubt whether the tumours in this patient were wholly muscular, or caused partly by the protrusion of the bone underneath. The prominence of the bony ridge around the temporal fossa and of the mental spines might be pointed to as evidence of this; but it seems somewhat improbable that the protrusion of the skull should be so exactly symmetrical, and accompanied by such marked hypertrophy of the masseter muscles. The temporal muscles, also, as they contracted under the finger, gave a sensation as if they filled up the fossa, and were in no way aided by bone.

If, then, it be granted that the tumours were muscular, to what disease known to us can they be referred? The hypothesis of the mother, that the disease was caused by the enormous appetite of the child, may be set aside in view of the fact that the child, as observed in the hospital, showed no such large appetite, but rather a small one. The disease to which this enlargement of the muscles shows most affinity is certainly the pseudo-hypertrophous paralysis described by Duchenne. Instances of the enlargement of the temporal and masseter muscles in this disease have been spoken of

both by Duchenne himself[1] and by Dr. Gowers.[2] But it would seem to be in all an appearance which comes on late in the disease, and I am not acquainted with any case in which enlargement of the temporals and masseters has been noticed first of all. In this case there was certainly no weakness of other muscles; the child could run, climb, go upstairs, kneel down and get up, sit on a low stool and get up without any trouble; and there was no enlargement of the muscles of the calf or about the shoulder in my own opinion, though by some it was thought that the gastrocnemii were enlarged, by others that the deltoids, by a third set that the infraspinati were enlarged. But there was no agreement amongst them; those, for instance, who thought that the deltoids were enlarged refused to allow that the calves were big, and so on. Further, there was no weakness in the enlarged muscles, for the child could make with her teeth a deep impression on a wooden pen holder. The muscles also acted well to the faradic current, though Dr. Gowers tells us that in Duchenne's disease the irritability to faradisation is usually lowered.[3] Under these circumstances, then, I feel disposed to refuse the name of Duchenne's disease to this case, although it must be owned that it has been but a short time under observation, and that it is possible that, later on, an increase in size in other muscles in the leg or about the shoulder may be noted. Also against the idea that the disease is Duchenne's paralysis, is the sex of the child and the want of hereditary transmission. I saw the brother and sister of the patient, and there was certainly no enlargement or weakness of their calves. The mother knew nothing of any trouble in walking or weakness in getting upstairs among her own brothers and sisters.

My friend, Dr. Champneys, tells me of a case, not unlike this, which he saw but once. A woman, aged somewhat over twenty, had enlarged temporal and masseter muscles on both sides, but without enlargements elsewhere. She attended but once at the hospital, and was not seen again.

The way in which Duchenne's paralysis is transmitted in families is noteworthy. It attacks the boys, but leaves the girls free, who, when they attain maturity, transmit the disease to their sons, their

[1] 'Duchenne, 'De l'électrisation localisée,' Paris, 1872, 3e éd., p. 608.

[2] W. R. Gowers, 'Pseudo-hypertrophic Muscular Paralysis,' London, 1879, pp. 11 and 29.

[3] W. R. Gowers, op. cit., p. 30.

daughters again carrying on the disease. The same method of propagation is seen in hæmophilia, and when first described it was thought peculiar to this highly hereditary disease. But this way of transmission has been seen not only in hæmophilia and Duchenne's disease, but in several other disorders, more or less severe. Thus, in some of Dr. Gee's cases of hereditary polydipsia or diabetes insipidus, the mothers, unaffected, gave the disease to their sons.[1] I have myself seen the like in gout, and I have heard of a case of colour blindness in a man who filled some diplomatic post in the time of the Georges, and to whom his infirmity was revealed by his neglect to appreciate a certain part of a despatch written in red ink. In this man's family the colour blindness has descended through the women, whom it has left untouched, to their sons, who suffer. It is possible that the diseases in which this trait prevails may hereafter become much more numerous than is at present known.

March 2nd, 1880.

The child has been attending regularly up to the present date (July 3rd), with very little change. If anything, the muscles are somewhat smaller.

---

3. *On some appearances, probably of parasites, in the voluntary muscles in cases of enteric fever.*

By George Buchanan, M.D.

In a recent investigation of a febrile disease prevalent on the training ship "Cornwall," my colleague, Mr. Power, finding difficulties in the identification of the disease with any of the ordinary continued fevers of this country, had occasion to exhume, for the purpose of *post-mortem* examination, the body of the only boy who had died of the prevailing complaint. The exhumation was not until two months—months of very cold weather—had elapsed after the boy's death. At the autopsy, enteric fever, which with peritonitis had seemed to be the cause of death in this particular case, was first disproved. The inquiry was then extended with the object

[1] Samuel Gee, 'St. Bartholomew's Hospital Reports,' 1877, vol. xiii, p. 80.

of discovering what the disease could be that had thus strangely simulated that fever; and presently the abundant presence of nematoid parasites in the voluntary muscles led to the diagnosis of trichiniasis as the cause of death. Without going into the story of the total outbreak, it would be impossible to give here the evidence upon which it came to be believed that all the cases were of the same nature; but it will be enough for present purposes to say that there was a presumption amounting pretty nearly to certainty that this was so. The parasites found in the fatal case were of about the usual dimensions of trichinæ, but there were two kinds of differences between them and the parasites that are observed in ordinary cases recognised as trichiniasis; first, they were not encysted; secondly, they were more watery and transparent than the common non-encysted trichinæ. These differences, however, were very probably the result of the exceptional circumstances under which they were found; death at a very early period of the disease; burial for two months before the time of this being found in the muscles. On the whole, it was judged there was very good reason for considering them as identical with trichinæ; but the reservation was made that, supposing they were not absolutely identical with *Trichina spiralis*, they were so plainly allied in their characters to that parasite, that their presence in the body of a boy dying of a febrile disease not readily distinguishable from enteric fever, would come to have a new sort of significance, and the fact might indeed prove to be of concern to the pathology of enteric fever itself.

With this experience from the "Cornwall" inquiry, therefore, it seemed to Mr. Power desirable to make a fresh examination of the voluntary muscles of enteric fever; and he has begun to make some observations in this direction. It is my object in this communication to state what has hitherto resulted from these observations, made, it is true, upon two cases only of the disease, but made with a sufficiently new and sufficiently demonstrable result, and with a sufficient similarity of result between the two cases to give a very considerable interest to the observations, and to make extremely desirable the investigation of other like cases. We have therefore regarded the subject as worthy of the many pathological workers that this Society numbers among its members, and without professing to do more than record the observed facts, I propose to describe Mr. Power's observations, which are illustrated by the specimens and drawings shown to-night.

Mr. Power's first note is dated April 2nd, and is as follows

"A young man was admitted into St. Thomas's Hospital on the 15th of March, suffering under well-marked enteric fever, that was at once recognised to be such. He died on the 30th of March, about the twenty-third day of his illness; the immediate cause of death being peritonitis. I was present at the *post-mortem* examination on Wednesday, March 31st, by the favour of Drs. Reid and Cory, of St. Thomas's. It appeared that perforation of the bowel had occurred at one enteric ulcer of the ileum, and that fœcal matter had escaped into the peritoneal cavity. There were numerous other ulcers of the same portion of bowel, all of them typical of enteric fever. Certain viscera and tissues were taken for microscopical examination, and this is now in progress.

"I think it right at once to acquaint you with the early observations I have made on the muscular tissues of this case. In the pectoral muscle I find what I take to be parasitic 'worms' of some sort. After search with a lower power, their characters were pretty clearly to be made out under a 'twelfth' (Gundlach's). One or more of them was to be seen in most specimens (a few fibres only in each instance) of the pectoral muscle examined. Apparently they were living when found. Certainly one of them appeared to advance and retract an extremity while under observation, his body becoming during the process alternately thinner and more thick. Another, which when first seen had one extremity partially buried in muscle, had in the course of half an hour so far pierced the muscle as to bring the obscured extremity fully into view. The dimensions of the parasite were wholly different from those of *Trichina spiralis*, or from anything figured in my report. In length and in breadth the present parasite appears to average something like one fourth of the average trichina as seen in muscular tissue before encapsulation. In breadth they are largest in the middle, and have one end more slender than the other. So far as I have yet made out, they have a resemblance to nematoid worms both in the proportion of their breadth to length and in the presence of an interior canal, which looks as if interrupted by some overlying internal tissue or organ; but as to these points I do not profess that my microscopical observation is anywise complete. Dr. Cory has been so good as to draw several of the creatures, with such details as we have yet made out."

Since the above date (April 2nd) observations have been continued

on the muscles of the St. Thomas's case, and have been extended to samples of muscle, obtained through the kindness of Dr. Curnow, from a boy who died of enteric fever in the Seamen's Hospital. The boy had been ill only eleven days and the immediate cause of death was peritonitis resulting from perforation of the bowel. The ulcer at which the perforation had taken place was a well-marked enteric fever ulcer, one of several existing at the lower end of the ileum. On April 17th Mr. Power reports, in continuation of his previous note, and adding his observations on the muscles of this second case:

"In the St. Thomas's case I have continued to find trichina-like bodies of the sort already reported to you.

"I have also found similar bodies in portions of muscle from a boy who died in Greenwich Hospital from peritonitis at an early stage of unquestionable enteric fever. In neither case (St. Thomas nor Greenwich) do the seeming parasites now appear so plentiful as they had looked to be in the earlier specimens examined from the St. Thomas's case. Further, and the following notes apply to both cases, the parasites have not been found in all the muscles examined. None have been found in the diaphragm. In the great pectoral and psoas muscles, to which most attention has been given, they are by no means uniformly distributed through the muscular tissue. Not unfrequently, more than one of the seeming parasites may be found in a microscope-sample of muscle, but more often several slides may be examined without finding any. On the other hand, certain much smaller bodies, having possible relation to the larger bodies that I speak of as being like parasites, are much more numerous, and they as well as the larger bodies are figured in the accompanying drawings. These smaller bodies are with difficulty distinguished amid the muscle in which they are found, and very slight interference with the slide (made with the object of bringing them more fully into view) often results in their being lost sight of altogether. I should mention that as decomposition of a portion of muscle has advanced, the larger parasite-like bodies have been found in that portion in greater abundance than before. But I am not prepared to say whether this greater abundance is apparent only or whether it results from actual growth or multiplication. With advancing decomposition of the muscles the minuter bodies to which I have referred are not more readily found. As regards movement of the seeming parasites I have not been able to get further indications than those mentioned in my previous note."

[The various drawings here mentioned, and specimens from the St. Thomas's and Greenwich cases, were shown in illustration.]

April 20th. 1880.

---

4. *Congenital talipes varus.*

By Robert William Parker.

The specimen was removed from an anencephalous fœtus, which died at its birth. I am indebted for it to my friend Dr. Wilson.

The condition of varus was well marked, although not extreme. The whole foot appeared very much foreshortened, the ball of the great toe being raised upwards and inwards, and drawn backwards towards the leg.

After removing the skin and the subcutaneous fat, which was very thick, the limb presented the following features:—The tibia was normal as to position, but the fibula was placed immediately behind it, instead of on its outer side. The outer malleolus, therefore, was not visible from the front. The os calcis was drawn a little upwards and inwards (supinated), so that the insertion of the tendo Achillis could be seen from the front.

Viewed from the front, the inner edge of the gastrocnemius muscle is seen to overlap the subcutaneous surface of the tibia in its upper half; this is in consequence of the rotation outwards and backwards of the fibula already referred to. There is no shortening of the tendo Achillis; the posterior tibial tendon appears short, and it was put on the stretch when any attempt to straighten the foot was made. The tendon of the anterior tibial muscle was even more shortened than the posterior, as was also the extensor proprius pollicis; both these muscles were rendered tense in attempting to overcome the deformity. The abductor pollicis was also much shortened.

By rotating the fibula forwards and forcibly extending the foot the deformity was in some measure overcome; but complete extension of the foot was prevented by the tendon of the anterior tibial muscle. The altered condition of the os calcis did not appear to be remedied by this extension, though it was partially rectified.

After the deformity had been partially overcome in the manner described, the muscles on the back of the leg all appeared flaccid, and longer than was necessary.

Congenital talipes calcaneus.

The specimen was removed from a fœtus, born at term, which presented no other malformation, and which died immediately after its birth. I am indebted for the specimen to my friends Dr. Herman and Dr. Barlow.

The condition is one of complete talipes calcaneus, the dorsum of the foot being in contact with the anterior surface of the leg.

After dissecting away the skin and subcutaneous fat the muscles were found to be normal in position and number; but those on the anterior surface of the limb—tibialis anticus, extensor proprius pollicis, and the extensor longus digitorum—were all obviously too short; and any attempt to rectify the position of the foot rendered these muscles quite tense. There was no lateral deviation of any kind. The muscles on the opposite surface of the limb were normal in appearance; the tendo Achillis presented no pathological condition; it became flaccid and loose when the position of the foot was altered.

Remarks.—These specimens are interesting as a contribution to the pathology of congenital talipes at the time of birth. I find no difference in appearance or consistence in any of the muscles; those on the extensor surface appear just as well developed as their opponents do on the flexor surface.

Various views have been expressed as to the causation of such deformities. I venture to think that these two specimens show how malposition *in utero* is probably the real predisposing cause of the congenital forms of the disease.

There is abundant evidence to show that the deformity occurs at a very early period of intra-uterine life—at a time, therefore, when the muscles are not sufficiently differentiated to be capable of contraction, in the sense of the word as applied to them in later life, and when, for the same reason, it is difficult to imagine that the nerve centres have that intimate relation with the function of these muscles which they acquire later on.

On the other hand, given a faulty position of a limb, the result of

a jolt or a fall or a blow sustained by the mother, or of some irregular muscular contraction of the uterus, and we have all that is necessary to bring about this deformity. For it appears reasonable that if, in consequence of some malposition of a limb, the two points of attachment of a muscle be abnormally approximated to each other during fœtal growth, the intervening muscle will, as a consequence, be shorter than under other circumstances; while, for an opposite reason, the opposing muscles will be lengthened.

I venture to think that clinical evidence bears out this supposition; for of all talipes the congenital forms are the most amenable to treatment. On the other hand, those forms, the paralytic, which result from a known nerve-lesion, carry their impress throughout life.

I do not think that a primary nerve-lesion is indicated as the probable cause of the congenital form, from the fact they are frequently *associated* with spina bifida and malformation of the brain; for I have seen many such cases accompanied by talipes of *one foot only*. On the other hand, a large proportion of the cases occur in children who not only have no malformation of the nerve-centres, but who are types of healthy development except as regards the foot or feet. *May 4th*, 1880.

---

5. *An Achilles tendon, which had reunited, with the formation of one and a half inch of new tendon, after subcutaneous division four years previous to death.*

By William Adams.

The specimen consisted of a large portion of the gastrocnemius muscle, with the Achilles tendon and a portion of the os calcis attached. The Achilles tendon had been divided subcutaneously by Mr. Adams on the 10th February, 1869; and the patient, a young gentleman, Master E—, then aged 10, died from subacute pneumonia four years afterwards, on the 19th March, 1873, æt. 14. He had been

the subject of pseudo-hypertrophic muscular paralysis, and his case, together with the *post-mortem* examination and the description of the microscopical appearances observed in the brain and spinal cord, is fully reported in the 'Trans. Royal Med. and Chir. Soc.,' vol. lvii, 1874, p. 247, in a paper by the late Dr. Lockhart Clarke, and Dr. W. R. Gowers.

The Achilles tendon exhibited showed the reparative process to have been extremely perfect, and between the divided extremities of the old tendon, which were very distinctly traceable, an inch and a half of new connecting tissue, or new tendon, had been formed, equal in diameter and thickness to the tendon, which it served to connect. Its external surface was smooth, and an examination externally would not detect any evidence of the operation; but in a longitudinal section, the new regenerated tendon structure was seen to differ from the old tendon, by the absence of the longitudinal arrangement of its fibres, and the opaque, pearly lustre, characteristic of old tendon. The new tendon structure presented a greyish translucency, with an irregular distribution of its fibrous element. At the line of junction between the old and new tendon, the process of dove-tailing was distinctly visible, the greyish translucent new tendon passing between the separated fibres of the old tendon.

The appearances were precisely similar to those observed in other specimens described by Mr. Adams in the earlier volumes of the 'Transactions' of this Society[1], but no specimen so late as four years after operation has been described.

It is worthy of remark that in the present case the deformity, viz. talipes equinus, for which the tendon had been divided, had returned before the death of the patient, and it is proved by the specimen that the recontraction, and consequent relapse of the deformity, was consequent upon changes taking place in the structure of the muscles of the calf, and not at the expense of the new tendinous structure, which we can hardly suppose to have been more than one and a half inches in length at any time.

The particular form of paralysis from which this patient suffered was first brought before this Society by the late Dr. Lockhart Clarke (on the 19th November, 1867) see 'Trans.,' vol. xix, 1868. Dr. L. Clarke then read a communication from Dr. Duchenne, of

[1] See 'Trans.,' vol. vi, 1855, and other vols.

Boulogne, who was one of the earliest observers of the disease; and at the next meeting (3rd December, 1867) Mr. Adams exhibited a boy, æt. 7½, suffering from this disease and then under treatment at the Orthopædic Hospital. *May 4th*, 1880.

---

6. *Sequel to a case of syphilitic gummata recorded in the 'Transactions' of the Society (vol. xx, p. 309).*

By Wm. Adams.

A considerable number of yellow fibrinous masses, which had formed subcutaneous tumours, chiefly in one leg below knee but also in the thigh, were exhibited to the Society on 2nd January, 1869; these had been removed during the sloughy and ulcerative process which they set up (see 'Trans. Path. Soc.,' vol. xx, 1869).

The patient, a lady, lived seven years after this date, and died on the 12th July, 1876, aged thirty-eight, having suffered from syphilitic sequelæ for about eighteen years. It could not be ascertained that she had ever suffered from primary syphilis, and she confidently stated that she had never been pregnant, but she was married at the age of nineteen years, and her husband admitted to Mr. Adams that he had suffered from syphilis six months previously. A few months after their marriage her husband suffered from a cutaneous eruption in a mild form, and about a year later also from deep ulcerations in one leg. Under a course of treatment by the late Mr. Startin he was supposed to be cured, but the cutaneous eruption occasionally reappeared.

About six or seven months after her marriage the wife began to suffer from deep ulcerations in one leg below knee, and also from a syphilitic affection of the knee, elbow, and ankle-joints, described in the early report of the case. It was for this affection of the knee-joint that she first came under Mr. Adams' care. She had never had a miscarriage, and her monthly periods had never been interrupted. In consequence of the anxiety both of her husband and herself to have a family, this lady became a patient of Dr. Oldham's two or three years after her marriage, and underwent

a course of local treatment of the os uteri. In what way the wife became infected in this case seems, therefore, difficult to explain, unless by the seminal fluid independently of impregnation. An abraded surface in the vagina would under the circumstances probably exist, but as the primary sore on the husband had healed some months before marriage and the surgeon had given him permission to marry, it is very improbable that any syphilitic sore existed at the time of marriage.

About three years before her death gummatous ulcerations began to form in the tonsils, then in the soft palate and pharynx, masses of yellow fibrinous deposit always existing at the base of the ulcerations. The larynx at last became involved, and from the urgency of the symptoms it was agreed at a consultation with Dr. Morrel Mackenzie, in June, 1874, that tracheotomy should be performed; and this was performed by Dr. Mackenzie with Mr. Adams' assistance on the 12th August, 1874. Dr. Brodie Sewell was also in constant attendance, and sometimes Dr. Crosby.

All the distress from the difficulty of breathing was relieved, and the health improved. With the aid of the valve and pea in the tube she could talk distinctly, and even sing a little. The tube was worn for a twelvemonth, and the general health remained good, though during this time gummatous formations continued to occur in the leg.

The patient wished to leave town, and became extremely anxious to have the tube permanently removed, to which Dr. M. Mackenzie saw no objection, and at a consultation on the 5th July, 1875, the tube was removed. On the 10th of July Dr. Mackenzie again saw her in consultation, and there seemed to be no reason to apprehend any danger. The patient, however, became nervously anxious and depressed, not sleeping well, though she did not express the dread, which we afterwards learned she had, of the closure of the aperture, nor did she express any wish for the re-introduction of the tube. On the 12th July Mr. Adams saw her between 5 and 6 o'clock in the afternoon, when she complained only of feeling week and depressed, and he administered a glass of port wine. About 7 p.m. she observed a blueness about her nails and the tips of her fingers, and exclaimed that her time had come; some difficulty in breathing came on and rapidly increased, when she made a rush to the window for air. Mr. Adams, who had been sent for, arrived at this time, and immediately re-introduced the tube without any

difficulty; air passed freely into and out of the chest, but she gradually sank, and died at 8.15 p.m. No *post-mortem* examination was made.

This patient was remarkably susceptible to the influence both of mercury and iodide of potassium. Mercury in any form, and in very small doses, rapidly produced salivation; and even black-wash when applied externally would begin to produce salivation in three or four days, though it was always useful in allaying pain and inflammation when periostitis of the tibia occurred, or of the articular extremities of the femur or humerus, when the knee and elbow-joints became involved. The mercurial vapour bath was useful, but only for a short time. Iodide of potassium, when given even in the dose of one sixth of a grain, gave rise to distressing nervous symptoms, extreme depression, confusion of intellect, and disposition to hysteria. Iodide of ammonium was borne better than any other drug and was decidedly useful, though not in permanently arresting the progress of the disease and its fatal termination.

May 4th, 1880.

---

7. *Two cases of late hereditary syphilis.*

By Sidney Coupland, M. D.

Case 1.—Emma F—, æt. 13, admitted into the Middlesex Hospital, under the care of Dr. Greenhow, on Sept. 22nd, 1877, and re-admitted Dec. 6th, 1877, suffering from renal dropsy of ten months' duration. She was a stunted, unhealthy-looking girl, with pale, puffy face, slightly depressed bridge of nose, some adhesions of irides, and partial opacity of left cornea, whilst the upper incisor teeth were notched. The albuminuria was very marked, but a notable feature about the case was the existence of a firm but irregular enlargement of the right lobe of the liver. This was inferred to be syphilitic from the condition of the patient and the history of the case. She was the seventh child of a family of twelve (including three still-born), four of whom died in infancy, after having shown the usual signs of congenital syphilis. She herself

had had "snuffles" in infancy and ozæna for the past three years, and all her life had been constantly attending at a hospital.

On her re-admission the dropsy had much increased, and she died from the renal disease on December 11th, 1877.

At the *post-mortem* examination there was double recent pleurisy In the abdomen were two pints of ascitic fluid. The spleen was large, weighing 9½ oz., was indurated and smooth on section, but not lardaceous. The kidneys were swollen, large, and mottled, the cortical layer being unduly friable, of a creamy, brownish tint. The liver adhered firmly to the diaphragm; it was greatly deformed, a deep sulcus passing from behind forwards, outwards and to the right on its upper surface, ending in a wide fissure in front. This marked the seat of a large, undoubted gummatous growth, opaque, pale yellow, and firm, with irregular outline and puckered surface of thickened capsule. The growth involved the right border of the organ. Some smaller tuberculated masses also occurred in the upper surface of each lobe, close to the falciform ligament. The inferior surface of the organ was traversed in many directions by deep fissures.

Case 2.—Kate C—, æt. 18, but very ill-developed, admitted under the care of Mr. Lawson, on April 15th, 1879, having been in the hospital some months before with necrosis and exfoliation of the frontal bone and periostitis of both tibia. Prior to her discharge in February the ulcer on forehead had healed, but three weeks after that date she began to suffer from shooting pains in the right knee, and a swelling appeared over the tibia. She was one of thirteen children of whom seven were dead, the other survivors being in fair health. Her mother had also had two miscarriages.

On admission there was a deep, puckered, circular scar on the forehead. Over the outer tuberosity of the right tibia there was a soft, elastic, and painful swelling, extending over the knee-joint. The left tibia in its lower third was uniformly thickened, whilst on the right leg there was a small inflamed ulcer. There was slight œdema about the ankles. The left upper central incisor was characteristically notched, but its fellow was well formed.

There was albuminuria and gradually increasing dropsy; death occurred from uræmia on November 16th.

At the *post-mortem* examination there was well-marked general dropsy, and also cellulitis of the right leg in connection with a sinus leading to a portion of necrosed bone on the lower third of the tibia.

This bone was removed entirely. It presented over various parts of its shaft beneath the periosteum numerous and rather extensive areas of yellowish soft material (gummatous), one of which, about the junction of the middle and lower third, had suppurated, exposing some carious bone. Wherever the deposit occurred the bone was rough and nodular; but there was no general sclerosis.

There were gummata in other parts, one in the left upper eyelid the size of a French bean, and two in connection with the cranium, which were exposed on reflection of the scalp as rather soft, rounded swellings, of the diameter of a shilling, seated beneath the pericranium, which firmly adhered to them. They had a pale brownish colour, and were seated, one (the smaller) on the frontal bone, half an inch to the left of the middle line, and one inch in front of the coronal suture; the other on the left parietal, near the lower end of the coronal suture. There was also an area of necrosis, the size of a crown piece, on the frontal bone to the right of the middle line, over which an oval-shaped ulcer occurred. The dura mater was slightly adherent to the calvaria in the frontal region opposite to the seat of necrosis, where the inner table was wanting, over a triangular space measuring half an inch in each direction, and exposing the softened diplöe infiltrated with pus. The gummata on the surface extended through the outer table of the skull, but did not present on the inner surface. The pia mater was natural; no obvious thickening of arterioles; no thrombosis. Brain natural.

The heart and lungs were natural.

The liver, which weighed fifty-five ounces, was firmly adherent to the diaphragm. It was curiously mis-shapen, so that its left lobe was as large as the right. It was not lardaceous, but slightly cirrhotic and fatty. In places the capsule was unduly thick and puckered, with a small caseous nodule embedded in it at one part.

The spleen was much enlarged, weighing thirteen ounces; firm, and glistening on section, but not lardaceous.

The kidneys were both of them swollen, the cortical portions being the seat of epithelial change; their consistency soft; colour, a pale fawn tint.

Besides the marked and deep notching of the left upper central incisor, the right lower first molar tooth was dome-shaped and carious.

There can be no doubt that in this case the disease was con-

genital and not acquired, for, in addition to the condition of teeth, it was stated that the mother had suffered from syphilis before the birth of the patient. The child herself showed apparently no symptoms of the disease in infancy nor in early childhood, but about the age of fourteen years she began to suffer from a swelling on the right knee. From September to November, 1877, she was in the Middlesex Hospital, under the care of Dr. Cayley, suffering then from "massive nodes" in connection with each radius at its upper part, as well as the affection of tibia, which was then not very far advanced. It was at this time that the cranial nodes began to appear.

Although I believe I am correct in stating that cases of latent hereditary syphilis, with marked visceral lesions, have not been numerously recorded, yet I suppose no one, now-a-days, would venture to doubt their occurrence, as, I believe, did Bärensprung when Lancereaux first drew attention to them. Every case, of course, presents the twofold difficulty of obtaining a clear history of congenital taint, and of excluding any possibility of acquired disease. Indeed, it is almost impossible to be certain of the latter, and some might even argue that syphilis could be both inherited and acquired in the same subject; but, on the former head, we have, thanks largely to Mr. Hutchinson, certain pathognomonic signs of inherited taint in dental and corneal lesions.

In both the foregoing cases the family history bore strongly in favour of hereditary disease. The large infantile mortality in both families, with the presence of syphilitic signs in some of these children, the notching of the incisors in both cases, and the keratitis in one, are all strong points. It is interesting to note the unsymmetrical notching of an incisor in one case, and the unsymmetrical keratitis in the other. In neither case was there any evidence at all of acquired disease, although neither had presented any definite syphilitic signs in infancy. One of the patients was, however, remarkably ill-developed and stunted.

In 1874 Professor Laschkewitch, of Charkow, recorded ('Vierteljahrsschrift für Dermat. ü. Syph.') two cases of "syphilis hereditaria tarda," one in a girl of twenty-two, the other a lad of fourteen, both of stunted growth, and one only with evidence of syphilitic taint on the side of a parent. Neither of them showed any evidence of having acquired syphilis; both died from nephritis, and presented marked syphilitic changes in the liver, as well as lardaceous disease of the spleen and kidneys.

A feature common to all these cases, and I may add to most cases of advanced syphilis, is death from parenchymatous nephritis, which in the two cases I have above given was quite independent of lardaceous disease.

As to bone disease in hereditary syphilis, of which the second case is so striking an example, I have for some years past had under observation a child, now eight years of age, who presents massive nodes on several bones, especially the radii and tibia. Other similar cases have recently been shown before this Society; and I recal the case of a youth, aged eighteen, brought before the Society in 1872 by Dr. Robert Liveing, where there was marked necrosis of the skull and advanced lardaceous disease, attributed to hereditary syphilis. *January 20th*, 1880.

---

8. *Micro-photographs of the blood in yellow fever.*

By W. Squire, M.D.

Dr. Squire exhibited micro-photographs of the blood in yellow fever, by Dr. G. M. Sternberg, of the United States Army. "In July and August of last year, at Havana, ninety-eight specimens of blood from forty-one undoubted cases of yellow fever were carefully studied, and 105 photographic negatives were made, mostly with a magnifying power of 1450 diameters. This was obtained by the use of Zeiss's one eighteenth inch (oil immersion) objective, and Tolles' amplifier. If there be any organism allied to bacteria present these micro-photographs should show it. No such organism is shown in any preparation photographed immediately after collection. The most important observation made related to certain granules in the white corpuscles shown in many of the micro-photographs taken.

From the manner in which these granules refract light, and for other reasons, they are believed by Dr. Sternberg to be fat, and to represent a fatty degeneration of the leucocytes.

In severe cases of yellow fever the granules were abundant, and nearly every white corpuscle contained some of them." (Report of the United States National Board of Health.)

In the specimens exhibited the granules are very conspicuous in two of blood taken on the first day and the fifth, both fatal cases. One of these suggests the appearance of micrococci. Granular or fatty degeneration of the white corpuscles has been quite lately noticed as a consequence of starvation, and is mentioned in a recent report on famine in India. Granules have also been observed on some white corpuscles in healthy blood. The micro-photograph of black vomit in yellow fever shows casts of the gastric follicles filled with colouring matter, but no blood-corpuscles in them. No alteration of the red corpuscles is seen in any of the micro-photographs.

May 4th, 1880.

---

9. *Fatty metamorphosis of the muscles of the leg, with talipes equino-varus from long-standing paralysis.* (*Card specimen.*)

Exhibited by FREDERIC S. EVE.

ALL the muscles of the leg are completely converted into fat, except that one or two patches of muscular fibre, retaining their colour, are seen on the surface of the gastrocnemius; the striation of the altered muscle is still visible.

The foot is immovably fixed in a position of talipes equino-varus, and the plantar fascia is contracted.

History.—Removed by amputation from a young woman, aged 17 years, because it was useless and cumbersome to her.

"Her legs became paralysed when she was three years old; they became deformed soon afterwards.

"The right leg was well formed and nourished, but the ankle weak and the foot flat. The left leg was smaller than the right, colder and bluer."[1]

March 16th, 1880.

10. *Dissection of a leg atrophied from infantile paralysis and amputated. From a patient, æt. 20.* (*Card specimen.*)

Exhibited by ALBAN DORAN.

THE fatty degeneration of the muscles is complete except in the sartorius; a horizontal section below shows the gastrocnemius and soleus to be converted into masses of fat. The cut surface above shows the muscular tissue of the semi-tendinosus also reduced

[1] 'Surgical Register, St. Bartholomew's Hospital.'

to fat and surrounded by a shell of tendon. The nerves are reduced in size, and contain much fat between their fibres.

March 16th, 1880.

11. *Recent division of the tendo Achillis.* (*Card specimen.*)

Exhibited by SAMUEL G. SHATTOCK.

THE ends of the divided tendon are separated by an interval of about three quarters of an inch, and are not altered in appearance; the space between them is filled with blood, which is effused also, into the surrounding adipose tissue. The ankle-joint is ankylosed by a thin layer of fibrous tissue continuous with the natural synovial folds. In two spots, on the tibia, the articular cartilage (which is elsewhere of natural thickness) has been perforated by ingrowths of the intervening tissue.

From a man, aged 37, in whom the tendon was divided for talipes, which followed in the repair of a compound fracture of the bones of the leg. The foot was amputated four days after the division of the tendon.

Patient under the care of Mr. Heath, March, 1879.

April 6th, 1880.

12. *The crown of a milk tooth which was exfoliated in the case of a syphilitic infant.* (*Card specimen.*)

Exhibited by JONATHAN HUTCHINSON.

AN infant, aged about three months, was brought to me at the London Hospital, by Mr. R. W. Parker, who kindly allowed me to obtain the specimen. The infant suffered from the usual symptoms of inherited syphilis in a severe degree. The point of interest was, however, that its gums were inflamed. The inflammation specially affected the region of the upper incisors. Over each central upper incisor was a small swelling, evidently an abscess on the point of bursting. These abscesses were symmetrical and limited to the region of the tooth named. On incising them pus escaped, and *in each instance the crown of the tooth dropped out.*

I have seen a similar case since, in which, again, the abscesses occurred in connection with the upper central incisors. Such cases are rare, and they are of great value as proving that during the course of inherited syphilis in early infancy inflammatory action does occur in the dental sacs, and further, that the upper central incisors are more prone than the others to suffer. This fact probably, to some extent, explains the frequency with which, in

the permanent set, the upper central incisors show malformations, whilst the others almost wholly escape.

Many years ago I exhibited similar specimens before this Society.

December 2nd, 1879.

13. *Chronic enlargement of a bursa patellæ.* (*Card specimen.*)

Exhibited by JONATHAN HUTCHINSON.

THE chief interest of this specimen consists in its size. It is the largest which I have seen. It was excised a week ago from the knee of a woman, æt. 48. It had been present for fifteen years, and had recently been punctured. It was as large when full as an infant's head. Its walls were thick in all parts, but much thicker in some than others. Obscure fluctuation could be detected, and its cavity contained upwards of half a pint of grumous fluid. An attempt to open it had been made before the patient came into the hospital, and there were several pressure ulcers on its surface. The skin adhered very firmly on most of its surface.

(This specimen is now in the Museum of the College of Surgeons).

November 4th, 1879.

14. *Portrait of an infant with a pedunculated occipital meningocele; also the occipital bone removed after death, showing the opening in the bone.* (*Card specimen, drawings only*).

Exhibited by the PRESIDENT for Dr. RODDICK (of Montreal).

THE portrait shows a rounded tumour, the size of a child's fist, attached by a thick peduncle to the lowest part of the occiput. There is also a sketch of the occipital bone, which shows an oval aperture which would admit a thumb in the middle line and about half an inch above the foramen magnum. It is separated from the latter by a bridge of bone. I believe that the existence of a bony bridge in this position is exceptional. I have dissected at least six such cases, and always found the cyst opening separated from the foramen magnum, by ligament only.

The infant's death was caused by an attempt to cure the disease. Under antiseptic dressings a seton was passed through the tumour, and an elastic ligature also applied round its base. It died (meningitis ?) about two weeks after this was done.

December 2nd, 1879.

15. *Gummata in the lung and testis.* (*Card specimen; drawings only.*)

Exhibited by JONATHAN HUTCHINSON.

Specimens obtained by Mr. Macarthy.

THE portraits show numerous *gummata in the lung*, all of which are well circumscribed, opaque, and of a greenish-yellow tint. They vary in size from a pin's head to a pea and to a small cherry. There were many others in other parts of the lung. A section of *one testis* from the same patient is shown in order to support the diagnosis of syphilis. In the substance of the gland large masses are seen, precisely similar in appearance to those in the lung. No softening has occurred in either organ. The patient had not complained of any lung symptoms. He died, after a short illness, in the London Hospital, with obstruction of the bowels. The diagnosis of syphilis rests upon the appearance presented in the two organs, and the presence of a scar on the penis. The right lung was the one affected and the left testis. The right testis showed evidences of old disease in the epididymis.

October 21*st*, 1879.

16. *Cystine calculus.* (*Card specimen.*)

By W. M. ORD, M.D.

A CYSTINE calculus weighing 1050 grains was exhibited by Dr. Ord. It had been removed by Mr. Reginald Harrison, of Liverpool, from a young man, by the lateral operation of lithotomy. The case ended successfully. The stone was exhibited on account of its size, which was greater than any on record.

XIII. SPECIMENS FROM THE LOWER ANIMALS.

1. *Enterolith—an oriental bezoar.*

By William M. Ord, M.D.

Apropos of the suggestion that a gall-stone which I have exhibited this evening was an enterolith,[1] I now exhibit an enterolith which was presented to the museum of St. Thomas's Hospital as a gall-stone. The concretion is of an elongated oval shape somewhat constricted round the middle. Its surface is smooth, polished, and of a chocolate-brown colour, like that of bronzed steel. Its section is concentrically laminated, of a dark greyish-brown colour, and when scraped by a knife presents a waxy lustre.

On chemical examination it appears to contain neither uric acid, cholesterin, nor earthy matters, but gives the reactions of ellagic acid (called by some authors "bezoardic"). These are, briefly, as follows:—Heated on platinum foil it readily becomes inflamed and burns with a resinous-smelling smoke, leaving only a trace of ash. It is insoluble in hydrochloric acid, freely soluble in liquor potassæ, forming a solution which becomes dark brown on exposure to the air, and which on being left to evaporate deposits a blackish powder. This powder when magnified is found to consist of blue-black crystals (glaucomelanate of potash). When the potash solution is neutralised by an acid a copious, pale buff-coloured precipitate is produced. The powdered calculus is little soluble in ammonia, is slightly soluble in hot alcohol, and is insoluble in water. It is dissolved by warm sulphuric acid and thrown down again on the addition of a large quantity of water. Placed in a porcelain capsule and treated with nitric acid it gives a dull Indian-red colour, a little brightened by ammonia added after the evaporation of the acid, but altogether different from the crimson colour of the

[1] See p. 139.

uric acid reaction. In its chemical relations ellagic acid is connected with gallic acid, and is obtained with that acid from gall-nuts. In its pathological relations it forms the principal constituent of oriental bezoars. The identification of this acid as the main constituent of oriental bezoars is generally attributed to Merklein and Wöhler, but any one who will refer to Mr. Thomas Taylor's papers on animal concretions in the 'London and Edinburgh Philosophical Magazine,' vol. xxiv (1844), and vol. xxviii (1846), p. 43, will have no difficulty in deciding that the discovery was first made by that gentleman in the course of his analysis of the calculi in the museum of the Royal College of Surgeons. Mr. Taylor's analysis was published in 1843, MM. Merklein and Wöhler's in 1845. These oriental bezoars are found in the alimentary canal of goats and antelopes in Western India and Persia. The exact part of the tract in which they are formed is not clearly stated in books on the subject, some indicating the cæcum, some the pyloric end of the stomach. The origin of the concretion from substances used as food is clear. The specimen exhibited presents the general physical characters belonging to oriental bezoars.

January 6th, 1880.

---

2. *Colon of a sheep, showing colotomy performed by a parrot.*

By John Wood, for Harry A. De Lautour.

This specimen consists of a portion of a sheep's colon with the right half of the lower lumbar vertebræ and the skin over the right loin. There is an aperture, quite circular and about a quarter of an inch in diameter, in the colon, firmly united by adhesions to the integument, which is also perforated. The outer opening is surrounded by a circle of short coarse wool, external to which is a bald area over an inch wide; the wool beyond this area is normal. The colon above the artificial aperture shows marked hypertrophy of its muscular coat, whilst below this artificial anus the same coat has undergone atrophy. The bowel is contracted opposite the opening, so that it can hardly admit the little finger.

The most interesting feature about the case is that the artificial anus was made by a Kea parrot (*Nestor notabilis*, Gould), well-known

to settlers in the mountainous districts near Otago, New Zealand. The ordinary food of this bird appears to be berries, insects, &c., but it has developed a taste for raw mutton, acquiring it in the first case from dead sheep,[1] and then attacking the live animal. On shearing the sheep, the shepherds find that numbers of them have large raw surfaces on the loins, as big as the palm of the hand, or scabs, or, not unfrequently, an artificial anus whence the dung escapes, befouling the wool in the neighbourhood. This latter condition is shown in this specimen, for which Mr. De Lautour is indebted to Mr. Middleton, manager of the Benmore Station, which belongs to the Hon. Robert Campbell. When the sheep was examined, it was found to be in a poor condition; there was a great absence of fat, but all the organs excepting the colon appeared to be healthy. The artificial anus was situated midway between the crest of the ilium and the last rib on the right side, and about three inches from the spinous processes of the lumbar vertebræ. The colon was not surrounded by peritoneum at the point of perforation; the circular contraction appeared to form a valve directing the fæces in their new direction. The fæces were quite liquid; the intestine above the aperture was much distended by them, the colon below also contained a small quantity.

The *modus operandi* appears to be as follows: the parrots, bold inquisitive birds, generally hunting in pairs, single out the strongest and fattest sheep in a flock, especially those with the longest wool. One bird alone settles on each of these sheep, invariably perching on the sacrum, probably because it is there the least shaken by the sheep's movements. The parrot then pulls off the wool with its beak, causing it to fly off in clouds, then rapidly tears into the skin and eats the flesh till the poor animal falls from exhaustion, shock, or loss of blood. The opening is said to be invariably on the right loin, but some shepherds deny this assertion. The sheep from

[1] In Professor W. H. Flower's lectures "On the Organs of Digestion in the Mammalia" ('Med. Times and Gaz.,' vol. i, 1872, p. 217), this habit is referred to as illustrating voluntary change of diet in a wild animal, in adaptation to change of circumstances. Mr. T. H. Potts, 'Nature,' vol. ii, 1871, p. 489, first recorded the carnivorous tendencies of this bird. Any assertion that the colon itself is sought for by instinct must be considered purely hypothetical; the description of the manner in which the parrot feeds on the sheep, as given at the end of this paper, leads to the conclusion that, through constant pecking at the same spot, the intestine is opened by accident.

which this specimen was taken had lived for eighteen months with the artificial anus. The upper beak in parrots of the genus *Nestor* is very long and curved, and also remarkably sharp at the point and along its edges, as may be seen from the specimen of a Kea parrot sent with the sheep's colon and exhibited with it this evening. The preparation is now in the museum of the Royal College of Surgeons (1389A). *November 4th*, 1879.

APPENDIX, VOL. XXXI.

Report of the Committee on Morbid Growths on Mr. Gay's specimen of recurrent mammary tumour. (See page 272.)

THE tumour consists of three portions: the first subcutaneous, spheroidal, and two and a half inches in diameter; the second forms a fungating mass, overlapping the skin, two and a half inches across, and projecting one inch from the surface; the third immediately underlies the second, and serves to connect it with the deeper subcutaneous tissues. The first portion is soft and opaque-white, except just at the deepest part, where it is somewhat translucent. The section of the second is striated perpendicularly to the surface, the striæ being alternately opaque-white and translucent grey; the central portion of this is undergoing necrotic changes. In the third the opaque and translucent areas are disposed without definite order.

In structure all parts of the tumour consist essentially of spindle-cells, having a length of $\frac{1}{800}$ inch, and having a breadth of $\frac{1}{4000}$ inch. In the opaque-white portions these cells are packed closely together, and are without stroma. In the more translucent portions the bundles are more or less widely separated by gelatinous intercellular substance, containing round and many-tailed cells. The tumour is therefore a spindle-celled sarcoma, probably rapidly growing towards the circumference.

H. G. HOWSE.
FREDERICK TAYLOR.

Read Nov. 2nd, 1880.

N.B.—As Mr. Gay's specimen was shown at the last meeting of the Society before the vacation, this report could not be presented in time for insertion in its regular place.

INDEX.

ABDOMEN, fatty tumour of, showing fibrous and osseous changes (J. Dreschfeld) 287

ABDOMINAL CAVITY, tumour found loose in (F. S. Eve) . . 311

ABERCROMBIE (*John*), three cases of sarcomatous growths invading both kidneys from without 168

„ multiple sarcomata of cranial bones 216

„ *report* on ditto by Morbid Growths Committee (M. Beck and R. J. Godlee) 221

„ cranial bones 244

„ case of varicella gangrænosa 333

ACID, see *Carbolic*.

ADAMS (*Wm.*), an Achilles tendon which had reunited, with formation of 1½ inch of new tendon, after subcutaneous division four years before death . 372

„ sequel to a case of syphilitic gummata (in vol. xx of the 'Transactions,' p. 309) 374

ANDERSON (*A. R.*); *per W. J. Walsham*, myxo-sarcoma of the head of the tibia 309

ANASTOMOSIS, see *Aneurysm*.

ANEURYSM of AORTA opening into right auricle (N. Moore) . . 82

„ intra-cardiac, at the root of the aorta, opening into right auricle (W. Ewart) 95

„ extra-pericardial, of ascending aorta, small orifice, leakage into pericardium (ditto) 82

„ intra-pericardial, of the aorta, opening into the left auricle (ditto) . 96

„ of aortic arch; rupturing into trachea (H. G. Orlebar) . . 98

„ of abdominal aorta and external iliac artery, opening into vena cava (P. H. Pye-Smith) 85

„ and rupture of aortic valve (H. G. Orlebar) 97

„ of pulmonary artery, death from rupture of, in a case of excavation of one lung (S. West) 50

„ by anastomosis, of the ear (F. S. Eve) 88

ANIMALS, LOWER, SPECIMENS from 385-388

AORTA, deformity of, produced by caries of spine (A. E. Barker) . . 246

„ transposition of, in a case of malformation of the heart (D. B. Lees) . 58

„ superior, from supernumerary ventricle, and descending aorta formed by pulmonary artery, &c. (S. Mackenzie) 66

„ communication with both ventricles in a case of malformation of the heart (T. B. Peacock and T. Barlow) 91

„ see *Aneurysm* of.

AORTIC ARCH, aneurysm of, rupturing into trachea (H. G. Orlebar) . 98

AORTIC ORIFICE, complete occlusion of, by a fibrinous and calcareous mass (H. R. Crocker) 93
AORTIC VALVE, aneurysm in and rupture of (H. G. Orlebar) . . 97
„ incompetency of, from a strain, endocarditis, and formation of polypoid in left ventricle, &c. (E. H. Greenhow) 73
„ perforation of one (H. R. Crocker) 93
„ stenosis of (J. P. Irvine) 79
ARM, malformation of (A. Sturge) 208
„ cartilaginous tumour of (W. H. Cripps) 287
ARTERIES, brachial, hepatic, and mesenteric, blood-clots in (H. T. Butlin) . 76
„ CEREBRAL, congenital malformation of, in a case of ramifying cyst in the brain (Wm. Ewart) 1
ARTERY, ILIAC, see *Aneurysm of.*
„ PULMONARY, absence of (T. B. Peacock and W. C. Reed) . . 91
„ — contraction of, with only two valves (S. Mackenzie) . . 63
„ — complete occlusion of right division of, and atheroma (W. Ewart) . 99
„ — stenosis of (T. B. Peacock and T. Barlow) . . . 91
„ — transposition of, in a case of malformation of the heart (D. B. Lees) . 58
„ — — of, and of superior cava (H. R. Crocker) . . . 92
ARYTÆNOID CARTILAGE, necrosis of, during convalescence from smallpox (Fred. S. Eve) 33
„ necrosis of, in typhoid fever (Fred. S. Eve) . . . 35
ASCITES, associated with papilloma of the Fallopian tube (A. Doran) . 174
ATAXY, LOCOMOTOR, united fracture of right ulna, from a case of (W. B. Hadden) 245
„ — lower extremity of a right femur, from a case of (ditto) . . 245
ATELECTASIS of LUNGS, with emphysematous cyst (T. Barlow) . . 48
ATROPHY of LEG from infantile paralysis (A. Doran) . . . 381
„ of the LIVER, acute (S. West) 116
„ of OPTIC NERVE and RETINA, in an eye lost by erysipelas spreading to the orbit (E. Nettleship) 254
AURICLE, LEFT, firm clot in, leaving narrow channel for the blood (J. P. Irvine) 79
AXIS-CYLINDER, degeneration and regeneration of, in non-traumatic nerve lesion, with reference to gangrene of the cutaneous nerves (Geo. Hoggan) . 12
„ in healthy portion of nerve (ditto) 14
„ regeneration of (ditto) 18
„ in degenerating portion of nerve (ditto) 21
„ conclusions (ditto) 25

BAKER (*W. Morrant*), case of lichen ruber 334
BARKER (*Arthur E. J.*), caries of spine, producing aortic deformity and probable obstruction 246
„ on a peculiar circular wandering rash on the tongue . . . 353
BARLOW (*Thomas*), laryngitis in congenital syphilis . . . 46
„ atelectasis of lungs with emphysematous cyst, congenital heart disease . 48
„ gumma of tongue in hereditary syphilis (living specimen) . . 101
„ disease of growing ends of shafts of long bones in congenital syphilis . 229
„ cranio-tabes, associated with congenital syphilitic disease of parietal bone . 236
„ see *Peacock* and Barlow, malformation of heart.
„ see *Steavenson.*
BECK (*Marcus*), *report* on John Abercrombie's case of tumours of the vault of the skull 221
„ *report* on H. Morris's specimen of pulsating tumour of cranium . 270
„ *report* on T. W. Nunn's case of recurrent tumour of the breast . 276

BEZOAR STONE, oriental (W. M. Ord) 385
BLADDER, mucous membrane of, showing miliary tubercles (W. Ewart) . 190
BLOOD, micro-photographs of, in yellow fever (W. Squire) . . 380
BLOOD-CASTS of the bronchi (S. West) 53
BLOOD-CLOTS in brachial and other arteries, &c. (H. T. Butlin) . 76
BLOOD-VESSELS, changes in, in granular kidney (R. Saundby) . . 155
BONES, DISEASES of 193-251
BONES, case of disease of, in a fœtus, presumably syphilitic (F. S. Eve) . 233
„ disease of growing ends of shafts of long bones, in congenital syphilis (T. Barlow) 229
„ lesions of, in congenital syphilis (R. W. Parker) . . . 226
„ — in tabes dorsalis (Tho. Buzzard) 193
„ cranial, multiple sarcomata of (J. Abercrombie) . . . 216
„ parietal, cranio-tabes, associated with congenital syphilitic disease of (T. Barlow) 236
„ left parietal, &c., pulsating tumour of, with hypertrophy of the heart (H. Morris) 259
„ see *Jaw-bone.*
BONY OUTGROWTHS of the great trochanter, simulating dorsal dislocation of the hip (H. Morris) 214
BOSSES, CRANIAL (J. Abercrombie) 244
BRACHICAL PLEXUS, supposed rupture of most of the roots of (Jon. Hutchinson) 27
BRAIN, ramifying cyst in, with congenital malformation of cerebral vessels (W. Ewart) 1
BREAST, cancerous tumour of, histology of (Geo. Thin) . . 294
„ recurrent tumour of, spindle-celled sarcoma; sixth removal (John Gay) . 272
„ — removed seven years after first operation (T. W. Nunn) . . 276
BRONCHI, blood casts of (S. West) 53
„ old syphilitic scars in, stricture, &c., leading to chronic disease in the lungs (W. Ewart) 57
„ membranous inflammation of, in an adult (P. H. Pye-Smith) . . 30
BUCHANAN (*George*), on some appearances, probably of parasites, in the voluntary muscles in enteric fever 366
BURSA PATELLÆ, chronic enlargement of a (J. Hutchinson) . . 383
BUTLIN (*Henry T.*), fibroid patch of inter-ventricular septum of heart, blood-clots in brachial and other arteries, gangrene of jejunum . . 76
„ myeloid sarcomata of lower jaw and rib; mollities ossium . . 277
„ *report* on S. Coupland's primary sarcoma of the liver . . 135
„ *report* on H. Morris's specimen of pulsating tumour of cranium . 270
BUZZARD (*Thomas*), cases of osseous and articular lesions in tabes dorsalis 193

CALCULUS, alternating, with layers of lithates and lithic acid, encrusted by oxalate of lime (J. Hutchinson) 192
„ removed by supra-pubic lithotomy (P. Swain) . . . 184
„ CYSTINE, 1050 grains (W. M. Ord) 384
„ mixed, of cystine and oxalate of lime (S. G. Shattock) . . 182
„ BILIARY, on the structure and formation of (W. M. Ord) . . 139
„ — passed per anum (W. M. Ord) 139
„ — ulcerating into duodenum (N. Moore) 109
„ from the kidney (W. M. Ord) 185
„ branched renal (C. H. Ralfe) 189

CANCER, series of fifteen drawings of (J. W. Hulke) . . . 311
„ of anus (J. W. Hulke) 313
„ of breast, cases of (J. W. Hulke) . . . 311-312
„ — histology of (Geo. Thin) 294
„ of lower lip, cases of (J. W. Hulke) 312
„ of the liver, appearances observed in a case of (Geo. Thin) . . 293
„ of penis and inguinal glands (J. W. Hulke) . . . 314
„ of the sigmoid flexure, gangrene of bowel, peritonitis (J. F. Goodhart) . 113
„ of womb (J. W. Hulke) 313
„ primary, of the gall bladder (N. Moore) 138
„ — (epithelioma) of the gall bladder (S. Coupland) . . . 136
„ — diffuse, of liver, combining characters of sarcoma and carcinoma (S. Coupland) 130
„ chimney sweep's (J. W. Hulke) 313-314
„ see *Carcinoma*.

CANCRUM ORIS, diseased jaw-bone from case of (W. H. Cripps) . . 242

CARBOLIC ACID POISONING, acute, œsophagus and stomach from a case of (Rt. Smith) 143

CARCINOMA of the liver (S. Coupland) 130
„ primary, of the liver (P. H. Pye-Smith) 125
„ medullary, of duodenum, occluding hepatic ducts (S. Coupland) . 145
„ see *Cancer*.

CARIES of spine producing aortic deformity (A. E. Barker) . . 246

CHIN, vesicular wart-like growth on (J. Hutchinson) . . . 342
„ — microscopical *report* on (A. Sangster) 346

CHOLESTERIN in a degenerated eyeball, from a child (J. Hutchinson) . 253

CHONDRITIS and PERICHONDRITIS of thyroid cartilage, in a case of epithelioma of the larynx (F. Semon) 55

CHONDRO-SARCOMA, ossifying, of both femora, with secondary deposits in lungs and bronchial and lymphatic glands (R. W. Parker) . . . 223

CHURCH (*W. S.*), case of necrosis of arytænoid cartilage in typhoid fever (Fred. S. Eve) 35

CIRCULATION, ORGANS of, DISEASES, &c., of . . 58-100

CIRRHOSIS of the liver in a child (F. Taylor) . . . 119

CLAVICLE, dislocation upwards of acromial end of, with fracture of clavicle (F. S. Eve) 245
„ pulsating tumours of, with hypertrophy of the heart (H. Morris) . 259

COLOTOMY performed by a parrot on a sheep (H. A. de Lautour) . 386

COMMITTEE ON MORBID GROWTHS, REPORTS:
„ on S. Coupland's specimen of primary sarcoma of the liver (J. F. Goodhart and H. T. Butlin) 135
„ on John Abercrombie's case of tumours of the vault of the skull (M. Beck and R. J. Godlee) 221
„ on H. Morris's specimen of pulsating tumour of cranium (M. Beck, H. T. Butlin, and R. J. Godlee) 270
„ on T. W. Nunn's case of recurrent tumours of the breast (M. Beck and R. J. Godlee) 276
„ on John Gay's specimen of recurrent mammary tumour (H. G. Howse and Fred. Taylor) 389

CONNECTIVE TISSUE, changes in, in granular kidney (R. Saundby) . 156
„ relations of elephantiasis arabum to (G. Thin) . . . 337

CORD, see *Spermatic cord, Spinal cord.*

CORNIL (*V.*), letters on the characters of H. Morris's pulsating tumour of the cranium 267
COUPLAND (*Sidney*), primary diffuse malignant growth in the liver, combining characters of sarcoma and carcinoma 130
„ — *report* of Morbid Growths Committee on (J. F. Goodhart and H. T. Butlin) 135
„ primary cancer (epithelioma) of the gall-bladder . . . 136
„ volvulus of small intestine due to a complete Meckel's diverticulum . 144
„ medullary carcinoma of duodenum, beyond pylorus, occluding hepatic ducts 145
„ hernia of ileum through a rent in the great omentum . . 146
„ ostitis with ulceration of skull, gummatous infiltration of dura mater, &c., from a case of syphilis 243
„ two cases of late hereditary syphilis 376
CRANIAL BOSSES (J. Abercrombie) 244
CRANIO-TABES, associated with congenital syphilitic disease of parietal bone (T. Barlow) 236
CRANIUM, two cases of disease of (N. Moore) . . . 238
„ ostitis, with ulceration of, &c., from a case of syphilis (S. Coupland) . 243
„ pulsating tumour of (H. Morris) 259
CRICOID CARTILAGE, necrosis of, during convalescence from smallpox (Fred. S. Eve) 33
CRIPPS (*W. Harrison*), volvulus of the ileum . . . 111
„ imperforate rectum 112
„ diseased jaw-bone from case of cancrum oris . . . 242
„ cartilaginous tumour of arm 287
CROCKER (*H. R.*), congenital malformation of the heart of a girl, æt. 13, transposition of pulmonary artery, &c. 92
„ complete occlusion of aortic orifice by a fibrinous and calcareous mass, &c. 93
„ histology and pathology of morphœa and its relation to scleroderma adultorum 315
CYST, ramifying, in the brain, with congenital malformation of cerebral vessels (W. Ewart) 1
CYSTINE, see *Calculus*.

DAY (*W. H.*), and *J. Knowsley THORNTON*, cystic kidney removed from a child 167
DEGENERATION, fatty, of the heart after hæmorrhage in typhoid fever (J. F. Goodhart) 71
DERMOID, see *Tumour* (dermoid).
DIGESTION, ORGANS of, DISEASES, &c., of . . . 101-147
DISEASES, &c., OF THE NERVOUS SYSTEM 1-29
„ of the ORGANS OF RESPIRATION . . . 30-57
„ of the ORGANS OF CIRCULATION . . . 58-100
„ of the ORGANS OF DIGESTION . . . 101-147
„ of the GENITO-URINARY ORGANS . . . 148-192
„ of the OSSEOUS SYSTEM 193-251
„ of ORGANS OF SPECIAL SENSE . . . 252-255
„ MORBID GROWTHS 256-314
„ of the SKIN 315-349
„ of the SUPRA-RENAL CAPSULES . . . 350-352
„ MISCELLANEOUS SPECIMENS 353-384
„ SPECIMENS FROM THE LOWER ANIMALS . . 385-388
DISLOCATION of acromial end of clavicle (F. S. Eve) . . 245
„ of the hip-joint from disease (H. A. Lediard) . . 247-248
„ of the external semilunar fibro-cartilage of the knee-joint (R. J. Godlee) . 240
„ recent, of the first phalanx of the thumb forwards (F. S. Eve) . . 216

DIVERTICULUM, Meckel's, volvulus of small intestine due to a (S. Coupland) 144

DORAN (*Albert*), papilloma of the Fallopian tube, with ascites and pleuritic effusion 174
„ dilatation of Fallopian tubes 192
„ dissection of a leg atrophied from infantile paralysis and amputated, from a patient æt. 20 381
„ see *Harris* (*V.*) and A. Doran.

DRESCHFELD (*J.*) fatty tumour of abdomen, showing fibrous and osseous changes 287

DUCKWORTH (*Dyce*), case of scleroderma adultorum, illustrating its circumscribed and diffuse forms 322

DUODENUM, medullary carcinoma of, occluding hepatic ducts (S. Coupland) 145
„ congenital occlusion of, above the common bile-duct (G. Eastes) . 114
„ see *Ulcer* of.

EAR, see *Aneurysm* by anastomosis.

EASTES (*George*), *per James F. Goodhart*, congenital occlusion of the duodenum above the common bile-duct 114

ELEPHANTIASIS ARABUM, histology of, and its relations to normal connective tissue (G. Thin) 337

EMPHYSEMATOUS CYST in a case of atelectasis of lungs (T. Barlow) . 48

ENCHONDROMA, large recurrent, of the upper jaw (J. H. Keeling) . 250

ENDOCARDITIS following incompetency of aortic valves (E. H. Greenhow) 73

ENTERIC FEVER, necrosis of the cartilages of the larynx in (Fred. S. Eve) 33
„ appearances, probably of parasites, in the voluntary muscles in (G. Buchanan) 366
„ see *Typhoid* Fever.

ENTEROLITH, an oriental bezoar (W. M. Ord) . . . 385

EPIDIDYMIS and CORD, myxo-fibroma of (J. Gay) . . . 310

EPITHELIOMA of the gall-bladder (S. Coupland) . . . 136
„ of larynx, secondary deposits in lymphatic glands, &c. (F. Semon) . 55
„ of the pharynx, involving the larynx, trachea, and œsophagus (T. Gilbart Smith) 102
„ of the penis (Tho. W. Nunn) 298

EPITHELIUM, changes in, in granular kidney (R. Saundby) . . 152

EVE (*Frederic S.*), cases of necrosis of the cartilages of the larynx in smallpox, and enteric fever (Fred. S. Eve) 33
„ a case of so-called aneurysm by anastomosis of the ear . . 88
„ hernia into the vaginal process of peritoneum and undescended testicle . 147
„ patent vaginal process of peritoneum 147
„ case of cystic degeneration of the kidneys 164
„ syphilitic disease of testicle 190
„ recent dislocation of the first phalanx of the thumb forwards . . 216
„ case of disease of the bones in a fœtus, presumably syphilitic . . 233
„ dislocation upwards of the acromial end of clavicle, with fracture of clavicle 245
„ lympho-sarcoma, "lymphadenoma," of the mediastinum involving the pericardium 279
„ tumour found loose in abdominal cavity 311
„ fatty metamorphosis of the muscles of the leg, with talipes equino-varus from long-standing paralysis 381

EWART (*William*), ramifying cyst in the brain, with congenital malformation of cerebral vessels 1
„ old syphilitic scars in the larynx, trachea, and bronchi, stricture of bronchi, &c. 57
„ extra-pericardial aneurysm of the ascending aorta, unusually small orifice, leakage into pericardium without visible perforation . . . 82
„ fibro-cretaceous ring surrounding the heart, in the situation of the auriculo-ventricular sulcus 94
„ intra-cardiac aneurysm at the root of the aorta, opening into the right auricle 95
„ intra-pericardial aneurysm of the aorta opening into the left auricle . 96
„ complete occlusion of right division of pulmonary artery, atheroma . 99
„ hernia of abdominal viscera into left pleura . . . 146
„ cystic degeneration of left kidney and ureter, during intra-uterine life . 187
„ congenital malposition and cystic degeneration of left kidney . . 187
„ two complete ureters on either side of the body . . . 188
„ mucous membrane of the bladder showing miliary tubercles . . 190
„ fibrous and calcareous changes in both supra-renal capsules, perhaps of syphilitic origin 352
EXCISION of knee-joint; bone twelve years afterwards (H. A. Lediard) . 247
EYE, spontaneous intra-ocular hæmorrhage in an infant (E. Nettleship) . 253
EYEBALL, degenerated, and containing much cholesterin, from a child (J Hutchinson) 253
EYELID, horny growth from the lower, of an old woman (W. J. Walsham) 306

FACE, plexiform sarcoma of (Jer. McCarthy) 256
FALLOPIAN TUBES, dilatation of (A. Doran) . . . 192
„ papilloma of, with ascites and pleuritic effusion (A. Doran) . . 174
FATTY CHANGES, acute, in an enlarged liver (C. H. Ralfe) . . 144
FATTY METAMORPHOSIS, of the muscles of the leg (F. S. Eve) . 381
FATTY TUMOURS, see *Tumours.*
FEMORA, ossifying chondro-sarcoma of both, with secondary deposits in lungs and bronchial and lymphatic glands (R.W.Parker) . . . 223
„ both, &c., pulsating tumours of, with hypertrophy of the heart (H. Morris) 259
FEMUR, impacted fracture of the neck of, complicated by bony outgrowths of the great trochanter (H. Morris) 214
„ right, lower extremity of, from a case of locomotor ataxy (W. B. Hadden) 245
FEVER, see *Enteric* Fever, *Typhoid* Fever.
FIBROID PATCH, of interventricular septum of heart (H. T. Butlin) . 76
FIBROMA, see *Myxo-fibroma.*
FINGER, melanosis of (R. J. Godlee) 336
„ — of the little (T. W. Nunn) 299
FISHER (*Thomas*), *per T. B. Peacock*, case of rupture of right ventricle of the heart 72
FŒTUS, case of disease of the bones in, presumably syphilitic (F. S. Eve) . 233
FORAMEN OVALE, closed, in malformation of the heart (S. Mackenzie) . 63
„ patent, incomplete septum (H. R. Crocker) . . . 92
„ and ductus arteriosus patent, in a case of malformation of the heart (S. Mackenzie) 66
FRACTURE of clavicle and dislocation of acromial end of ditto (F. S. Eve) 245
„ of right ulna from a case of locomotor ataxy (W. B. Hadden) . . 245
„ impacted, of the neck of the femur, complicated by bony outgrowth of the great trochanter (H. Morris) 214

FUNGUS of tinea imbricata (G. Thin) 339

GALL-BLADDER, primary cancer (epithelioma) of (S. Coupland) . 136
„ primary cancer of (N. Moore) 138

GALL-STONE, see *Calculi* (biliary).

GANGRENE of the bowel, in a case of cancer of sigmoid flexure (J. F. Goodhart) 113
„ of portion of jejunum (H. T. Butlin) 76
„ of the cutaneous nerves, degeneration and regeneration of the axis-cylinder with reference to (Geo. Hoggan) 12

GAY (*John*), recurrent mammary tumour; spindle-celled sarcoma, the sixth removal 272
„ — *report* of the Committee on Morbid Growths on ditto (H. G. Howse and F. Taylor) 389
„ *per James F. Goodhart*, myxo-fibroma of epididymis and cord . . 310

GENERATION, ORGANS of, DISEASES, &c., of . . 148-192
„ organs of, persistent communication of rectum with track of, in newborn male child (S. G. Shattock) 191

GODLEE (*R. J.*), dislocation of the external semilunar fibro-cartilage of the knee-joint 240
„ melanosis of finger 336
„ *report* on John Abercrombie's case of tumours of the vault of the skull . 221
„ *report* on H. Morris's specimen of pulsating tumour of cranium 270
„ *report* on T. W. Nunn's case of recurrent tumour of the breast . 276

GOODHART (*James F.*), case of suppurative myocarditis with scarlatinal nephritis 70
„ case of fatty degeneration of the heart after hæmorrhage in typhoid fever 71
„ cancer of the sigmoid flexure, gangrene of the bowel, peritonitis . 113
„ see *Eastes* (*George*).
„ see *Gay* (*J.*).
„ *remarks* on the microscopical structure of H. Morris's pulsating tumour of cranium 265
„ *report* on S. Coupland's primary sarcoma of the liver . . 135

GREENFIELD (*W. S.*), granular contracted kidney . . . 157

GREENHOW (*Edward H.*), incompetency of the aortic valves from a strain, endo-carditis and formation of polypoid in left ventricle, ulceration and erosion 73

GROSS (*S. W.*), *report* of a case of multiple central medullary round-celled sarcoma of the osseous centre system 268

GROWTHS, MORBID 256-314

GUMMA of testis from a boy the subject of inherited syphilis (J. Hutchinson) 192
„ of tongue, in hereditary syphilis (T. Barlow) . . . 101

GUMMATA in the lung and testis (J. Hutchinson) . . . 384
„ syphilitic, sequel to a case of in vol. xx of the 'Trans.,' p. 309 (W. Adams) 374

HADDEN (*W. B.*), united fracture of right ulna from a case of locomotor ataxy 245
„ lower extremity of a right femur from a case of locomotor ataxy . 245

HÆMORRHAGE in typhoid fever followed by fatty degeneration of the heart (J. F. Goodhart) 71
„ spontaneous intra-ocular, in an infant (E. Nettleship) . . 253

HARRIS (*Vincent*) and *Alban DORAN*, spinal cord from a case of tetanus following ovariotomy 7

HARRISON (*Reginald*), cystine calculus, 1050 grains 384

HEART, congenital disease of, in a case of atelectasis of lungs (T. Barlow) . 48
„ fatty degeneration of, after hæmorrhage in typhoid fever (J. F. Goodhart) 71
„ fibro-cretaceous ring surrounding the heart in the situation of the auriculo-ventricular sulcus (W. Ewart) 94
„ fibroid patch of interventricular septum of, blood clots in brachial and other arteries, gangrene of jejunum (H. T. Butlin) . . . 76
„ hypertrophy of, in a case of pulsating tumours of cranium (H. Morris) . 259
„ malformation of, congenital (L. Mackenzie) . . . 63
„ — congenital, in a girl, æt. 13 (H. R. Crocker) . . . 92
„ — absence of pulmonary artery (T. B. Peacock and W. C. Reed) . 91
„ — stenosis of pulmonary artery, &c. (T. B. Peacock and T. Barlow) . 91
„ — with transposition of the aorta and pulmonary artery (D. B. Lees) . 58
„ rupture of right ventricle (T. Fisher) 72

HEPATIC DUCTS, medullary carcinoma of duodenum, occluding (S. Coupland) 145

HERNIA of abominal viscera into left pleura (W. Ewart) . . 146
„ of ileum, through a rent in the great omentum (S. Coupland) . . 146
„ into the vaginal process of peritoneum and undescended testicle (F. S. Eve) 147

HIP, dorsal dislocation of, simulated by outgrowth of great trochanter (H. Morris) 214

HIP-JOINT, dislocation of, from disease (H. A. Lediard) . 247-248

HOGGAN (*George*), on degeneration and regeneration of the axis-cylinder in non-traumatic nerve lesions, with reference to gangrene of the cutaneous nerves 12

HORNY GROWTH from the lower eyelid of an old woman (W. J. Walsham) 306

HOWSE (*Henry G.*), *report* on John Gay's specimen of recurrent mammary tumour 389

HULKE (*John W.*), series of fifteen drawings of cancer exhibited by him 311-314

HUTCHINSON (*Jonathan*), case of supposed rupture of most of the roots of the brachial plexus 27
„ an alternating calculus, consisting of layers of lithates and lithic acid, encrusted by oxalate of lime 192
„ gumma of testis from a boy the subject of inherited syphilis . . 192
„ osteitis of the ulna in connection with inherited syphilis . . 248
„ dwarfing of the tibia following detachment of its lower epiphysis . 249
„ chronic osteitis in connection with inherited syphilis . . 250
„ *per E. Nettleship*, eyeball degenerated and containing much cholesterin from a child 253
„ on a peculiar papulo-vesicular eruption: lupus lymphaticus [vesicular wart-like growth on chin] 342
„ — *report* of microscopical appearances of ditto, by A. Sangster . 346
„ pigmented mole with elephantoid hypertrophy of the mons and labium, growth after excision, second operation 348
„ case of molluscum fibrosum, one tumour very large and pendulous . 349
„ a peculiar form of mole, the "cock's-comb mole" . . . 349
„ the crown of a milk tooth exfoliated in the case of a syphilitic infant . 382
„ chronic enlargement of a bursa patellæ 383
„ gummata in the lung and testis 384
„ see *Keeling, Roddick.*

HYPERTROPHY of the heart, in a case of pulsating tumour of cranium (H. Morris) 259
„ of the mons and labium in a case of pigmented mole (J. Hutchinson) . 348

ILEUM, hernia of, through a rent in the great omentum (S. Coupland) . 146
„ volvulus of the (W. H. Cripps) 111
ILIUM, pedunculated fatty tumour from the anterior superior spine of the (W. J. Walsham) 310
INFLAMMATION, membranous, of the larynx, trachea, and bronchial tubes in an adult (P. H. Pye-Smith) 30
INTESTINES, DISEASES of 101-147
„ small, volvulus of, due to a complete Meckel's diverticulum (S. Coupland) 144
„ see *Jejunum*.
IRVINE (*J. Pearson*), aortic, mitral, and tricuspid stenosis, firm clot in left auricle, leaving only narrow channel for the blood . . . 79

JAW-BONE, diseased, from case of cancrum oris (W. H. Cripps) . . 242
„ LOWER, myeloid sarcomata of, mollities ossium (H. T. Butlin) . . 277
„ UPPER, large recurrent enchondroma of (J. H. Keeling) . . 250
JEJUNUM, gangrene of portion of (H. T. Butlin) . . . 76
JOINTS, lesions of, in tabes dorsalis (Thos. Buzzard) . . . 193
„ see *Hip-joint*, *Knee-joint*.

KEELING (*J. H.*), *per Jon. Hutchinson*, large recurrent enchondroma of the upper jaw 250
KIDNEY, cystic, removed from a child (W. H. Day and J. K. Thornton) . 167
„ case of cystic degeneration of (F. S. Eve) . . . 164
„ left, cystic degeneration of, and congenital malposition of (W. Ewart) . 187
„ left, and ureter, cystic degeneration of, during intra-uterine life (W. Ewart) 187
„ granular, the histology of [changes in epithelium, Malpighian bodies, blood-vessels, and connective tissue] (R. Saundby) . . . 148
„ — bibliography of 156
„ granular, contracted (W. S. Greenfield) 157
„ horseshoe (Norman Moore) 188
KIDNEYS, sarcomatous growth invading both, from without (J. Abercrombie) 168
„ the two, united by a fibrous band (H. A. Lediard) . . . 189
KNEE-JOINT, dislocation of the external semilunar fibro-cartilage (R. J. Godlee) 240
„ excision of: bone twelve years afterwards (H. A. Lediard) . . 247

LABIUM, hypertrophy of, in a case of pigmented mole (J. Hutchinson) . 348
LARYNGITIS in congenital syphilis (T. Barlow) . . . 46
LARYNX, epithelioma of, secondary deposits in lymphatic glands, &c. (F. Semon) 55
„ membranous inflammation of, in an adult (P. H. Pye-Smith) . . . 30
„ necrosis of the cartilages of, in smallpox and enteric fever (Fred. S. Eve) . 33
„ congenital syphilis of, two cases (F. Semon) . . . 41
„ old syphilitic scars in, stricture of bronchi, &c., leading to chronic disease in the lungs (W. Ewart) 57
„ ulceration of, due to congenital syphilis (W. A. Sturge) . . 39
LAUTOUR (*Harry A. de*), *per John Wood*, colon of a sheep, showing colotomy performed by a parrot 386
LEDIARD (*H. A.*), kidneys united by a fibrous band . . . 189
„ excision of knee-joint: bone twelve years afterwards . . . 247
„ dislocation of the hip-joint from disease (two cases) . . 247-248
„ lymphoma of mediastinum pressing in the right bronchus and invading the lung 309

LEES, (*David B.*), malformation of the heart, with transposition of the aorta and pulmonary artery 58
LEG, atrophied, from infantile paralysis (A. Doran) . . . 381
LEGG (*J. Wickham*), xanthelasma multiplex, disappearance of the patches . 329
„ enlargement of the temporal and masseter muscles on both sides . 361
LICHEN RUBER, case of (W. Morrant Baker) . . . 334
LIME, oxalate of, see *Calculus*.
LITHATES, see *Calculus*.
LITHIC ACID, see *Calculus*.
LITHOTOMY, supra-pubic, for removal of a calculus (P. Swain) . . 184
LIVER, acute atrophy of (S. West) 116
„ cancer of the, appearances observed in a case of (Geo. Thin) . . 293
„ primary carcinoma of (P. H. Pye-Smith) . . . 125
„ cirrhosis of, in a child (F. Taylor) 119
„ enlarged, acute fatty changes in (C. H. Ralfe) . . . 144
„ primary diffuse malignant growth in, combining the characters of sarcoma and carcinoma (S. Coupland) 130
„ diffuse sarcoma of, probably congenital (R. W. Parker) . . 290
LUNG, gummata in the (Jon. Hutchinson) 384
LUNGS, atelectasis of, with emphysematous cyst, congenital heart disease (T. Barlow) 48
„ excavation of one, two cases, death in one from exhaustion, in the other from rupture of aneurysm of pulmonary artery (S. West) . . . 50
LUPUS LYMPHATICUS a papulo-vesicular eruption (J. Hutchinson) . 342
„ microscopical *report* on ditto (A. Sangster) . . . 346
LYMPHADENOMA of the lymphatic glands, liver, spleen, lungs, and pleuræ (F. Taylor) 282
„ of the mediastinum, involving the pericardium (F. S. Eve) . . 279
LYMPHATIC GLANDS, secondary deposits in, in a case of epithelioma of the larynx (F. Semon) 55
LYMPHOMA of mediastinum pressing on the right bronchus and invading the lung (H. A. Lediard) 309
LYMPHOSARCOMA of the mediastinum involving the pericardium (F. S. Eve) 279

M'CARTHY (*Jeremiah*), necropsy in *S. Mackenzie's* case of malformation of the heart 67
„ tumour of face, plexiform sarcoma 256
„ gummata in the lung and testes 384
MACKENZIE (*Stephen*), two cases of congenital malformation of the heart 63
MALFORMATION of arm (A. Sturge) 208
„ of the heart, congenital, two cases (S. Mackenzie) . . . 63
„ — congenital, in a girl æt. 13 (H. R. Crocker) . . . 92
„ — with transposition of the aorta and pulmonary artery (D. B. Lees) . 58
„ — absence of pulmonary artery (T. B. Peacock and W. C. Reed) . 91
„ — stenosis of pulmonary artery, &c. (T. B. Peacock and T. Barlow) . 91
MALIGNANT GROWTHS, see *Cancer*.
MALPIGHIAN BODIES, changes in, in granular kidney (R. Saundby) . 154
MAMMA, see *Breast*.
MEDIASTINUM, lymphoma of, pressing on the right bronchus and lung (H. A. Lediard) 309
„ lymphosarcoma, "lymphadenoma" of (F. S. Eve) . . . 279
MELANOSIS of finger (R. J. Godlee) 336
„ of the little finger (T. W. Nunn) 299

MENINGOCELE, pedunculated occipital, with the occipital bone removed after death, showing the opening in the bone (Dr. Roddick) . . 383
MEREDITH (*W. A.*), ovarian cyst which had ruptured repeatedly during nine years prior to removal 180
MITRAL VALVE, aneurysm of (N. Moore) 96
„ stenosis of (J. P. Irvine) 79
MOLE, pigmented, with hypertrophy of mons and labium, growth after excision and second operation (J. Hutchinson) 348
„ the cock's-comb (J. Hutchinson) 349
MOLLITIES OSSIUM, myeloid sarcomata of lower jaw and rib (H. T. Butlin) 277
MOLLUSCUM CONTAGIOSUM, case of (Jas. Startin) . . 341
MOLLUSCUM FIBROSUM, case, with one tumour very large and pendulous (J. Hutchinson) 349
MONS VENERIS, hypertrophy of, in a case of pigmented mole (J. Hutchinson) 348
MOORE (*Norman*), aneurysm of aorta opening into right auricle . . 82
„ aneurysm of mitral valve 96
„ ulcerations of stomach and duodenum 106
„ case of cancer, probably primary, of the gall-bladder . . . 138
„ horseshoe kidney 188
„ two cases of disease of the skull-cap 238
„ case of disease of the supra-renal capsules . . . 350
MORBID GROWTHS 256-314
„ see COMMITTEE ON.
MORPHŒA, histology and pathology of, and its relation to scleroderma adultorum (H. R. Crocker) 315
MORRIS (*Henry*), bony outgrowth of the great trochanter in a case of impacted fracture of the neck of the femur, and simulating a dorsal dislocation of the hip 214
„ pulsating tumour of the left parietal bone, right clavicle and of both femora, with hypertrophy of the heart 259
„ — *remarks* on the microscopical structure of the tumour (J. F. Goodhart and Geo. Thin) 265-266
„ — *letter* of M. Cornil on the tumour 267
„ — *report* of a similar case by S. W. Gross . . . 268
„ — *report* of the Morbid Growths Committee (M. Beck, H. T. Butlin, and R. J. Godlee) 270
MUSCLES of the leg, fatty metamorphosis of (F. S. Eve) . . 381
„ temporal and masseter, enlargement of, on both sides (J. W. Legg) . 361
„ voluntary, appearances, probably of parasites, in, in enteric fever (G. Buchanan) 366
MYOCARDITIS, suppurative, with scarlatinal nephritis (J. F. Goodhart) . 70
MYXO-FIBROMA of epididymis and cord (J. Gay) . . . 310
MYXO-SARCOMA of the spermatic cord removed from a child thirteen months old (W. J. Walsham) 299
„ of the head of the tibia (A. R. Anderson) 309

NECROSIS of the cartilages of the larynx in smallpox and enteric fever (Fred. S. Eve) 33
NEPHRITIS, scarlatinal, in a case of suppurative myocarditis (J. F. Goodhart) 70
NERVE LESIONS, non-traumatic, on degeneration and regeneration of the axis-cylinder in (Geo. Hoggan) 12

NERVES, supposed rupture of most of the roots of the brachial plexus of (Jon. Hutchinson) 27
„ cutaneous, gangrene of, in relation to degeneration and regeneration of the axis-cylinder (Geo. Hoggan) 12
„ optic, from a case of optic neuritis with good sight (E. Nettleship) . 252
„ — atrophy of, in an eye lost by erysipelas spreading to the orbit (E. Nettleship) 254

NERVOUS SYSTEM, DISEASES, &c., of 1–29

NETTLESHIP (*E.*), optic nerve from a case of optic neuritis with good sight 252
„ spontaneous intra-ocular hæmorrhage in an infant . . . 253
„ atrophy of optic nerve and retina, and other changes in an eye lost by erysipelas spreading to the orbit 254
„ see *Hutchinson* (*J.*), cholesterin in eyeball

NEURITIS, optic, with good sight; optic nerve from the case (E. Nettleship) 252

NUNN (*T. W.*), recurrent tumour of breast removed seven years after first operation 276
„ *report* of the Morbid Growths Committee on ditto (M. Beck and R. J. Godlee) 276
„ epithelioma of the penis 298
„ melanosis of the little finger 299

OCCLUSION, complete, of right pulmonary artery (W. Ewart) . . 99
„ of the duodenum above the common bile-duct, congenital (G. Eastes) . 114
„ of hepatic ducts by medullary carcinoma of duodenum (S. Coupland) . 145

ŒSOPHAGUS and stomach from a case of acute carbolic acid poisoning (Rt. Smith) 143

OMENTUM, great, hernia of ileum through rent in (S. Coupland) . 146

ORD (*W. M.*), description of a large gall-stone passed per anum, with remarks on the structure and formation of biliary calculi . . . 139
„ calculus from the kidney 185
„ cystine calculus, 1050 grains 384
„ enterolith, an oriental bezoar 385

ORGANS OF SPECIAL SENSE, DISEASES, &c., of . . 252-255

ORLEBAR (*H. G.*), aneurysm and rupture of aortic valve . . 97
„ aneurysm of aortic arch rupturing into trachea . . . 98

OS CALCIS, ostitis of right (W. Rivington) 246

OSSEOUS SYSTEM, DISEASES, &c., of. . . . 193-251

OSTITIS of right os calcis (W. Rivington) 246
„ with ulceration of the skull, gummatous infiltration of dura mater, &c., from a case of syphilis (S. Coupland) 243
„ of the ulna in connection with inherited syphilis (Jon. Hutchinson) . 248
„ chronic, in connection with inherited syphilis (Jon. Hutchinson) . 250

OVARIAN CYST, which had ruptured repeatedly during nine years prior to removal (W. A. Meredith) 180

OVARIOTOMY, spinal cord from a case of tetanus following (V. Harris and A. Doran) 7

PAPILLOMA of the Fallopian tube, with ascites and pleuritic effusion (A. Doran) 174

PARKER (*Robert W.*), ossifying chondro-sarcoma of both femora with secondary deposits of a similar new growth in the lungs and in the bronchial and lymphatic glands 223
„ bone lesions in congenital syphilis 226
„ diffuse sarcoma of liver, probably congenital . , . 290
„ congenital talipes varus and talipes calcaneus . . . 370

PARALYSIS, talipes equino-varus from long-standing (F. S. Eve) . 381
„ infantile, dissection of a leg atrophied from and amputated from a patient æt. 20 (A. Doran) 381

PARROT, colotomy performed by, on a sheep (H. A. de Lautour) . 386

PATELLA, chronic enlargement of a bursa patellæ (J. Hutchinson) . 383

PEACOCK (*T. B.*) and *T. BARLOW*, malformation of the heart, stenosis of pulmonary artery, aorta communicating with both ventricles . . 91
„ and *W. C. REED*, malformation of the heart, absence of the pulmonary artery 91
„ see *Fisher*.

PENIS, epithelioma of (Thomas W. Nunn) 298

PERICARDIUM, leakage in, from an extra-pericardial aneurysm of ascending aorta (W. Ewart) 82

PERICHONDRITIS, see *Chondritis*.

PERIOSTITIS and osteo-myelitis of os calcis (W. Rivington) . . 246

PERITONEUM, patent vaginal process of (F. S. Eve) . . . 147
„ hernia into vaginal process of (F. S. Eve) 147

PHARYNX, epithelioma of, involving the larynx, trachea, and œsophagus (T. Gilbart Smith) . . . . . , . 102

PLEURA, left, hernia of abdominal viscera into (W. Ewart) . . 146

PLEURITIC EFFUSION, associated with a papilloma of the Fallopian tube (A. Doran) 174

POISONING, see *Carbolic Acid* Poisoning.

POLYPOID BODY found in left ventricle, following incompetency of the aortic valves, &c. (E. H. Greenhow) 73

PORT (*Heinrich*), dermoid tumour from the rectum . . . 307

PYE-SMITH (*P. H.*), membranous inflammation of the larynx, trachea, and bronchial tubes in an adult 30
„ aneurysm of abdominal aorta and external iliac artery opening into vena cava 85
„ primary carcinoma of the liver 125

RALFE (*C. H.*), acute fatty changes in an enlarged liver . . 144
„ branched renal calculus 189

RASH, peculiar circular wandering, on the tongue (A. E. Barker) . . 353

RECTUM, persistent communication of, with genito-urinary track in newborn male child (S. G. Shattock) 191
„ imperforate (W. H. Cripps) 112
„ dermoid tumour from the (H. Port) 307

REED (*W. C.*), see *Peacock*, Malformation of Heart.

RESPIRATION, ORGANS of, diseases, &c., of 30-57

RETINA, atrophy of, in an eye lost by erysipelas spreading to the orbit (E. Nettleship) 254

RIB, myeloid sarcomata of, mollities ossium (H. T. Butlin) . . 277

RING, fibro-cretaceous, surrounding the heart (W. Ewart) . . 94

RIVINGTON (*Walter*), ostitis of right os calcis, combined periostitis and osteomyelitis 246
RODDICK (*Dr.*), *per Jonathan Hutchinson*, infant with a pedunculated occipital meningocele: the occipital bone, after death, showing the opening . 383
RUPTURE of aortic valve (H. G. Orlebar) 97
„ of right ventricle of the heart (T. Fisher) 72
„ supposed, of most of the roots of the brachial plexus (Jon. Hutchinson) . 27

SANGSTER (*A.*), microscopical *report* on Jon. Hutchinson's case of vesicular wart-like growth on the chin 346
SARCOMA of the liver (S. Coupland) 130
„ — diffuse, probably congenital (R. W. Parker) . . . 290
„ MULTIPLE, of cranial bones (J. Abercrombie) . . . 216
„ — central medullary, round-celled, of the osseous centre system (S. W. Gross) 268
„ MYELOID, of lower jaw and rib, mollities ossium (H. T. Butlin) . 277
„ PLEXIFORM, of the face (Jer. McCarthy) 256
„ SPINDLE-CELLED, sixth removal (John Gay) . . . 272
„ see *Chondro-sarcoma, Myxo-sarcoma.*
SARCOMATOUS GROWTH, invading both kidneys from without (J. Abercrombie) 168
SAUNDBY (*R.*), the histology of granular kidney . . . 148
SCARLATINA, see *Nephritis* (scarlatinal).
SCIRRHUS of female breast, cases of (J. W. Hulke) . . 311-312
SCLEREMA, case of (W. E. Steavenson) 326
SCLERODERMA ADULTORUM, case illustrating its circumscribed and diffuse forms (D. Duckworth) 322
„ — relation of morphœa to (H. R. Crocker) . . . 315
SEMON (*Felix*), two cases of congenital syphilis of the larynx . . 41
„ epithelioma of larynx, secondary deposits in lymphatic glands, chondritis of thyroid cartilage 55
SENSE, SPECIAL, ORGANS of, DISEASES . . . 252-255
SEPTUM, see *Heart.*
SHATTOCK (*Sam. G.*) mixed calculus of cystine and oxalate of lime . 182
„ persistent communication between the rectum and genito-urinary track in a new-born male child 191
„ recent division of the tendo Achillis 382
SHEEP, colon of, showing colotomy performed by a parrot (H. A. de Lautour) 386
SIGMOID FLEXURE, cancer of, gangrene of bowel, &c. (J. F. Goodhart) . 113
SKIN, papulo-vesicular eruption on, or lupus lymphaticus (J. Hutchinson) . 342
SKULL-CAP, two cases of disease of (N. Moore) . . . 238
„ see *Cranium.*
SMALLPOX and ENTERIC FEVER, necrosis of the cartilage of the larynx in (Fred. S. Eve) 33
SMITH (*Robert*), œsophagus and stomach from a case of acute carbolic acid poisoning 143
SMITH (*T. Gilbart*), epithelioma of the pharynx involving the larynx, trachea, and œsophagus 102
SPECIMENS, MISCELLANEOUS 353-384
SPECIMENS FROM THE LOWER ANIMALS . . 385-388

SPERMATIC CORD, myxo-fibroma of (J. Gay) . . . 31
„ myxo-sarcoma of, removed from a child thirteen months old (W. J. Walsham) 299
„ tumour of, from a child four years of age (W. J. Walsham) . . 303
SPINAL CORD, from a case of tetanus following ovariotomy (V. Harris and A. Doran) 7
SPINE, caries of, producing aortic deformity (A. E. Barker) . . 246
SQUIRE (*W.*), micro-photographs of the blood in yellow fever . . 380
STARTIN (*James*), case of molluscum contagiosum . . . 341
STEAVENSON (*W. E.*), *per Thomas Barlow*, case of sclerema . . 326
STENOSIS, aortic, mitral, and tricuspid, firm clot in left auricle, &c. (J. P. Irvine) 79
„ of the pulmonary artery (T. B. Peacock and T. Barlow) . . 91
STOMACH, INTESTINES, &c., DISEASES of . . . 101-147
„ from a case of carbolic acid poisoning (Rt. Smith) . . . 143
„ see *Ulcer of.*
STURGE (*W. Allen*), ulceration of the larynx due to congenital syphilis . 39
„ malformation of arm 208
SUPRA-RENAL CAPSULES, DISEASES, &c., of . . 350-352
„ case of disease of (N. Moore) 350
„ fibrous and calcareous changes in, perhaps syphilitic (Wm. Ewart) . 352
SWAIN (*Paul*), calculus removed by supra-pubic lithotomy . . 184
SYPHILIS, ostitis of skull, gummatous infiltration of dura mater, &c., from a case of (S. Coupland) 243
„ congenital, of the larynx; two cases (F. Semon) . . . 41
„ — laryngitis in (T. Barlow) 46
„ — ulceration of larynx due to (W. A. Sturge) . . . 39
„ — disease of growing ends of shafts of long bones in (T. Barlow) . 229
„ — bone lesions in (R. W. Parker) 226
„ hereditary or inherited, gumma of tongue in (T. Barlow) . . 101
„ — gumma of testis from a boy, the subject of (J. Hutchinson) . . 192
„ — chronic osteitis in connection with (Jon. Hutchinson) . . 250
„ — osteitis of ulna in connection with (Jon. Hutchinson) . . 248
„ late hereditary, two cases (S. Coupland) 376
„ see *Tooth.*
SYPHILITIC (?) disease of the bones in a fœtus (F. S. Eve) . . 233
„ — of parietal bone, congenital, associated with cranio-tabes (T. Barlow) . 236
„ — of testicle (F. S. Eve) 190
SYPHILITIC GUMMATA, sequel to a case of, in vol. xx of the 'Trans.,' p. 309 (W. Adams) 374
„ — in the lung and testis (J. Hutchinson) 384

TABES, see *Cranio-tabes.*
TABES DORSALIS, osseous and articular lesions in (Tho. Buzzard) . 193
TALIPES CALCANEUS (R. W. Parker) 371
TALIPES EQUINO-VARUS from long-standing paralysis (F. S. Eve) . 381
TALIPES VARUS, congenital (R. W. Parker) . . . 370
TAYLOR (*Frederick*), cirrhosis of the liver in a child . . . 119
„ lymphadenoma of the lymphatic glands, liver, spleen, lungs, and pleuræ . 282
„ *report* on John Gay's specimen of recurrent mammary tumour . 389
TENDO ACHILLIS, recent division of (S. G. Shattock) . . . 382
„ reunited, with formation of one and a half inch of new tendon, after subcutaneous division four years before death (W. Adams) . . . 372

TESTIS, fibroid, from a case of syphilis (S. Coupland) . . . 243
„ gumma of, from a boy, the subject of inherited syphilis (J. Hutchinson) . 192
„ gummata in (Jon. Hutchinson) 384
„ undescended, hernia of, into vaginal process (F. S. Eve) . . 147
„ syphilitic disease of (ditto) 190
TETANUS, spinal cord from a case of, following ovariotomy (V. Harris and A. Doran) 7
THIN (*George*), remarks on the microscopical structure of H. Morris's pulsating tumour of cranium 266
„ on some of the appearances observed in a case of cancer of the liver . 293
„ on the histology of a cancerous tumour of the mamma . . 294
„ histology of elephantiasis arabum and its relations to normal connective tissue 337
„ on the fungus of tinea imbricata 339
THORNTON (*J. Knowsley*), see *Day* and Thornton, Cystic kidney
THUMB, recent dislocation of the first phalanx of, forwards (F. S. Eve) . 216
THYROID CARTILAGE, chondritis of, in a case of epithelioma of the larynx (F. Semon) 55
TIBIA, dwarfing of, following detachment of its lower epiphysis (J. Hutchinson) 249
„ myxo-sarcoma of head of (A. R. Anderson) . . . 309
TINEA IMBRICATA, on the fungus of (G. Thin) . . . 339
TISSUE, see *Connective tissue.*
TONGUE, gumma of, in hereditary syphilis (T. Barlow) . . 101
„ on a peculiar circular, wandering rash on the (A. E. Barker) . . 353
TOOTH, milk, its crown exfoliated in a syphilitic infant (J. Hutchinson) . 382
TRACHEA, aneurysm of aortic arch rupturing into (H. G. Orlebar) . 98
„ membranous inflammation of, in an adult (P. H. Pye-Smith) . . 30
„ old syphilitic scars in leading to chronic disease in the lungs (W. Ewart) 57
TRANSPOSITION of the aorta and pulmonary artery, in a case of malformation of the heart (D. B. Lees) 58
TRICUSPID VALVE, stenosis of (J. P. Irvine) . . . 79
TROCHANTER, bony outgrowth of the great, simulating dorsal dislocation of the hip (H. Morris) 214
TUBERCLE, miliary, in mucous membrane of the bladder (W. Ewart) . 190
TUMOUR found loose in abdominal cavity (F. S. Eve) . . 311
„ of face, plexiform sarcoma (Jer. McCarthy) . . . 256
„ of spermatic cord from a child four years of age (W. J. Walsham) . 303
„ see *Sarcoma.*
„ CARTILAGINOUS, of arm (W. H. Cripps) 287
„ DERMOID, from the rectum (H. Port) 307
„ FATTY, of abdomen, showing fibrous and osseous changes (J. Dreschfeld) . 287
„ — pedunculated, from the anterior superior spine of the ilium (W. J. Walsham) 310
„ PULSATING, of left parietal bone, right clavicle and both femora, with hypertrophy of the heart (H. Morris) 259
„ RECURRENT, of breast, removed seven years after first operation (T. W. Nunn) 276
„ — mammary: spindle-celled sarcoma; sixth removal (John Gay) . 272
„ see *Cancerous tumours.*
TYPHOID FEVER, hæmorrhage in, followed by fatty degeneration of the heart (J. F. Goodhart) 71
„ two cases of necrosis of the arytænoid cartilages in (Fred. S. Eve) . 35
„ see *Enteric fever.*

ULCERATION of the larynx, due to congenital syphilis (W. A. Sturge) . 39
„ of the stomach, statistics of, at St. Bartholomew's Hospital, 1867-79 (N. Moore) 109-110
„ — and duodenum (N. Moore) 106
„ simple, of the stomach (N. Moore) . . . 106-107
„ — of duodenum (N. Moore) 108
„ of ventricular septum and erosion of cusp of the valve (E. H. Greenhow) . 73
ULNA, united fracture of right, from a case of locomotor ataxy (W. B. Hadden) 245
„ osteitis of, in connection with inherited syphilis (Jon. Hutchinson) . 248
URETERS, cystic degeneration of, during intra-uterine life (W. Ewart) . 187
„ two complete, on either side of the body (W. Ewart). . . 188
URINARY ORGANS, DISEASES, &c., of . . . 148-192
UTERUS SEPTUS cum vagina duplici (W. J. Walsham) . . 191
VAGINA DUPLEX et uterus septus (W. J. Walsham) . . . 191
VALVES, aortic, mitral and tricuspid, stenosis of (J. P. Irvine) . . 79
„ see *Aortic, Mitral, Tricuspid.*
VARICELLA GANGRÆNOSA, case of (J. Abercombie) . . 333
VASCULAR SYSTEM, DISEASES, &c., of . . . 58-100
VEINS, cerebral, congenital malformation of, in a case of ramifying cyst in the brain (Wm. Ewart) 1
VENA CAVA, obliteration of right and persistence of left superior (S. Mackenzie) 63
„ persistent left superior (W. J. Walsham) 99
„ aneurysm of aorta opening into (P. H. Pye-Smith) . . . 85
VENTRICLES, see *Heart.*
VESSELS, see *Arteries, Veins.*
VISCERA, abdominal, hernia of some, into left pleura (W. Ewart) . 146
VOLVULUS of the ileum (W. H. Cripps) 111
„ of small intestine, due to a complete Meckel's diverticulum (S. Coupland) 144
WALSHAM (*W. J.*), persistent left superior vena cava . . . 99
„ uterus septus cum vagina duplici 191
„ myxo-sarcoma of the spermatic cord, removed from a child thirteen months old 299
„ tumour of the spermatic cord, from a child four years of age . . 303
„ horny growth from the lower eyelid of an old woman . . 306
„ pedunculated fatty tumour from the anterior superior spine of the ilium 310
„ see *Anderson.*
WEST (*Samuel*), two cases of complete excavation of one lung, death in one from exhaustion, in the other from rupture of an aneuryrm of the pulmonary artery 50
„ blood-casts of the bronchi 53
„ a case of acute atrophy of the liver 116
WOOD (*John*), see *Lautour.*
XANTHELASMA multiplex, disappearance of the patches (J. W. Legg) . 329
YELLOW FEVER, micro-photographs of the blood in (W. Squire) . 380

ERRATUM IN VOLUME XXX.

Page 387.—*For* James Gairdner, M.D., *read* William Tennant Gairdner, M.D.
List of Specimens, page xliii.—The same correction.
Index, page 598.—*For* Gairdner (*James*), *read* Gairdner (*William Tennant*).

41 B107

U. HOLZER
BINDER
ANTIGO, WIS.